

Duodenal Diverticular Bleeding

Yan-Yu Chen^{1,2,3}, Wei Liu^{1,2,3*}

¹The First College of Clinical Medical Science, China Three Gorges University, Yichang, China.

²Institute of Digestive Disease, China Three Gorges University, Yichang, China.

³Department of Gastroenterology, Yichang Central People's Hospital, Yichang, China.

*Corresponding Author: Wei Liu, Institute of Digestive Disease, China Three Gorges University, 8 Daxue Road, Yichang 443000, China.

Received date: November 24, 2024; Accepted date: January 09, 2025; Published date: February 10, 2025

Citation: Yan Y. Chen, Wei Liu, (2025), Duodenal Diverticular Bleeding, *Clinical Research and Clinical Trials*, 12(2); DOI:10.31579/2693-4779/248

Copyright: © 2025, Wei Liu. This is an open access article distributed under the Creative Commons Attribution License, which permits unrestricted use, distribution, and reproduction in any medium, provided the original work is properly cited.

Abstract:

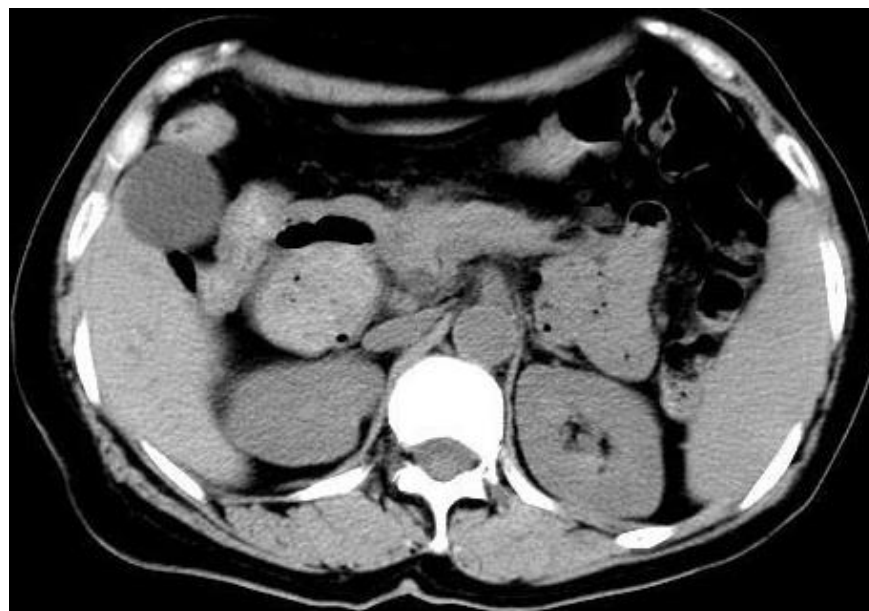
A 69-year-old man with no previous medical history presented to our hospital with a 2-week history of melena, severe, and anemia and dizziness. Physical examination revealed pale skin, hypotension, and tachycardia. Abnormal laboratory values showed hemoglobin 65 g/L.

Keywords: hypotension; bleeding; gastrointestinal

Introduction

A 69-year-old man with no previous medical history presented to our hospital with a 2-week history of melena, severe, and anemia and dizziness. Physical examination revealed pale skin, hypotension, and tachycardia.

Abnormal laboratory values showed hemoglobin 65 g/L. Abdominal computed tomography revealed a large intraluminal diverticulum located in the descending duodenum after initial fluid resuscitation (Figure 1A).



Upper gastrointestinal bleeding was suspected.

Esophagogastroduodenoscopy showed a juxtapapillary thin-walled diverticulum in the descending segment of duodenum with a ulcerative lesion oozing in its edge (Figure 1B).

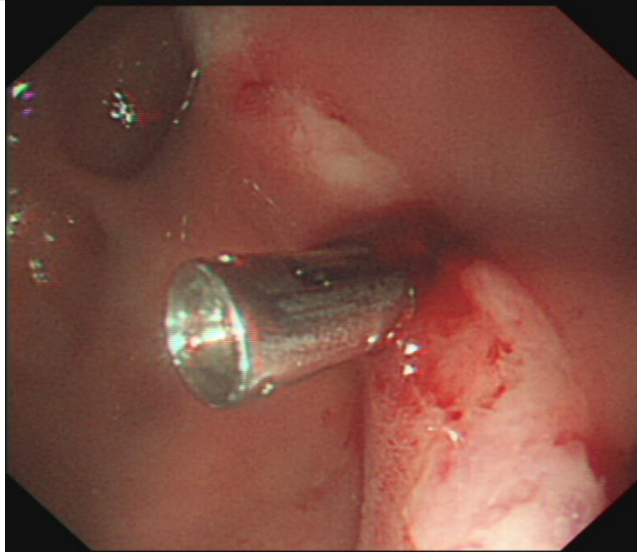


Figure 1: Abdominal computed tomography revealed a large intraluminal diverticulum located in the descending duodenum after initial fluid resuscitation. B. Esophagogastroduodenoscopy showed a juxtapapillary thin-walled diverticulum in the descending segment of duodenum with a ulcerative lesion oozing in its edge.

An over-the-scope clip was successfully deployed after attempted hemostasis with adrenalin failed. The patient experienced an uneventful clinical course. Diverticular bleeding is a rare cause of upper gastrointestinal bleeding.[1] Most duodenal diverticula are located on the second part of the duodenum, originated from a congenital malformation of the descending duodenum, which may lead to epigastric pain, vomiting, or bleeding depending on size and the relationship to the papilla of Vater.[2] Symptomatic bleeding from a duodenal diverticulum is uncommon. Sclerotherapy, mechanical, and thermal devices are useful for successful management of diverticular bleeding by endoscopy.[3]

Conflicts of Interest: The authors have no conflicts of interest to declare.

Ethical Statement: The authors are accountable for all aspects of the work in ensuring that questions related to the accuracy or integrity of any part of the work are appropriately investigated and resolved. Written informed consent was obtained from the patient for publication of this “GI Image”. Board institutional approval was not required.

Author’s contributions

Collection of data and writing: Wei Liu.

Manuscript preparation: Yan-Yu Chen.

Final approval of the manuscript: Wei Liu.

References

1. Rintaro Hashimoto, Akimichi Chonan. (2017). Duodenal Diverticular Bleeding Missed Repeatedly at Endoscopy. Clin Gastroenterol Hepatol.;15(4):79.
2. Vito D Corleto, Emilio Di Giulio, Gianfranco Delle Fave. (2007). Gastrointestinal bleeding caused by giant duodenal diverticula. Clin Gastroenterol Hepatol.;5(8):29.
3. Samuel Raimundo Fernandes, João Lopes, Ana Isabel Valente. (2018). Duodenal Diverticular Bleeding Managed Using an Over-the-Scope Clip. Clin Gastroenterol Hepatol.;16(3):36.



This work is licensed under Creative Commons Attribution 4.0 License

To Submit Your Article Click Here:

[Submit Manuscript](#)

DOI:10.31579/2693-4779/249

Ready to submit your research? Choose Auctores and benefit from:

- fast, convenient online submission
- rigorous peer review by experienced research in your field
- rapid publication on acceptance
- authors retain copyrights
- unique DOI for all articles
- immediate, unrestricted online access

At Auctores, research is always in progress.

Learn more <https://auctoresonline.org/journals/clinical-research-and-clinical-trials>