

Irreversible Electroporation of Prostate Cancer an Update

Anthony Kodzo-Grey Venyo*

North Manchester General Hospital, Department of Urology, Delaunays Road, Manchester, M8 5RB, United Kingdom.

***Corresponding Author:** Anthony Kodzo-Grey Venyo, North Manchester General Hospital, Department of Urology, Delaunays Road, Manchester, M8 5RB, United Kingdom.

Received Date: 11 November, 2024 | **Accepted Date:** 20 November, 2024 | **Published Date:** 20 December, 2024

Citation: Anthony Kodzo-Grey Venyo., (2024), Irreversible Electroporation of Prostate Cancer an Update., *Journal of Clinical Surgery and Research.*, 5(9); **DOI:**10.31579/2768-2757/152

Copyright: © 2024, Anthony Kodzo-Grey Venyo., This is an open access article distributed under the Creative Commons Attribution License, which permits unrestricted use, distribution, and reproduction in any medium, provided the original work is properly cited.

Abstract

It has been known that the undertaking of radical treatment for localized prostate cancer has often been ensued by a major impact upon the quality of life of individuals who had undergone radical treatment for their localized prostate cancer, some of which include urinary incontinence and other types of voiding problems as well as erectile dysfunction. This has led to the development of focal therapy for prostate cancer, which has the objective of attaining equivalent oncology control of the problem, whilst improving upon episodes of voiding and incontinence problems as well as maintaining coital and erectile function preservation of each individual patient. Irreversible electroporation (IRE) is a new treatment option which utilises using pulsed high-voltage low-energy direct electric current for the ablation of tumour. As a non-thermal energy platform, IRE does have the advantage of sparing the peri-prostatic encompassing functional structures, including blood vessels and connective tissue. Histopathology examination outcomes pursuant to the undertaking of IRE to prostate cancer had demonstrated sharp demarcation between the ablated and non-ablated tissue, whereas thermal ablation techniques had demonstrated a transitional zone of partially damaged tissue due to insufficient temperatures for definitive ablation. An international multi-centre study pursuant to the treatment 411 patients who had undergone treatment for prostate cancer from July 2015 up to April 2020 had concluded that:

- For men who are afflicted by localized prostate cancer, IRE could achieve good urinary and sexual function outcomes and a reasonable oncology result.
- The real-world data are consistent with earlier studies, including recently published randomized controlled studies.
- The long-term oncology results need further investigation and follow-up.
- The rate of AEs was 1.8% at 3 months after IRE and major AEs were rare.
- The IPSS initially had worsened but had returned to baseline level at 6 months.
- The IIEF-5 had worsened at 3 months and then had been maintained stable subsequently.
- IRE had been able to achieve a reasonable oncology outcome.
- The clinically significant prostate cancer rate in the repeat biopsy during 12–18 months was in 24.1%.
- The long-term oncology results need further investigation and follow-up.
- The real-world data are consistent with earlier studies including recently published randomized controlled studies.

Keywords

adenocarcinoma of prostate gland; prostate biopsy; ultrasound scan; computed tomography scan; magnetic resonance imaging scan; good oncology outcomes; further studies

Introduction

It has been iterated that prostate cancer represents the second most common solid tumour that afflicts men with an incidence which was 1,414,259 new cases globally in the year 2020.[1] [2] It has been pointed out that the standard of care for localized prostate cancer, depending upon the International Society of Urological Pathology (ISUP) grade and the stage of the disease, had traditionally been active surveillance, radical prostatectomy (RP), and radiotherapy (RT). RP and RT had been documented to be the long-standing curative whole-gland approaches which had been associated with the best possible oncology outcomes for patients who are afflicted by localized prostate cancer. Nevertheless, it has also been pointed out that these curative treatment options have tended to be associated with adverse quality-of-life outcomes such as urinary incontinence and sexual dysfunction. In view of this, newer advances in the field of prostate cancer management had been directed towards the provision of focal therapy with an intent of balancing the patient's quality of life while treating the lesion effectively.

It has been pointed out that focal ablation therapy could cover a wide range of ablation treatment options depending upon the site of location of the tumour within the prostate gland. [1] It has been iterated that the most common ablative treatment options which tend to be used are focal, quadrant, hemi-ablation, and hockey-stick ablation. [1] [3] Focal therapies such as irreversible electroporation (IRE), high-intensity focused ultrasound (HIFU), cryoablation, radiofrequency ablation (RFA), photodynamic therapy (PDT), brachytherapy, and focal laser ablation (FLA) had been developed with the objective to preserve the non-cancerous prostatic tissue as well as to reduce the harm to the neurovascular bundles, urethra, urethral sphincter, and the rectum which could happen.[1] [4] It has been pointed out that cryotherapy, FLA, RFA, and PDT do administer localized thermal ablation but could also cause nonselective injury to the tissues that encompass the targeted area, as they do lack precision when they are compared to the IRE. [1] It has furthermore, been iterated that focal treatment options which rely upon thermal ablation are also affected by the heat sink effect, when the area of ablation is too close to the blood vessels.[1] [5] It has in addition been pointed out that IRE is a relatively new focal therapy when compared to HIFU or cryoablation, which had been explored more extensively. When a cell is subjected to an electric field, a process called electroporation does develop, wherein nanopores

are formed upon the cell membrane. IRE is documented to use repetitive electric pulses in order to create nanopores upon the cell membrane and which induces cell death due to membrane instability and disruption of the cellular homeostasis. [1] [6] Considering that utilization of irreversible electroporation in the treatment of localised prostate cancer has only been undertaken in a few well-resourced centres in the world, it would be envisaged that the majority of practising clinicians in every part of the world including: general practitioners, urologists, oncologists, pathologists, as well as radiologists would not be familiar with the utilization of irreversible electroporation in the treatment of localised prostate cancer. The ensuing article on irreversible electroporation of carcinoma of the prostate gland is divided into two parts:(A) Overview, and (B) miscellaneous narrations and discussions from some case reports, case series, and studies related to irreversible electroporation of prostate cancer.

Aim

To provide an update on irreversible electroporation of prostate cancer

Methods

Internet data bases were searched including: Google, google scholar; yahoo; and PUBMED. The search words that were used included: Irreversible electroporation of prostate cancer; prostatic cancer irreversible electroporation; Irreversible electroporation of the prostate gland. Fifty-six (56) references were identified which were used to write the article which has been divided into two parts: (A) Overview, and (B) miscellaneous narrations and discussions from some case reports, case series, and studies related to irreversible electroporation of prostate cancer.

Results

[A] OVERVIEW

Definition / general statements [7]

- It has been iterated that even though there are various types of cancer that afflicts the prostate gland, adenocarcinoma of the prostate gland is the most common malignancy of the prostate gland
- It has been pointed out that adenocarcinoma of the prostate gland does originates from prostatic secretory epithelium
- Essential features
- The essential manifesting features of adenocarcinoma of the prostate gland had been summated as follows: [7]
- It has been pointed out that the clinical and radiology-image features of the prostate gland, are neither sensitive nor specific to be used to establish the diagnosis of adenocarcinoma of the prostate gland
- It has been explained that diagnosis of adenocarcinoma of the prostate gland is often established based upon pathology examination of specimens of the prostate gland which had been obtained by non-targeted needle biopsies during the investigation of raised serum prostate specific antigen (PSA) of the patient
- It has been pointed out that during pathology examination of specimens of the prostate gland, absence of basal cell layer in the specimen of the prostate gland is a pathognomonic histological feature
- It has been iterated that the pathognomonic diagnostic features of adenocarcinoma of the prostate gland include the ensuing: circumferential perineural invasion, glomerulations and collagenous micronodules (mucinous fibroplasia)
- It has been pointed out that other histopathology examination features of adenocarcinoma of the prostate gland include the ensuing: infiltrative architecture, nucleolar prominence, amphophilic cytoplasm and some intraluminal contents (crystalloids, blue mucin, pink amorphous material)
- Terminology
- It has been iterated that: Other terminologies, had tended to be utilized for adenocarcinoma of the prostate generally as follows: [7]
- Prostate cancer
- Prostate adenocarcinoma
- It has been iterated that: Various sub-types of adenocarcinomas of the prostate gland exist including:
 - Acinar adenocarcinoma
 - Ductal adenocarcinoma
 - Atrophic adenocarcinoma
 - Pseudo-hyperplastic adenocarcinoma
 - Microcystic adenocarcinoma
 - Foamy gland adenocarcinoma
 - Mucinous adenocarcinoma
 - Signet ring variant of adenocarcinoma
 - Pleomorphic giant cell adenocarcinoma
 - Sarcomatoid adenocarcinoma

Epidemiology

The epidemiology of adenocarcinoma of the prostate gland has been summated as follows: [7]

- It has been documented that adenocarcinoma of the prostate gland, is the second most common cancer and second leading cause of cancer related death in American men. [8]
- It has been iterated that in 2024, about 2.0 million people would be diagnosed with cancer within the United States of America (U.S.A.) An estimated 310,720 women and 2,790 men would be diagnosed with breast cancer, which makes it the most common cancer diagnosis. Prostate cancer is the leading cancer diagnosis among men and the second most common diagnosis overall with 299,010 expected cases. Lung and bronchus cancer is the third most common cancer diagnosis with an estimated 234,580 new cases. [9]

- It has been iterated that 92% of U.S. cases of adenocarcinoma of the prostate gland, are diagnosed in men aged, who are aged 55+ years; and in 19.5% in men aged 75+ years. [10]
- It has been iterated that adenocarcinoma of the prostate gland is found at autopsy in 40% of men who are aged 60+ years [11]
- It has been documented that incidental prostate cancer is reported in about 25% of cystoprostatectomies that had been undertaken for the treatment of urinary bladder cancer [12]
- It has been iterated that globally, the highest age standardized rates of adenocarcinoma of the prostate gland are in Oceania, North America, Europe [13]
- It has been iterated that lower rates of adenocarcinoma can be found in the developing countries and that this lower rates of adenocarcinoma of the prostate gland might be due to different screening programs and diagnostic pathways
- It has been pointed out that there is a higher incidence of adenoma of the prostate gland in men of African heritage [13]

Sites

- The sites of the prostate gland that are afflicted by adenocarcinoma had been summated as follows: [7]
- The majority of adenocarcinoma of prostate gland tumours are stated to be multifocal tumours [14]
- It has been stated that 75% to 80% of adenocarcinomas of the prostate gland are found within the posterior / posterolateral peripheral zone of the prostate gland
- It has been iterated that between about 13% to 20% of adenocarcinomas of the prostate gland are found in the transition (periurethral) zone [15] [16]
- It has been pointed out that most clinically significant adenocarcinomas of the prostate gland arise within the peripheral zone of the prostate gland which is sampled by needle biopsies
- It has been iterated that transition zone prostate cancer is associated with favourable pathology examination features and better recurrence free survival [17]
- It has been pointed out that adenocarcinoma of the prostate gland less frequently afflicts the anterior prostate most likely due to inadequate sampling using standard biopsy approach [18]

Pathophysiology

The pathophysiology of adenocarcinoma of the prostate gland has been summated as follows: [7]

- It has been iterated that germline variants of primary adenocarcinoma of the prostate gland could increase the risk of developing prostate adenocarcinoma []
- Somatic mutations in genes such as ERG, ETV1/4, FLI1, SPOP, FOXA1, IDH1, PTEN, TP53, MYC, CDH1 had been documented to be associated with adenocarcinoma of the prostate gland [19] [20]
- It has been iterated that the most common somatic genomic rearrangement in cases of adenocarcinoma of the prostate gland is fusion of the androgen regulated gene TMRSS2 with a member of the ETS transcription family [20]

Aetiology

The aetiology of adenocarcinoma of the prostate gland has been summated as follows: [7]

- Obesity increases the risk for the development of adenocarcinoma of the prostate gland [21]
- Non-modifiable risk factors that had been stated to be associated with the development of adenocarcinoma of the prostate gland had been iterated to include the ensuing: age, race and family history [22]
 - Genetic susceptibility linked to African heritage [22]
 - Increased risk with first degree relative with prostate cancer [22]
 - BRCA2 mutations increase the risk for the development of adenocarcinoma of the prostate gland by 5-fold; BRCA2 associated cancers occur at a lower age and have worse survival outcomes [20] [22] [23]
 - Additional germline variants associated with increased cancer risk is stated to occur in HOXB13 [20]
 - Increased risk for the development of adenocarcinoma of the prostate gland was stated to be in Lynch syndrome [24]
- Numerous single nucleotide polymorphisms (SNPs) that have a low to moderate effect on risk / progression have been identified [7] [25]
- It has been iterated that high levels of IGF1 might confer increased risk for the development of adenocarcinoma of the prostate gland [7] [26]

Clinical features

- The clinical manifesting features of primary adenocarcinoma of the prostate gland had been summated as follows: [7]
- It has been iterated that generally adenocarcinoma at the time of initial diagnosis has tended to be asymptomatic unless locally advanced or metastatic
- It has been stated that adenocarcinoma of the prostate gland is often discovered following investigation of nonspecific lower urinary tract symptoms
- It has been iterated that in some cases of adenocarcinoma of the prostate gland, during digital rectal examination (DRE), the prostate gland may feel normal or may be enlarged / asymmetrical / hard / as well as have a palpable nodule present

Diagnosis

- The process of the diagnosis of adenocarcinoma of the prostate gland has been summated as follows: [7]

- It has been stated that generally prostate cancer is diagnosed by the systematic transrectal ultrasound guided prostate biopsies, and the pathologist then examines the specimens of the prostate biopsies to visualise the prostate cancer diagnostic features of the prostate biopsy specimens [7]
- It has been iterated that trans-perineal needle biopsies of the prostate gland with targeted biopsies is increasingly undertaken which has tended to be associated with lower risk of infection [7]
- It has been pointed out that the undertaking of pre-biopsy magnetic resonance imaging (MRI) scan which is ensued by the undertaking of systematic prostate biopsies which is supplemented with targeted biopsies from any radiological abnormality leads to improve the identification of clinically significant prostate cancer than systematic prostate biopsy alone [7] [27]
- It has been iterated that incidental prostate cancer is sometimes diagnosed in transurethral resection of prostate gland (TURP) specimens [7]
- It has been iterated that immunohistochemistry studies of specimens of the prostate gland with basal cell markers (HMWCK, p63) and AMACR is utilised to establish the diagnosis of prostate cancer in equivocal cases [7]

Laboratory

The ensuing summations had been made regarding laboratory tests in the assessment, diagnosis, and follow-ups of individuals who are afflicted by adenocarcinoma of the prostate gland: [7]

- Raised serum PSA
- It has been pointed out that different serum PSA level cutoffs had been utilised to prompt the undertaking of prostate needle biopsy [7]
- It has been iterated that age-specific serum PSA cutoffs, PSA velocity (rate of change in PSA over time) and PSA density (PSA per unit prostate volume - ng/mL/cc) might increase sensitivity and specificity of PSA testing [28]
- It has been pointed out that U.S.A. Preventative Services Task Force (USPSTF) had recommended against serum PSA based screening for prostate cancer in men who are aged 70 years and older [7]
 - For men, who are aged between 55 years and 69 years, the taking of periodic serum PSA based screening should be an individual choice based upon the advice of USPSTF [7]
 - It has been iterated that screening in this age group does offer a small potential benefit of reducing the chance of death from prostate cancer in some men; however, many men will experience potential harm [7] [29]
 - It has been iterated that the American Urological Association (AUA) does not recommend serum PSA screening in men, who under age 40 years or in men aged 40 - 54 years at average risk [7]
 - For men who are aged between 55 years and 59 years, shared decision making has been stated to be desirable [7]
 - For men who are aged 70 years and over 70 years of age or men have less than (<) 10 years and between 10 years and 15 year life expectancy, serum PSA screening is generally, not recommended [7] [30]
- Potential urine biomarker for prostate cancer is PCA3 [7]

Radiology description

The radiology-image features of prostate cancer had been summated as follows; [7]

- Ultrasound scan (USS) is generally used to guide prostate biopsies; and prostate cancer may appear upon ultrasound scan images as hypo-echoic but USS is neither sensitive nor specific for the diagnosis of prostate cancer [7]
- Multiparametric MRI scan is commonly used for the local tumour staging and it may also be used to identify abnormalities for targeting at biopsy of the prostate gland [7]
- MRI abnormalities are generally reported using either PI-RADS (Prostate Imaging - Reporting and Data System) or Likert score [7]
- CT scan is used to identify metastatic disease within lymph nodes [7]
- Bone scan is used to identify bone metastases [7]
- PET scan is used to detect micro-metastatic disease in selected patients, such as men with raised PSA levels after treatment [7]

Prognostic factors

The factors of prognostication associated with adenocarcinoma of the prostate gland had been summated as follows: [7]

- **Biopsy:** with regard to the pathology examination features of the prostate biopsy specimens, the extent of the tumour which has been assessed and documented in terms of mm measurement or percentage core involvement by the tumour, the grade of the tumour (Gleason score and grade group), perineural invasion, extra-prostatic extension, does determine the prognosis associated with the tumour
- **Radical prostatectomy:** With regard to radical prostatectomy specimens, it has been iterated that the size of the tumour, the Gleason score of the tumour and the tumour grade group, the stage of the tumour, and the excision margin status of the tumour documenting absence or presence of tumour at the surgical excision margin represent factors that determine the prognosis of the tumour [7]
- It has been iterated that during pathology examination of the prostate cancer specimen the finding of Cribriform morphology and intraductal carcinoma tends to be associated with invasive prostate cancer are adverse prognostic indicators [7] [31]
- It has been iterated that in a case of primary adenocarcinoma of the prostate gland, the finding of a small cell carcinoma component of the tumour is associated with a tumour that portends an aggressive behaviour and the tumour should be treated differently [7]

- Some expert groups recommend incorporating intraductal component into the Gleason score while others recommend reporting it separately in a comment [7] [32] [33] [34]

Treatment

- The treatment of primary adenocarcinoma of prostate gland has been summated as follows: [7]
- Preoperative risk stratification of adenocarcinoma of the prostate gland is based upon serum PSA level, clinical stage of the tumour, biopsy parameters of the tumour including: the extent of the tumour, the histopathology grade of the tumour, presence and absence and extent of cribriform morphology features of the tumour, intraductal carcinoma, as well as presence or absence of peri-neural invasion [7]
- Primary treatment options of adenocarcinoma of the prostate gland are based upon pre-operative risk stratification including: [7]
 - Active surveillance
 - Focal therapy (cryotherapy, high intensity ultrasound)
 - Radical prostatectomy
 - Brachytherapy
 - External beam radiotherapy
 - Hormone therapy (e.g., luteinizing hormone releasing hormone [LHRH] analogues, antiandrogens)
 - Orchiectomy (rare in contemporary practice)
 - Chemotherapy (for metastatic disease)
- Postprostatectomy options:
 - Generally, PSA monitoring and early salvage therapy if rising serum PSA
 - Less commonly adjuvant therapy for high stage disease or margin positivity

Gross description

Macroscopy pathology examination features of adenocarcinoma of prostate gland specimens had been summated as follows: [7]

- Often macroscopy examination of the prostate gland in carcinoma of prostate tends to demonstrate grossly an inapparent tumour or what would be described no examination features of the prostate gland to suggest cancer
- At times gross examination of the prostate gland may demonstrate formation of a cream mass

Microscopic (histologic) description

Microscopy pathology examination features of adenocarcinoma of the prostate gland has been summated as follows: [7]

- Gleason grading of adenocarcinoma of the prostate gland is stated to be based upon the architecture of the tumour [7]
- It has been iterated that the Gleason grades of the tumour represent a morphological spectrum from well-formed glands (pattern 3) to increasingly complicated glandular proliferations (pattern 4) to almost no glandular differentiation (pattern 5) [7] [35]
- Glandular crowding and infiltrative growth pattern [7]
- Nuclear enlargement, nucleolar prominence [7]
- Round generally monomorphic nuclei [7]
- Amphophilic cytoplasm [7]
- Mitoses [7]
- Apoptotic bodies [7]
- Stromal desmoplasia [7]
- Intraluminal contents: crystalloids, pink amorphous secretions, blue mucin [7]
- Glomerulations, collagenous micronodules (mucinous fibroplasia) [7]
- Absence of basal cell layer (generally requires immunohistochemical confirmation) [7]
- There had been an extensive history of exploring urine as a source of biomarkers for prostate cancer that had resulted in a variety of urine tests that are in current clinical use. Importantly, at least three tests had demonstrated high sensitivity (~90%) and negative predictive value of about 95% for clinically significant tumours; nevertheless, there had not been widespread adoption of these tests. [36] Conceptual and methodological advances in the field will help to drive the development of novel urinary tests that in turn may lead to a shift in the clinical paradigm for prostate cancer diagnosis and management. [36] [37]

Cytology description

- Urine cytology for detecting prostate cancer is stated to have a very low sensitivity [7] [37]
- It has been pointed out that urine cytology is not used clinically in the diagnosis of prostate cancer [7]
- It has been iterated that FNA of metastatic prostate cancer to a lymph node may show micro-acinar complexes / cell clusters / single cells with fragile cytoplasm and prominent nucleoli [7] [38]
- Positive stains
- It has been iterated that tumour cells of adenocarcinoma of the prostate gland upon immunohistochemistry staining studies exhibit positive staining for the ensuing tumour markers: [7]
 - **PSA**
 - **NKX3.1**
 - **AMACR** (P504S, racemase)
 - **Prostein** (P501S)

- **PSMA**
- Rare tumours may exhibit aberrant expression of p63 [7] [39] [40]

Negative stains

It has been iterated that tumour cells of adenocarcinoma of the prostate gland upon immunohistochemistry staining studies exhibit negative staining for the ensuing tumour markers: [7]

- **CK7**
- **CK20**
- High molecular weight cytokeratins (**34 beta E12, CK5, CK5/6**)
- **p63**
- **CDX2**
- **GATA3**
- **TTF1** [41]

Molecular / cytogenetics description

The molecular / cytogenetics features of adenocarcinoma of the prostate gland had been summated as follows: [7]

- Prostate cancer is stated to be a heritable disease [7]
- It has been iterated that a family history of a first degree relative with prostate cancer increases the risk of developing prostate cancer by 2-fold [7] [42]
- 30 - 40% of familial risk is due to genetic factors [20]
- Genetic factors include highly penetrable rare variants and more common low to moderate risk variants [20]
- Highly penetrant variants occur in BRCA2 and HOXB13 [7]
- Over 280 SNPs have been identified as prostate cancer risk factors [20]
- For most SNPs, the molecular mechanism of cancer association is generally unknown, as they occur in noncoding regions of the genome [20]
- Somatic mutations occur in genes such as ERG, ETV1/4, FLI1, SPOP, FOXA1, IDH1, PTEN, TP53, MYC, CDH1 [20][43]
- Most common somatic genomic rearrangement is fusion of the androgen regulated gene TMPRSS2 with a member of the ETS transcription family [20]
- Somatic mutation profiles of prostate cancer are associated with clinical and pathological outcomes [7]
 - There are 7 major subtypes, which are defined by either specific gene fusions of ETS transcription family members (ERG, ETV1, ETV4 and FLI1) or mutations (SPOP, FOXA1, IDH1) [43]
- It has been iterated that different sub-types of prostate cancer have different molecular profiles, for example [43]:
 - ETS subset (59% of cases) are enriched in PTEN mutations
 - SPOP mutant subset (11%) of cases have distinct somatic copy number alteration profiles, including deletions of CHD1, 6q and 2q

Differential diagnoses

The differential diagnoses of prostate cancer had been summated as follows: [7]

- **Benign prostate tissue:**
 - Pale cytoplasm
 - Corpora amylacea
 - No other intraluminal contents
 - Basal cell marker immunoreactivity
- **Prostate atrophy:**
 - Lobular architecture
 - Scant cytoplasm
 - Basal cell marker immunoreactivity
- **Adenosis:**
 - Lobular architecture
 - Basal cell marker immunoreactivity (often scattered)
- **Atypical small acinar proliferation (ASAP):**
 - Small size
 - Lack of significant cytological atypia, including a lack of macronucleoli
- **High grade prostatic intraepithelial neoplasia (HGPIN):**
 - Less architectural atypia
 - Maintained basal cells
- **Post-atrophic hyperplasia:**
 - Some glands atrophic
 - Basal cell marker immunoreactivity (often scattered)
- **Partial atrophy:**
 - Atrophic glands with abundant lateral pale cytoplasm
 - Irregularly distributed nuclei
 - Basal cell marker immunoreactivity (often scattered)
- **Radiation atypia:**

- Glandular atrophy
- Nuclear irregularity and pleomorphism
- Atypical stromal cells
- Basal cell marker immunoreactivity
- **Urothelial carcinoma:**
 - Nuclear irregularity and pleomorphism
 - Hyaline dense eosinophilic cytoplasm
 - Desmoplastic stromal reaction
 - Immunoreactivity for urothelial markers (GATA3, CK7, p63)
 - No expression of prostatic immunomarkers (PSA, PSAP, NKX3.1)

[B] Miscellaneous Narrations from Some Case Reports, Case Series and Studies Related to Irreversible Electroporation of Prostate Cancer

Prabhakar et al. [1] made the ensuing iterations:

- Irreversible electroporation (IRE) is a new and promising focal therapy for the treatment of localized prostate cancer.
- they had summarized the literature on IRE for prostate cancer which had been published over the last decade preceding 2024.

Prabhakar et al. [1] searched PubMed and EMBASE with the end date of May 2023 to find relevant publications on prostate cancer ablation using IRE. They included original studies with focal IRE as the primary curative treatment which reported on functional or oncological outcomes were included. They also scanned bibliography of relevant studies to identify suitable articles. Prabhakar et al. [1] summated the results as follows:

- They had included a total of 14 studies reporting on 899 patients treated with IRE for localized prostate cancer.
- Out of all the studies they had reviewed, 77% had reported on recurrence within the zone of ablation, and it had ranged from 0% to 38.9% for in-field and 3.6% to 28% for out-of-field recurrence.
- Even though, a standardised follow-up protocol was not followed, all the studies had employed serial prostate-specific antigen monitoring, a multiparametric magnetic resonance imaging, and a biopsy at between 6 months and 12 months pursuant to the IRE -treatment.
- Across all the studies, 58% had reported that the urinary continence had returned to the pretreatment levels and 25% had reported a minor decrease in the continence from the baseline at 12-months of follow-up.
- Erections sufficient for intercourse had varied from 44% to 75% at the baseline to 55% to 100% at 12-months of follow-up across all the studies.

Prabhakar et al. [1] made the ensuing conclusions:

- IRE, as a focal therapy, had demonstrated promising results with minimal complications and reasonably effective oncological control, but the data comparing it to the standard of care was still lacking.
- Future research should focus upon randomized definitive comparisons between IRE, radical prostatectomy, and radiotherapy.

Blazevski et al. [44] assessed the safety, oncology as well as quality-of-life (QoL) outcomes of focal ablation of apical prostate cancer (PCa) lesions with irreversible electroporation (IRE). Blazevski et al. [44] included patients in the study if they had a PCa lesion within 3 mm of the apical capsule treated with IRE. The IRE procedure was undertaken in their institution by a single urologist. Blazevski et al. [44] collected the QoL and functional data prospectively from patients who had provided consent using the Expanded Prostate Cancer Index Composite (EPIC). The oncology follow-up included the obtaining of 3-month serum PSA levels, mpMRI at 6 months and trans-perineal biopsy at 1-year post treatment. Blazevski et al. [44] summated the results as follows:

- A total of 50 patients had apical PCa lesions which were treated between February 2013 and September 2018.
- The median follow-up was 44 months.
- There were no Clavien-Dindo grade 3 events or higher.
- No perioperative complications were documented.
- No significant difference was observed in the EPIC urinary or bowel QoL domain between baseline and 12-month post-treatment.
- One patient that amounted 2% of the patients required one pad per day for urinary incontinence 12-month post-treatment.
- There was a small but significant decline in EPIC sexual QoL (65 at baseline and 59 at 12-month post-IRE).
- Out of patients who were potent pre-treatment, 94% had remained potent after their treatments.
- The median serum PSA nadir had decreased by 71% (6.25-1.7 ng/mL).
- Only one patient which amounted to 2.5% of the patients had in-field residual disease upon pathology examination of his repeat prostate biopsy specimen.

Blazevski et al. [44] concluded that focal ablation using IRE for PCa in the distal apex appeared to be safe and feasible with acceptable early QoL and oncology outcomes.

Yaxley et al. [45] made the ensuing iterations:

- Focal irreversible electroporation (IRE) for prostate cancer is aimed to reduce quality of life complications; nevertheless, outcomes data had remained limited.
- They had aimed to evaluate the histopathology in-field clearance of prostate cancer at ≥ 12 months post-IRE.

Yaxley et al. [45] undertook a retrospective review of prospectively acquired data of consecutive patients who had been treated between August 2018 and August 2021. They defined significant recurrence as a ≥ 6 mm core Gleason 3+3, or \geq Gleason 3+4 with ≥ 4 mm tumour length. They also analysed a second definition of any focus of International Society of Urological Pathology (ISUP) ≥ 2 . Yaxley et al. [45] summated the results as follows:

- The median follow-up of the entire cohort of patients was 23 months and the follow-up had ranged between 3 months and 39 months.
- For 64 primary IRE procedures, surveillance biopsy was undertaken in 40 patients out of 50 patients which amounted to 80.0% with ≥ 12 months follow-up.
- Significant in-field recurrence had occurred in 3 patients out of 40 patients which amounted to 7.5% of the patients, or in 4 patients out of 40 patients which amounted to in 10.0% of patients with any focus of ISUP >2 .
- Significant out-of-field recurrence had occurred in 5 patients out of 40 patients which amounted to in 12.5% of the patients.
- In salvage IRE, three patients (3/6, 50.0%) had undetectable prostate-specific antigen levels, two had no residual cancer upon pathology examination of their prostate biopsy specimens and one patient had out-of-field recurrence.
- For sexually active men, erectile function was maintained in 24 patients out of 28 patients which amounted to in 85.7% of primary IRE.
- No incontinence had developed in primary IRE (0/64).

Yaxley et al. [45] made the ensuing conclusions:

- Surveillance prostate biopsies are needed to exclude progression despite a normal post-IRE multiparametric magnetic resonance imaging (mpMRI).
- Salvage IRE is a promising option for localised recurrence after radiotherapy of prostate cancer with low morbidity.
- Focal IRE for primary PCa is associated with complete in-field ablation of all cancer in 87.5% based on post-IRE biopsy, or 90% of any core length of ISUP grade 2.
- There was minimal postoperative complications and a low risk of post treatment urinary incontinence or impotence.

Scheltema et al. [46] evaluated the feasibility, safety, early quality-of-life (QoL) and oncological outcomes of salvage focal irreversible electroporation (IRE) for radio-recurrent prostate cancer (PCa). Scheltema et al. [46] offered to patients who had localized, radio-recurrent PCa without evidence of metastatic or nodal disease focal IRE according to the consensus guidelines. Scheltema et al. [46] iterated that patients who had a minimum follow-up of 6 months were eligible for analysis. Scheltema et al. [46] monitored adverse events using the National Cancer Institute Common Terminology Criteria for Adverse Events (CTCAE version 4.0). Scheltema et al. [46] collected patient-reported QoL data at baseline, 6 weeks, 3 months, 6 months and 12 months using the Expanded Prostate Cancer Index Composite (EPIC), the American Urological Association (AUA) symptom score and the 12-item short-form health survey (SF-12) physical and mental component summary questionnaires. Scheltema et al. [46] evaluated the oncology control according to serial prostate-specific antigen (PSA), 6-month multiparametric magnetic resonance imaging (mpMRI) and 12-month prostate biopsy. Scheltema et al. [46] used Wilcoxon's signed rank test to assess QoL differences over time in paired continuous variables. Scheltema et al. [46] summated the results as follows:

- A total of 18 patients were included in the analysis.
- The median follow-up was 21 months.
- No high-grade adverse events (CTCAE >2) or recto-urethral fistulae had developed.
- No statistically significant declines were identified in QoL outcomes ($n = 11$) on the EPIC bowel domain ($P = 0.29$), AUA symptom score ($P = 0.77$), or the SF-12 physical ($P = 0.17$) or SF-12 mental component summary ($P = 0.77$) questionnaires.
- At 6 months, patients who had undergone salvage therapy had experienced a decline in EPIC sexual domain score (median of 38-24; $P = 0.028$) and urinary domain (median of 96-92; $P = 0.074$). Pad-free continence and erections sufficient for intercourse were preserved in 8/11 patients and 2/6 patients at 6 months, respectively.
- The mpMRI was clear in 11 out of 13 patients, with two single out-field lesions (true-positive and false-positive, respectively).
- The median (interquartile range) nadir serum PSA was 0.39 (0.04-0.43) $\mu\text{g/L}$.
- Three and four patients had experienced biochemical failure utilising the Phoenix and Stuttgart definitions of biochemical failure, respectively.
- Eight out of 10 of the patients were clear of any PCa on follow-up biopsy, whereas two patients had significant PCa on follow-up biopsy (International Society of Urological Pathology grade 5).

Scheltema et al. [46] made the ensuing conclusions:

- Their short-term safety, QoL and oncological control data had shown that focal IRE is a feasible salvage option for localized radio-recurrent PCa.
- A prospective multicentre study (FIRE trial) had been commenced that would provide further insight into the ability of focal IRE to obtain oncological control of radio-recurrent PCa with acceptable patient morbidity.

Blazevski et al. [47] iterated that focal irreversible electroporation (IRE) could be utilised to treat men who are afflicted by localised prostate cancer (PCa) with reduced impact upon quality of life (QoL). Blazevski et al. [47] assessed the oncological and functional outcomes of patients who had undergone treatment of localised prostate cancer with IRE. Blazevski et al. [47] reported on a prospective database of patients who had undergone primary IRE between February 2013 and August 2018. A minimum of 12-mo follow-up was available for 123 patients. The median follow-up of the patients was 36 months

(interquartile range [IQR] 24-52 mo). A total of 112 (91%) patients had National Comprehensive Cancer Network intermediate risk and 11 (9%) had low risk. A total of 12 (9.8%) had International Society of Urological Pathology (ISUP) grade 1, 88 (71.5%) had ISUP 2, and 23 (18.7%) had ISUP 3. The treatment the patients had entailed focal IRE ablation of their PCa lesions. The follow-up of the patients entailed the undertaking of serial serum prostate-specific antigen (PSA), multiparametric magnetic resonance imaging (mpMRI), and trans-perineal template mapping biopsy (TTMB) at 12 mo. Failure-free survival (FFS) was defined as progression to whole-gland or systemic treatment or metastasis/death. Functional outcomes were assessed.

Blazevski et al. [47] summated the results as follows:

- The median age of the patients was 68yr (IQR 62-73yr).
- The median pre-operative serum PSA level was 5.7ng/ml (IQR 3.8-8.0ng/ml).
- On post-treatment TTMB, in-field recurrence was present in 2.7-9.8% of patients. FFS at 3yr was 96.75%, metastasis-free survival 99%, and overall survival 100%.
- A total of 18 patients had required salvage treatment (12 had repeat IRE; six had whole-gland treatment).
- The negative predictive value of mpMRI was 94% and sensitivity 40% for detecting in-field residual disease 6 months after treatment.
- Among patients who had returned their questionnaires, 80 out of 81 patients which amounted to 98.8% of the patients had remained pad free and 40 out of 53 patients which amounted to 76% of the patients had no change in their erectile function.

Blazevski et al. [47] made the ensuing conclusions and summation:

- Focal IRE in select patients with localized clinically significant PCa has satisfactory short-term oncology outcomes with a minimal impact on patient QoL.
- In their study, 123 patients had undergone focal therapy utilising irreversible electroporation.
- Follow-up biopsy was clear of residual disease in 90.2-97.3% of patients.
- Out of the patients, 96.75% had avoided whole gland treatment at 3years.

van den Bos et al. [48] determined the safety, quality of life (QoL) and short-term oncology outcomes of primary focal irreversible electroporation (IRE) for the treatment of localized prostate cancer (PCa), as well as they identified the potential risk factors for oncology failure of focal irreversible electroporation of prostate cancer. van den Bos et al. [48] reported that patients who had met the consensus guidelines on patient criteria and selection methods for primary focal therapy were eligible for analysis. Focal IRE was undertaken for organ-confined clinically significant PCa, which was defined as high-volume disease with Gleason sum score 6 (International Society of Urological Pathology [ISUP] grade 1) or any Gleason sum score of 7 (ISUP grades 2-3). van den Bos et al. [48] analysed the Oncological, adverse event (AE) and QoL outcome data, with a minimum of 6 months' follow-up. van den Bos et al. [48] compared patient characteristics and peri-operative treatment variables between patients with and without oncological failure on follow-up biopsy. van den Bos et al. [48] used Wilcoxon's signed rank test, Wilcoxon's rank sum test and the chi-squared test to assess statistically significant differences in paired continuous, unpaired continuous and categorical variables respectively. van den Bos et al. [48] summated the results as follows:

- A total of 63 patients met all eligibility criteria and were included in the final analysis.
- No high-grade AEs had occurred.
- QoL questionnaire analysis had revealed no significant change from baseline in physical ($P = 0.81$), mental ($P = 0.48$), bowel ($P = 0.25$) or urinary QoL domains ($P = 0.41$ and $P = 0.25$), but there was a mild decrease in the sexual QoL domain (median score 66 at baseline vs 54 at 6 months; $P < 0.001$).
- Compared with baseline, a decline of 70% in serum prostate-specific antigen level (1.8 ng/mL, interquartile range 0.96-4.8 ng/mL) was observed at 6 months to 12 months.
- A narrow safety margin ($P = 0.047$) and system errors ($P = 0.010$) had been identified as potential early risk factors for in-field oncological failure.
- In-field and whole-gland oncology control on follow-up biopsies was 84% (38/45 patients) and 76% (34/45 patients); this increased to 97% (38/39 patients) and 87% (34/39 patients) when patients treated with a narrow safety margin and system errors were excluded.

van den Bos et al. [48] concluded that their data had supported the safety and feasibility of focal IRE as a primary treatment for localized PCa with effective short-term oncological control in carefully selected men.

Karagiannis et al. [49] made the ensuing iterations:

- Even though still considered to be experimental, focal irreversible electroporation (IRE) as a primary treatment for prostate cancer (PCa) which is considered to be one of the most promising ablative technology options for focal therapy.
- They had undertaken review of the literature and provided a description of the principle of IRE for the treatment of PCa, combined with an overview of the recent research.
- Their recent findings included the ensuing:
 - It had been almost a decade since the first human studies of focal IRE for PCa were trying to demonstrate its feasibility and safety, and recently new data had been emerging regarding the functional and oncological outcomes.
 - It had been demonstrated that the expected ablation efficacy of IRE is dependent upon increased safety margins of > 9 mm and an uninterrupted IRE procedure, but these findings need further investigation in larger cohorts and randomized control trials (RCT).

- Recent data from larger cohorts with a longer follow-up of up to 12 months had proven that focal IRE as primary treatment for localized PCa is indeed safe, and is associated with an effective short-term oncological control in selected patients, and it has good functional outcomes by retaining urinary function and causing only mild erectile dysfunction.

Blazevski et al. [50] made the ensuing iterations:

- Whilst whole-gland radical treatment is highly effective for the control of prostate cancer, it does have significant impact upon the quality of life and it represents an unnecessary 'over-treatment' in many men who are found to have screening-detected prostate cancer.
- Improvements in the undertaking of prostate biopsy and imaging have led to increased interest in partial gland ablation so as to reduce treatment-related morbidity.
- Many energies for focal ablation had been trialled.
- Irreversible electroporation (IRE) is a new technology which ablates tissue by delivering direct current between electrodes.
- They have provided a narrative review which has narrated the history of electroporation including its scientific basis, early data from pre-clinical animal studies, and contemporary clinical outcomes from the use of IRE in prostate cancer.

Blazevski et al. [50] undertook a literature search using the Medical Literature Analysis and Retrieval System Online (MEDLINE), the Excerpta Medica data BASE (EMBASE), PubMed and Google Scholar in order to identify historical perspectives and current clinical data relating to IRE for prostate cancer. Blazevski et al. [50] summated the results as follows:

- The history of electroporation and its implementation as a prostate cancer therapy was had followed the basic scientific principles, in vitro data, then animal studies, and now short- to medium-term clinical cohorts in humans.
- The results of IRE on more than 283 patients had been published in many papers, with preserved rates of (pad-free) continence in between 91% and 100% of men and preserved erectile function in between 79% and 100% of men.
- In-field recurrence rates that had been reported had ranged from 0% to 33%.
- The current state of evidence for IRE for the treatment of primary and salvage prostate cancer is considered as Idea, Development, Exploration, Assessment, Long-term follow-up (IDEAL) stage 2B.

Blazevski et al. [50] made the ensuing conclusions:

- IRE is a novel focal ablative technology for the treatment of localised prostate cancer in carefully selected men.
- Published cohorts had documented encouraging short-term oncological and functional outcomes; nevertheless, longer-term data are required in order to validate this treatment before it could be recommended for widespread clinical usage.

Diven et al. [51] made the ensuing iterations:

- Radiotherapy and Irreversible Electroporation for Intermediate Risk Prostate Cancer (RTIRE) is a phase II clinical trial testing combination of radiation therapy and irreversible electroporation for intermediate risk prostate cancer
- PCa is the most common non-cutaneous cancer in men and the second leading cause of cancer death in men.
- PCa treatment is associated with long term side effects including urinary, sexual, and bowel dysfunction.
- The management of PCa is based upon risk stratification in order to avoid its overtreatment and associated treatment-related toxicity.
- There is increasing interest in new treatment options, such as focal therapy, to minimize treatment associated morbidity.
- Focal therapy alone has yet to be included in mainstream guidelines, given ongoing concerns with potentially higher risk of recurrence.
- They had hypothesized that combining focal therapy with whole gland, reduced dose radiotherapy would provide acceptable oncological efficacy with minimal treatment associated morbidity. RTIRE is a phase II single institution, investigator-initiated study combining a local ablative technique though local irreversible electroporation (IRE) with MR guided RT (MRgRT) to treat the entire prostate.
- The goal is to provide excellent oncology outcomes and to reduce treatment related side effects through leveraging benefits of locally ablative therapy with established radiation treatment techniques.

Diven et al. [51] stated that a total of 42 men with intermediate risk PCa per NCCN guidelines and focal grade group (GG) 2 or 3, Gleason Score (GS) 3 + 4 or GS 4 + 3, cancer in an MRI target would be enrolled in their study. Patients who are found to have MRI scan visible foci of GG2/GG3 would undergo focal therapy with IRE of this lesion. Following successful focal therapy, the patients would then undergo a course of reduced dose, whole gland MRgRT with either 32.5 Gy in 5 Fractions or 22 Gy in 2 fractions. The primary objective of the study is to determine safety. Secondary outcomes would include evaluation of oncologic efficacy (as measured by the proportion of patients free of clinically significant cancer as defined as > Grade Group 1 at 1-year follow-up biopsy), imaging characteristics of patients pre and post RTIRE, impact on quality of life (QoL), and PSA kinetics. Diven et al.

[51] made the ensuing conjectural discussion:

- Combining IRE with a reduced dose radiotherapy might offer a new treatment paradigm for PCa by both reducing treatment effects of full dose radiotherapy and minimizing the risk of recurrence observed with focal therapy.

Teramoto et al. [52] compared the comprehensive clinical outcomes of focal therapy (FT) and robot-assisted radical prostatectomy (RARP) in patients who had localized prostate cancer (PC) using a win ratio analysis. Teramoto et al. [52]

analysed pursuant to a propensity score matching, a win ratio analysis, in which the composite endpoints of failure-free survival (FFS) and the urinary domain of the Expanded Prostate Cancer Index Composite (EPIC) for the comparison of the clinical outcomes of FT and RARP for the patients who had localized PC. Teramoto et al. [52] included seventy-two patients in each group after propensity score matching. Teramoto et al. [52] summated the results as follows:

- FFS was found not to be significantly different between the groups ($p = 0.5044$) after 36 months of follow-up. In contrast, the score of the urinary domain of the EPIC in the FT group was significantly better than that in the RARP group ($p < 0.0001$).
- The win ratio of FT per RARP was noted to be 3.39 ($p < 0.0001$; 95% confidence interval 2.21-5.20), indicating a higher comprehensive outcome in the FT group than in the RARP group during short-term follow-up in single institution.

Teramoto et al. [52] concluded that:

- Even though further randomized trial with long-term follow-up would be required for the evaluation, the win ratio would be useful to analyse the efficacy of FT according to patient preferences comprehensively.
- Faiella et al. [53] evaluated the most recent research from 2000 to 2023 in order to deeply investigate the applications of PCa IRE, first exploring its usage with primary intent and then salvage intent. Finally, Faiella et al. [53] discussed the differences with other focal PCa treatments. Faiella et al. [53] summated the results as follows:
- In the case of primary-intent IRE, the in-field recurrence was quite low (ranges from 0% to 33%).
- Urinary continence ensuing the treatment had remained high in that it was greater than in 86% of the cases.
- In view of the many different patients in the studies, the preserved potency had varied quite a lot of between 59% and 100%.
- With regard to complications, the highest occurrence rates were for those of Grades I and II (20-77% and 0-29%, respectively). Grade III complications represented less than 7%.
- Regarding the specific oncology outcomes, both PCa-specific survival and overall survival were 100%. Metastasis-free survival was 99.6%.
- In a long-term study, the Kaplan-Meier FFS rates that were reported were 91% at 3 years, 84% at 5 years, and 69% at 8 years.
- In the single study with salvage-intent IRE, the in-field recurrence was found to be 7%. Urinary continence was still high at 93%, but preserved potency was significantly lower than primary-intent IRE patients of 23%. In addition, Grade III complications were noted to be slightly higher, which had occurred in 10.8% of the cases.

Faiella et al. [53] concluded that:

- In males with localized low-intermediate-risk prostate cancer, IRE had an excellent safety profile and might have positive results for sexual and urinary function.

Schmid et al. [54] reported a 72-year-old male patient who had manifested with elevated PSA (4.0ng/mL) during his routine testing. To investigate his slightly increased PSA value, he had multiparametric magnetic resonance imaging (MRI) of the prostate gland, which demonstrated a 0.8cm ill-defined lesion within the posterolateral aspect of the right mid-gland with marked hypo-intensity on ADC (ACR PI-RADS 4) (see Figure 1). The patient was otherwise healthy, with no relevant past medical history. Next, a trans-perineal prostate gland biopsy was undertaken, and as per institutional protocol, 18 random samples and four MRI-targeted samples were obtained (see Figure 2). The resulting analysis had demonstrated that only one of these prostate specimens was positive for acinar adenocarcinoma (Gleason Score 3+3=6; International Society of Urological Pathology=1). The risks and benefits associated with all the management options were discussed with the patient. He felt that prostatectomy at that point was too radical for what seemed to be a rather unaggressive/early-stage tumour and would entail complications that he was not willing to undertake. He was also not in favour of a watchful waiting approach. Hence, ensuing discussions of local therapies, IRE ablation was chosen as the treatment method. The procedure was undertaken under general anaesthesia, utilising 2g of Ceftriaxone as antibacterial prophylaxis. The patient was placed in the lithotomy position, and his scrotum was elevated and held out of the way using tape to expose the perineum, which was prepared with chlorhexidine solution. The IRE was undertaken using the NanoKnife® system (AngioDynamics, Queensbury, NY, USA) and three 15cm x 19G electrodes (NanoKnife, AngioDynamics, Latham, NY, USA) with an exposure of 4cm surrounding the lesion (Figure 2). A biplanar endorectal ultrasound probe (6–12 MHz, Canon Aplio a, Otawara, Japan) coupled with real-time fusion of the previous MRI was used to guide probe insertion. A 10-pulse test of this setup was carried out to adjust the voltage between the probes, and then two therapeutic cycles of 80-pulse each were performed to obtain a current of over 20 A between the probes. No complications were observed. Thirty-two days after the procedure, serum PSA levels reduced to 1.04ng/mL and remained within normal limits (1.26ng/mL) after 349 days. Follow-up imaging performed after 90 days with prostate-specific membrane antigen (PSMA) PET/MRI (Figure 1) showed size reduction, retraction, and diffuse hypo-intensity in the peripheral zone of the right prostate lobe, with no increased PSMA uptake. An MRI which was undertaken 367 days pursuant to the IRE demonstrated no suspicious lesions (Figure 3). At the final clinical follow-up at 390 days, the patient was asymptomatic.

Schmid et al. [54] concluded that:

- Irreversible electroporation is a safe and promising option of treatment which should be considered during treatment planning for patients who are afflicted by prostate cancer.

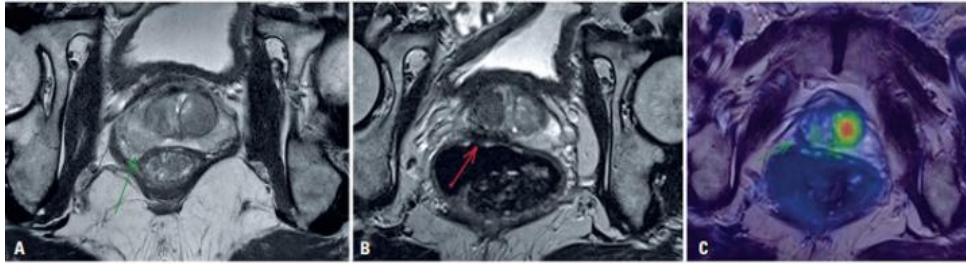


Figure 1: Imaging findings. Magnetic resonance imaging using a T2 weighted sequence shows (A) a slightly hypointense lesion on the right midgland. (B) a markedly hypointense region after treatment on T-2 weighted sequence, and (C) no increased uptake of prostate-specific membrane antigen on PET/CT after treatment.

Reproduced from: [54] under the Creative Commons Attribution License.

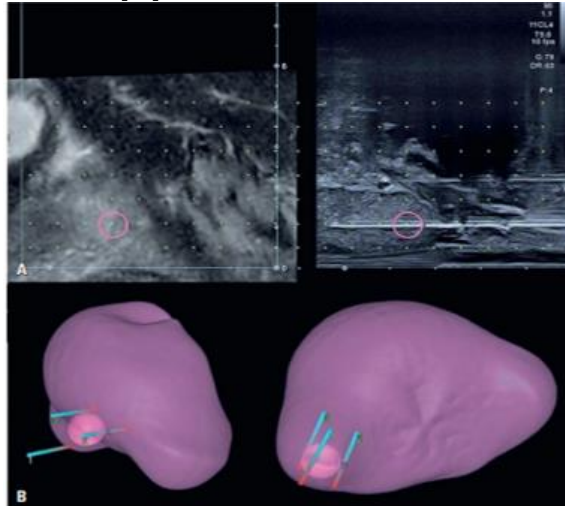


Figure 2: Transperineal biopsy. A) A real-time fusion of the prostate MRI coupled with the sagittal view of the transrectal ultrasound during the transperineal biopsy of the nodule. B) A 3D reconstruction depicts the position of the electroporation probes relative to the prostatic nodule. Reproduced from: [54] under the Creative Commons Attribution License.

Reproduced from: [54] under the Creative Commons Attribution License.

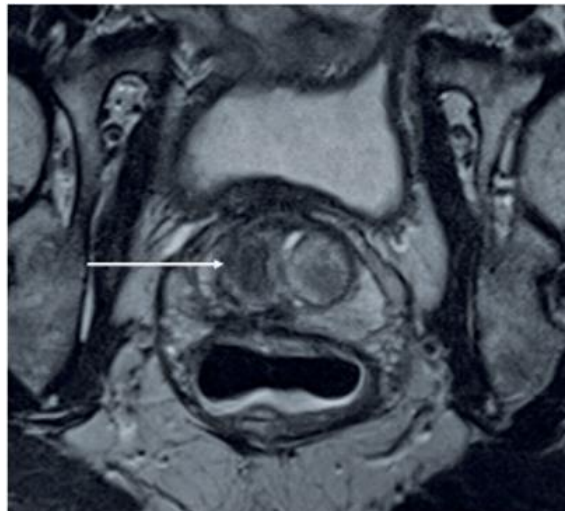


Figure 3: Magnetic resonance imaging (T2-weighted sequence) performed 367 days after irreversible electroporation shows no suspicious lesions. The ablation area appears with marked hypointensity (white arrow). Reproduced from: [54] under the Creative Commons Attribution License.

Colletini et al. [55] made the ensuing iterations:

- MRI–transrectal US fusion–guided irreversible electroporation is a safe and effective procedure for patients who have localized low- to intermediate-risk prostate cancer with promising midterm results, both in terms of urogenital toxicity and oncologic control.
- Irreversible electroporation (IRE) is a nonthermal ablative method which is based upon the formation of nanoscale defects in cell membranes leading to cell death.
- Clinical experience with the technique for treatment of prostate cancer had remained limited.

- MRI–transrectal US fusion–guided irreversible electroporation is a safe and effective procedure for patients with localized low- to intermediate-risk prostate cancer with promising midterm results, both in terms of urogenital toxicity and oncologic control.

Colletini et al. [55] evaluated urogenital toxicity and oncologic outcome of MRI–transrectal US fusion–guided IRE of localized prostate cancer. Colletini et al. [55] undertook a prospective study, of men with biopsy-proven, treatment-naive, low- to intermediate-risk prostate cancer (prostate-specific antigen [PSA], ≤ 15 ng/mL; Gleason score, $\leq 3 + 4$; clinical stage, $\leq T2c$; lesion size at multiparametric MRI, ≤ 20 mm) who had undergone focal MRI/transrectal US fusion–guided IRE between July 2014 and July 2017. The primary end point of the study was the urogenital toxicity profile of focal IRE by using participant-reported questionnaires. The secondary end points were biochemical, histologic, and imaging measures of oncologic control. Analyses were performed by using nonparametric and χ^2 test statistics. Colletini et al. [55] summarized the results as follows:

- They had included thirty men whose median age, was 65.5 years; and whose mean serum PSA level was 8.65 ng/mL and whose mean tumour size was 13.5 mm.
- One grade III adverse event (urethral stricture) had been documented.
- The proportion of men who had erection sufficient for penetration was 83.3% which accounted for 25 out of 30 patients at baseline and 79.3%, which accounted for 23 men out of 29 men; $P > .99$) at 12 months.
- Leak-free and pad-free continence rate was 90%, which accounted for 27 men out of 30 men at baseline and 86.2%, which accounted for 25 men out of 29 men; $P > .99$) at 12 months.
- Urogenital function had remained stable at 12 months according to changes in the modified International Consultation on Incontinence Questionnaire Male Lower Urinary Tract Symptoms, or ICIQ-MLUTS, and the International Index of Erectile Function, or IIEF-5, questionnaires ($P = .58$ and $P = .07$, respectively).
- Serum PSA level had decreased from a baseline median value of 8.65 ng/mL (interquartile range, 5–11.4 ng/mL) to 2.35 ng/mL (interquartile range, 1–3.4 ng/mL) at 12 months ($P < .001$).
- At 6 months, 28 of 30 participants had undergone post-treatment prostate biopsy.
- The rate of in-field treatment failure was noted to be 17.9%, which accounted for five men out of 28 men as determined with multiparametric prostate MRI and targeted biopsies at 6 months.

Colletini et al. [55] concluded that after a median follow-up of 20 months, focal irreversible electroporation of localized prostate cancer was found to be associated with low urogenital toxicity and promising oncologic outcomes.

Geboers et al. [56] stated that accurate monitoring following focal treatment of prostate cancer (PCa) is paramount for timely salvage treatment or retreatment. Geboers et al. [56] evaluated the diagnostic accuracy of multiparametric magnetic resonance imaging (mpMRI) to detect residual PCa in the short-term follow-up of focal treatment with irreversible electroporation (IRE) using trans-perineal or transrectal template \pm targeted biopsies. Geboers et al. [56] undertook a retrospective international multi-centre study of men with biopsy-proven PCa, treated with focal IRE, and followed by mpMRI (index-test) and template biopsies (reference-test) between February 2013 and January 2021. Geboers et al. [56] calculated the sensitivity, specificity, positive predictive value (PPV), and negative predictive value (NPV) of mpMRI for in- and outfield residual disease based on two definitions of significant PCa: University College London (UCL) 1-International Society of Urological Pathology (ISUP) ≥ 3 or ISUP ≥ 1 with maximum cancer core length (MCCL) ≥ 6 mm, and UCL2-ISUP ≥ 2 or ISUP ≥ 1 with MCCL ≥ 4 mm. Geboers et al. [56] summarized the results and limitations as follows:

- A total of 303 patients from five focal therapy centres were treated with primary IRE.
- The final analysis was undertaken on 217 men, whose median age was 67 years, and whose median serum prostate-specific antigen was 6.2, and 81% of whose ISUP was 2/3, who had undergone both mpMRI and template biopsies.
- Multiparametric MRI had missed 38 out of 57 (67%) positive biopsy locations (UCL1) in 22 patients.
- Sensitivity, specificity, PPV, and NPV of mpMRI to detect whole gland residual disease (UCL1) were 43.6% (95% confidence interval [CI]: 28-59), 80.9% (95% CI: 75-86), 33.3% (95% CI: 21-47), and 86.7% (95% CI: 81-91), respectively.
- Based upon UCL2, sensitivity, specificity, PPV, and NPV were 35.8% (95% CI: 25-48), 82.0% (95% CI: 75-88), 47.1% (95% CI: 34-61), and 74.1% (95% CI: 67-80), respectively.
- The limitations of the study, was iterated to be related to the retrospective nature and short follow-up of the study.

Geboers et al. [56] made the ensuing conclusion and patient summation:

- The diagnostic accuracy of mpMRI to identify residual clinically significant PCa following IRE was low.
- Follow-up template biopsies should be undertaken, regardless of mpMRI results.
- They had investigated the accuracy of magnetic resonance imaging (MRI) to detect residual prostate cancer after treatment with irreversible electroporation.
- The accuracy of MRI is insufficient, and they had emphasized the importance of confirmatory prostate biopsies.

Conclusions

- IRE is a new focal ablative treatment option for localised prostate cancer in carefully selected men.
- Published cohorts of treated patients with IRE of localized prostate cancer had reported encouraging short-term oncological and functional outcomes; nevertheless, longer-term data are required in order to validate this treatment before it could be recommended for widespread clinical usage.

Conflict Of Interest -Nil

Acknowledgements

Acknowledgements to:

- Einstein (Sao Paolo): For granting permission for reproduction of figures and contents of their Journal article under the Creative Commons Attribution License with the ensuing copyright iterations: Copyright the authors This content is licensed under a Creative Commons Attribution 4.0 International License

References

1. Prabhakar P, Avudaiappan AP, Sandman M, Eldefrawy A, Caso J, et al. (2024). Irreversible electroporation as a focal therapy for localized prostate cancer: A systematic review. *Indian J Urol.*;40(1):6-16.
2. Sung H, Ferlay J, Siegel RL, Laversanne M, Soerjomataram I, et al. (2021). Global Cancer Statistics 2020: GLOBOCAN Estimates of Incidence and Mortality Worldwide for 36 Cancers in 185 Countries. *CA Cancer J Clin.*;71(3):209-249.
3. Valerio M, Ahmed HU, Emberton M, Lawrentschuk N, Lazzari M, et al. (2014). The role of focal therapy in the management of localised prostate cancer: a systematic review. *Eur Urol.*;66(4):732-751
4. Hopstaken JS, Bomers JGR, Sedelaar MJP, Valerio M, Fütterer JJ, et al. (2021). An Updated Systematic Review on Focal Therapy in Localized Prostate Cancer: What Has Changed over the Past 5 Years? *Eur Urol.* 2022;81(1):5-33.
5. Wagstaff PG, Buijs M, van den Bos W, de Bruin DM, Zondervan PJ, et al. (2016). Irreversible electroporation: state of the art. *Onco Targets Ther.* 22;9:2437-2446.
6. Rubinsky B, Onik G, Mikus P. (2007). Irreversible electroporation: a new ablation modality--clinical implications. *Technol Cancer Res Treat.*;6(1):37-48.
7. (2024). Short E, Varma M. Adenocarcinoma.
8. NIH National Cancer Institute, Surveillance, Epidemiology, and End Results Program.
9. (2024). National Cancer Institute NIH: Cancer Facts. Common Cancer Sites. Statistics at a glance. *New Cancer cases.*
10. (SEER data available at NIH: Cancer Stat Facts - Prostate Cancer.
11. Zlotta AR, Egawa S, Pushkar D, Govorov A, Kimura T, et al. (2013). Prevalence of prostate cancer on autopsy: cross-sectional study on unscreened Caucasian and Asian men. *J Natl Cancer Inst.*;105(14):1050-1058.
12. Fahmy O, Khairul-Asri MG, Schubert T, Renninger M, Stenzl A, et al. (2016). Clinicopathological Features and Prognostic Value of Incidental Prostatic Adenocarcinoma in Radical Cystoprostatectomy Specimens: A Systematic Review and Meta-Analysis of 13,140 Patients. *J Urol.* 2017 Feb;197(2):385-390.
13. Rawla P. (2019). Epidemiology of Prostate Cancer. *World J Oncol.* 2019 Apr;10(2):63-89.
14. Løv M, Zhao S, Axcrona U, Johannessen B, Bakken AC, et al. (2018). Multifocal Primary Prostate Cancer Exhibits High Degree of Genomic Heterogeneity. *Eur Urol.* 75(3):498-505.
15. Reissigl A, Pointner J, Strasser H, Ennemoser O, Klocker H, et al. (1997). Frequency and clinical significance of transition zone cancer in prostate cancer screening. *Prostate.*;30(2):130-135.
16. Matzkin H, Patel JP, Altwein JE, Soloway MS. (1994). Stage T1A carcinoma of prostate. *Urology.*;43(1):11-21.
17. Lee JJ, Thomas IC, Nolley R, Ferrari M, Brooks JD et al. (2015). Biologic differences between peripheral and transition zone prostate cancer. *Prostate.*75(2):183-190.
18. Fine SW, Reuter VE. (2012). Anatomy of the prostate revisited: implications for prostate biopsy and zonal origins of prostate cancer. *Histopathology.* 60(1):142-152.
19. (2015). Cancer Genome Atlas Research Network. The Molecular Taxonomy of Primary Prostate Cancer. *Cell.* 163(4):1011-1025.
20. Faisal FA, Lotan TL. (2020). The Genomic and Molecular Pathology of Prostate Cancer: Clinical Implications for Diagnosis, Prognosis, and Therapy. *Adv Anat Pathol.* 27(1):11-19.
21. Lavalette C, Trétarre B, Rebillard X, Lamy PJ, Cénée S, et al. (2018). Abdominal obesity and prostate cancer risk: epidemiological evidence from the EPICAP study. *Oncotarget.*9(77):34485-34494.
22. Gann PH. (2002). Risk factors for prostate cancer. *Rev Urol.* 4 Suppl 5(Suppl 5):S3-S10.
23. Junejo NN, AlKhateeb SS. (2020). BRCA2 gene mutation and prostate cancer risk. Comprehensive review and update. *Saudi Med J.* 41(1):9-17.
24. Haraldsdottir S, Hampel H, Wei L, Wu C, Frankel W, et al. (2014). Prostate cancer incidence in males with Lynch syndrome. *Genet Med.* 16(7):553-557.
25. Allemailem KS, Almatroudi A, Alrumaihi F, Makki Almansour N, Aldakheel FM, et al. (2021). Single nucleotide polymorphisms (SNPs) in prostate cancer: its implications in diagnostics and therapeutics. *Am J Transl Res.*;13(4):3868-3889
26. Roberts CT Jr. (2004). IGF-1 and prostate cancer. *Novartis Found Symp* 262:193-9; discussion 199-204,
27. Ahmed HU, El-Shater Bosaily A, Brown LC, Gabe R, Kaplan R, et al. (2017). PROMIS study group. Diagnostic accuracy of multi-parametric MRI and TRUS biopsy in prostate cancer (PROMIS): a paired validating confirmatory study. *Lancet.*
28. (2024). National Comprehensive Cancer Network. NCCN Guidelines Prostate Cancer Early Detection. Version 2.
29. (2018). U S Preventive Task Force. USPTF. Prostate Cancer Screening.
30. (2018). American Urological Association. Early Detection of Prostate Cancer.
31. Kweldam CF, van der Kwast T, van Leenders GJ. (2018). On cribriform prostate cancer. *Transl Androl Urol.*;7(1):145-154.

32. van Leenders GJLH, van der Kwast TH, Grignon DJ, Evans AJ, Kristiansen G; et al. (2020). ISUP Grading Workshop Panel Members. The 2019 International Society of Urological Pathology (ISUP) Consensus Conference on Grading of Prostatic Carcinoma. *Am J Surg Pathol. Aug*;44(8): e87-e99.
33. Epstein JI, Amin MB, Fine SW, Algaba F, Aron M, Baydar DE, Beltran AL et al. (2021). The 2019 Genitourinary Pathology Society (GUPS) White Paper on Contemporary Grading of Prostate Cancer. *Arch Pathol Lab Med*;145(4):461-493
34. Varma M, Epstein JI. (2021). Head to head: should the intraductal component of invasive prostate cancer be graded? *Histopathology. 78*(2):231-239.
35. Short E, Warren A Y, Varma M. (2019). Gleason grading of prostate cancer: a pragmatic approach. *25*(10): 371-378.
36. Humphrey PA. (2017). Histopathology of Prostate Cancer. *Cold Spring Harb Perspect Med*;7(10):a030411.
37. Eskra JN, Rabizadeh D, Pavlovich CP, Catalona WJ, Luo J. (2019). Approaches to urinary detection of prostate cancer. *Prostate Cancer Prostatic Dis.*;22(3):362-381
38. Rosa M, Chopra HK, Sahoo S. (2007). Fine needle aspiration biopsy diagnosis of metastatic prostate carcinoma to inguinal lymph node. *Diagn Cytopathol. ;35*(9):565-567.
39. Tan HL, Haffner MC, Esopi DM, Vaghasia AM, Giannico GA et al. (2015). Prostate adenocarcinomas aberrantly expressing p63 are molecularly distinct from usual-type prostatic adenocarcinomas. *Mod Pathol. 28*(3):446-456.
40. Epstein JI, Egevad L, Humphrey PA, Montironi R; (2014). Members of the ISUP Immunohistochemistry in Diagnostic Urologic Pathology Group. Best practices recommendations in the application of immunohistochemistry in the prostate: report from the International Society of Urologic Pathology consensus conference. *Am J Surg Pathol 38*(8):e6-e19.
41. Epstein JI, Egevad L, Humphrey PA, Montironi R; (2014). Members of the ISUP Immunohistochemistry in Diagnostic Urologic Pathology Group. Best practices recommendations in the application of immunohistochemistry in the prostate: report from the International Society of Urologic Pathology consensus conference. *Am J Surg Pathol ;38*(8):e6-e19.
42. Eeles R, Goh C, Castro E, Bancroft E, Guy M, et al (2014). The genetic epidemiology of prostate cancer and its clinical implications. *Nat Rev Urol.*;11(1):18-31.
43. Inamura K. (2018). Prostatic cancers: understanding their molecular pathology and the 2016 WHO classification. *Oncotarget. 16*;9(18):14723-14737.
44. Blazeovski A, Amin A, Scheltema MJ, Balakrishnan A, Haynes AM, et al. (2021). Focal ablation of apical prostate cancer lesions with irreversible electroporation (IRE). *World J Urol. 39*(4):1107-1114.
45. Yaxley WJ, Gianduzzo T, Kua B, Oxford R, Yaxley JW. (2022). Focal therapy for prostate cancer with irreversible electroporation: Oncological and functional results of a single institution study. *Investig Clin Urol. 63*(3):285-293.
46. Scheltema MJ, van den Bos W, Siriwardana AR, Kalsbeek AMF, Thompson JE, et al. (2017). Feasibility and safety of focal irreversible electroporation as salvage treatment for localized radio-recurrent prostate cancer. *BJU Int. 120* Suppl 3:51-58.
47. Blazeovski A, Scheltema MJ, Yuen B, Masand N, Nguyen TV, et al. (2020). Oncological and Quality-of-life Outcomes Following Focal Irreversible Electroporation as Primary Treatment for Localised Prostate Cancer: A Biopsy-monitored Prospective Cohort. *Eur Urol Oncol. 3*(3):283-290.
48. van den Bos W, Scheltema MJ, Siriwardana AR, Kalsbeek AMF, Thompson JE, et al. (2018). Focal irreversible electroporation as primary treatment for localized prostate cancer. *BJU Int. 121*(5):716-724
49. Karagiannis A, Varkarakis J. (2019). Irreversible Electroporation for the Ablation of Prostate Cancer. *Curr Urol Rep. 2*;20(10):63.
50. Blazeovski A, Scheltema MJ, Amin A, Thompson JE, Lawrentschuk N, et al (2020). Irreversible electroporation (IRE): a narrative review of the development of IRE from the laboratory to a prostate cancer treatment. *BJU Int. 125*(3):369-378.
51. Diven M, Ballman K, Marciscano A, Barbieri C, Piscopo J, et al. (2024). Radiation therapy and Irreversible electroporation for intermediate risk prostate cancer (RTIRE). *BMC Urol. 24*(1):151
52. Teramoto A, Sakamaki K, Shoji S, Uemura K. (2024). Win ratio analysis of short-term clinical outcomes of focal therapy and robot-assisted radical prostatectomy for the patients with localized prostate cancer. *Sci Rep. 14*(1):17019.
53. Faiella E, Santucci D, Vertulli D, Vergantino E, Vaccarino F, et al. (2024). Irreversible Electroporation (IRE) for Prostate Cancer (PCa) Treatment: The State of the Art. *J Pers Med. 14*(2):137.
54. Schmid BP, Mariotti GC, Miranda GM, Garcia RG, Kaufmann O. (2024). Irreversible electroporation for prostate cancer: another promising focal therapy. *einstein (São Paulo).*
55. Colletini F, Enders J, Stephan C, Fischer T, Baur A D J, et al. (2019). Image-guided Irreversible Electroporation of Localized Prostate Cancer: Functional and Oncologic Outcomes. *Radiology RSNA*. Published on line.
56. Geboers B, Gondoputro W, Thompson JE, Reesink DJ, van Riel LAMJG, et al. (2022). Diagnostic Accuracy of Multiparametric Magnetic Resonance Imaging to Detect Residual Prostate Cancer Following Irreversible Electroporation-A Multicenter Validation Study. *Eur Urol Focus. 8*(6):1591-1598.