

A Case Report of Chorea-Acanthocytosis

Maryam Izadi Laybidi *, Melika Izadi Laybidi

Laybidi MI. Epilepsy Nurse, Kashani Hospital. School of Nursing, Isfahan University of Medical Sciences, Isfahan, Iran

***Corresponding Author:** Maryam Izadi Laybidi, Laybidi MI. Epilepsy Nurse, Kashani Hospital. School of Nursing, Isfahan University of Medical Sciences, Isfahan, Iran.

Received date: October 07, 2024; **Accepted date:** November 05, 2024; **Published date:** November 14, 2024

Citation: Maryam Izadi Laybidi, Melika Izadi Laybidi, (2024), A Case Report of Chorea-Acanthocytosis, *J Clinical Research and Reports*, 17(1); **DOI:**10.31579/2690-1919/418

Copyright: © 2024, Maryam Izadi Laybidi. This is an open access article distributed under the Creative Commons Attribution License, which permits unrestricted use, distribution, and reproduction in any medium, provided the original work is properly cited.

Abstract

Back ground:

Neuroacanthocytosis (NA) is a heterogeneous group of inherited neurodegenerative disorders characterized by misshapen spiculated erythrocytes and symptoms that resemble Huntington's disease. A 30-year-old, who developed hyperkinetic involuntary movements that became progressively more obvious during the course of a year.

Method: Case presentation: Here, we present one case of ChAc diagnosed based on typical clinical symptoms, MRI, genetic findings.

Conclusions: Chorea-acanthocytosis is a rare neurodegenerative disease with various early clinical manifestations. A neuropsychiatric syndrome, beginning with features of person with OCD spectrum disorder, may evolve into dementia; some patients also have axonal neuropathy and seizures. Nursing participates in improving the quality of the patient's life.

Keywords: utilisation of algal; bioremediation; polluted environment; polycyclic hydrocarbon; bioremediation of algae

Introduction

Acanthocytes are irregularly shaped red cells with spiny projections whose appearance reflects abnormal membrane structure. They are found in PKAN (see the following text) and in Huntington-like disorder 2 (HDL2), a triplet repeat disease affecting the gene encoding junctophilin-3, a protein involved in sarcoplasmic and plasma membranes. Chorea-acanthocytosis is an autosomal recessive disorder in which patients experience the onset of a hyperkinetic movement disorder in early adulthood, which eventually evolves into parkinsonism. The movements are often drug resistant but may respond to deep brain stimulation. A neuropsychiatric syndrome, beginning with features of obsessive-compulsive disorder may evolve into dementia; some patients also have an axonal neuropathy and seizures. Death usually occurs within 15 years; there is no disease-modifying therapy. Patients have mutations in CHAC, the human analog of the yeast vacuolar protein sorting 13 (VPS13). The gene product, chorein, interacts with β -adducin and β -actin, membrane cytoskeletal proteins expressed at synapses and red cell membranes. Two related disorders of lipid metabolism are also associated with acanthocytosis. Abetalipoproteinemia (Bassen-Kornzweig syndrome) is caused by mutations in the gene encoding the microsomal triglyceride transfer protein. This leads to severe diarrhea and almost complete absence of apolipoprotein B (apoB)-containing proteins in the blood, with very low levels of cholesterol (often <40 mg/dL) and other blood lipids. Fat-soluble vitamins are correspondingly low; perhaps the most

significant is vitamin E, whose deficiency causes a spinocerebellar syndrome, progressive ophthalmoplegia and pigmentary retinopathy. Vitamin K deficiency may cause serious bleeding. The presence of very low serum cholesterol and acanthocytes should suggest the diagnosis, which can be confirmed by mutation analysis. Treatment with vitamin E and vitamin K is effective if begun early. Hypobetalipoproteinemia results from mutations in the apoB gene itself; the phenotype is indistinguishable from abetalipoproteinemia; the treatment is the same.

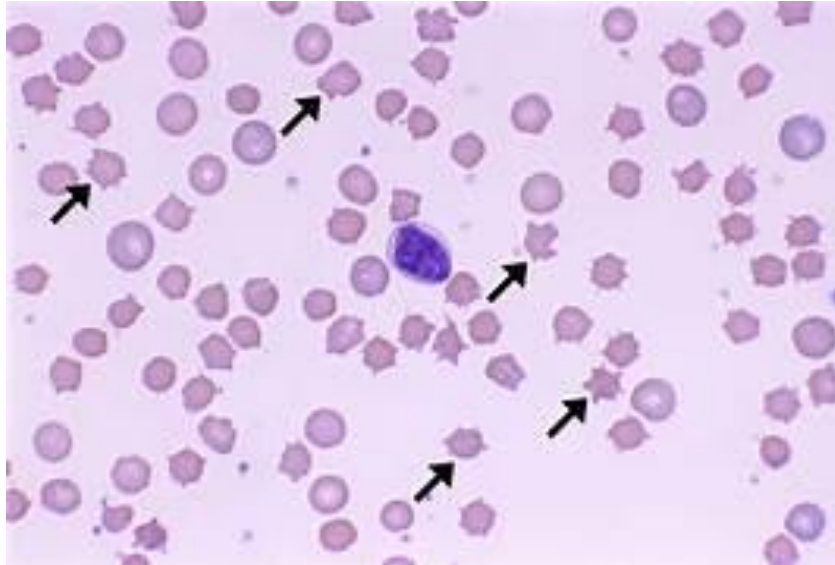
Some also have seizures. MRI shows caudate atrophy and increased signal in the putamen. Cardiomyopathy may occur and lead to premature death. Electromyography (EMG) shows axonal degeneration and muscle biopsy may show myopathy and denervation. Complex phenotypes likely result from contiguous gene syndromes; XK is adjacent to CYBB (causing X-linked chronic granulomatous disease), DMD (Duchenne muscular dystrophy), and RPGR (X-linked retinitis pigmentosa) on the X chromosome (Merritt Neurology - page 2225).

Perhaps the most common hereditary chorea after HD is neuroacanthocytosis, formerly called *chorea-acanthocytosis*. The chorea is typically less severe than that seen with HD but occasionally can be just as severe. In addition to chorea, patients with neuroacanthocytosis often have tics, stereotypies, seizures, cognitive decline, amyotrophy, dysphagia, absent tendon reflexes, high serum creatine kinase, feeding

dystonia (tongue pushes food out of the mouth), and self-mutilation with lip and tongue biting. Age at onset is typically in adolescence and young adulthood, but the range is wide (8 to 62 years). Like HD, a young age at onset is more likely to produce parkinsonism or dystonia rather than chorea. The diagnosis depends on finding more than 10% spiky erythrocytes (acanthocytes) in blood smears. Some authorities have proposed that detection of acanthocytes can be enhanced if a wet smear of blood is diluted 1:1 with normal saline (Figure. 81.2). Occasionally electron microscopy is needed to confirm the presence of acanthocytes (merritte. page694)

The cerebral pathology is similar to that of HD, with striatal degeneration causing caudate atrophy but without intranuclear inclusions

immunostaining with antibodies against huntingtin protein. PET scan typically shows hypometabolism in the caudate nucleus as well as reduced fluorodopa uptake and decreased dopamine receptor binding in the striatum. Erythrocyte membrane lipids are altered. Tightly bound palmitic acid (C16:0) is increased and stearic acid (C18:0) is decreased. Choline acetyltransferase and glutamic acid decarboxylase are normal in basal ganglia and cortex, substance P levels are low in the substantia nigra and striatum, and norepinephrine is elevated in the putamen and pallidum. A rare patient with neuroacanthocytosis may have the McLeod phenotype, an X-linked (Xp21) form of acanthocytosis associated with chorea, seizures, neuropathy, liver disease, hemolysis, and elevated creatine kinase values. (merritte. page 695)

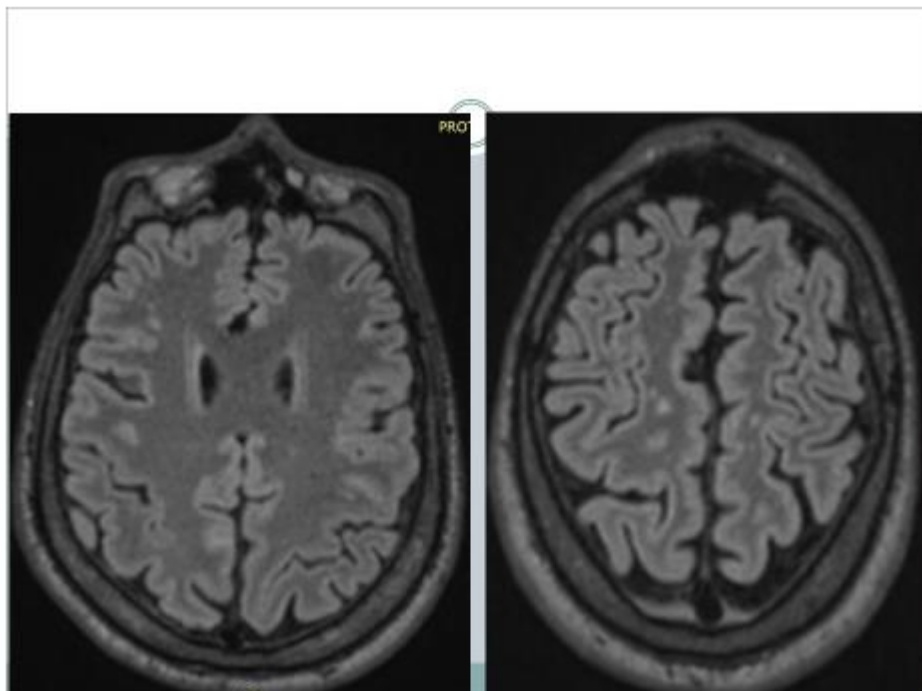
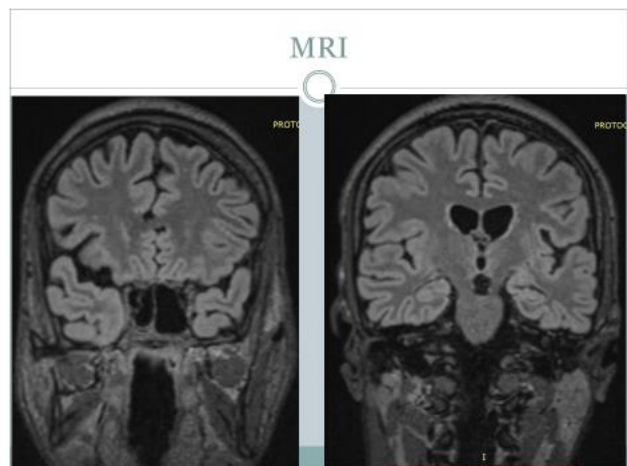
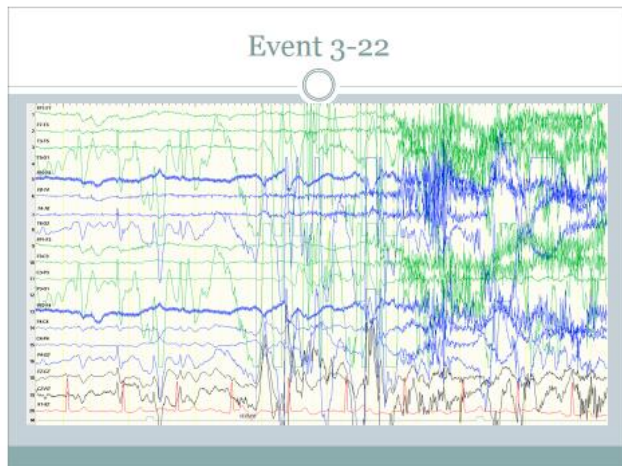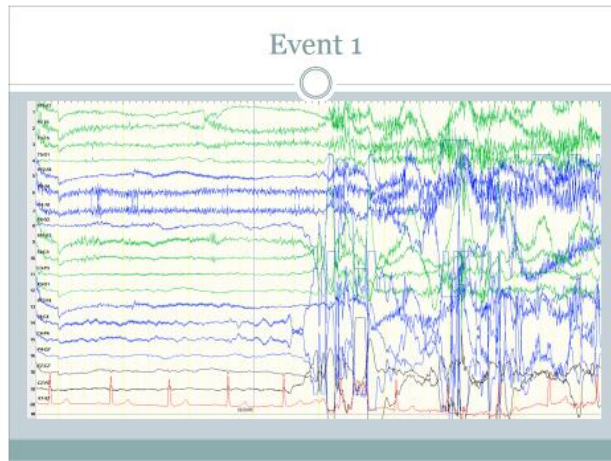


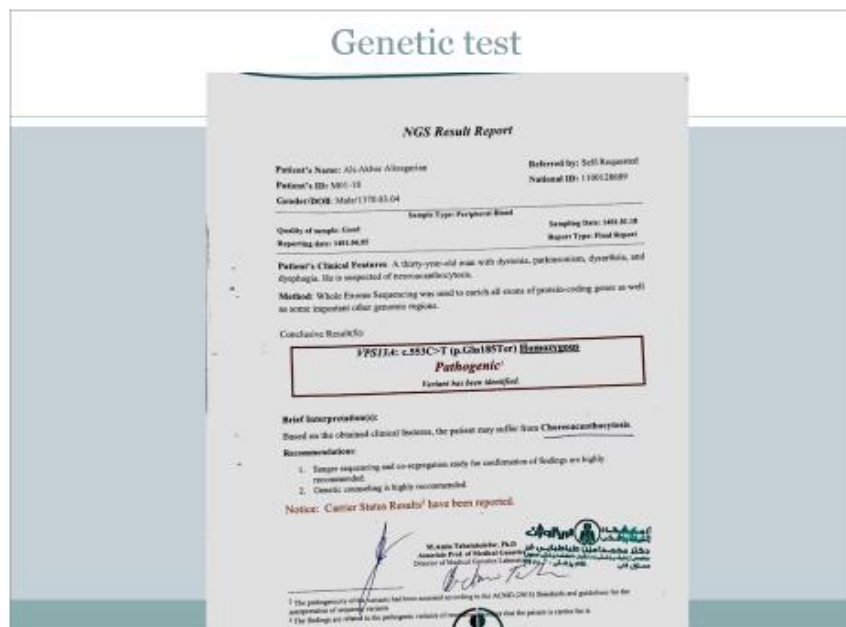
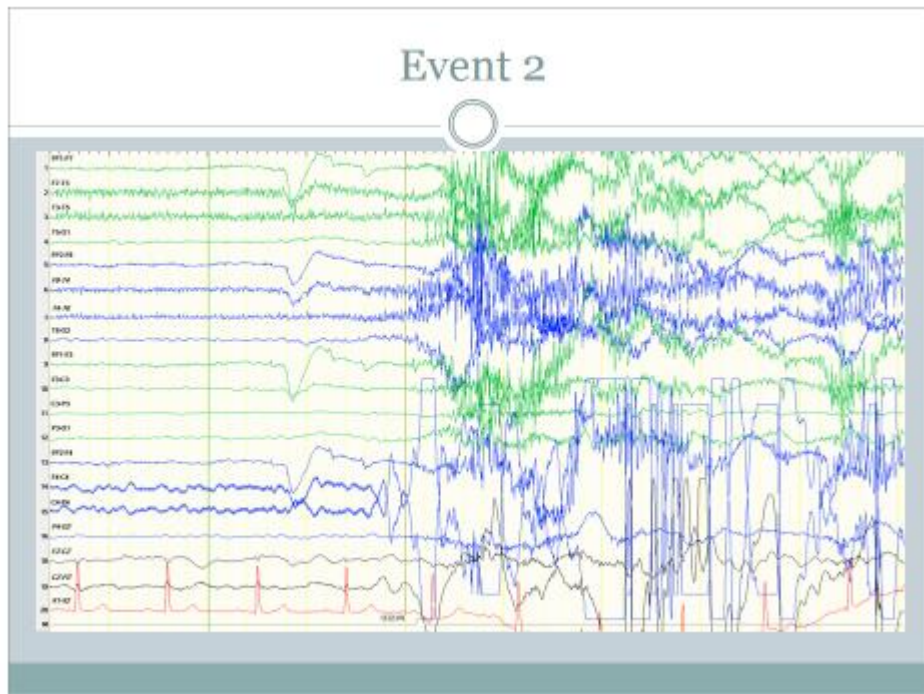Case Report

it's 30year old male patient who was brought to emu for acute seizure and lost muscle an especially prominent of lower extremity which was following that followed by loss of movement the patient was sent to 4 monitoring he was conscious and oriented he he hadn't walked and he's verbal response was incomprehensive and his motor response was poor especially in lover extremity motor exam consisted right upper limb proximal and distal 5 to 5 left upper limp proximal four to five and distal 3 to 5 write lovely proximate four to five distal 3 to 5 .plantar reflex right mute left down . And he was involuntary time movement that affected cutting and speech he initially experienced symptom in 2020 and He had the history up and anxiety restlessness and his symptoms fluctuated during recently Mount the patient hyper kinetic involuntary movement because progressive more abvious. He developed tongue protrusion,diarrhoea, dysplasia. Brain magnetic response imaging MRI showed white matter lesion of the bilateral Hemisphere. The routine blood analysis rate was normal . Akanto sitosis was shown in a peripheral blood smear. Subsequently, symptoms include tongue protrusion. Genetic testing was performed and they were found in his family, mother and sister. The patient was administered anti-epileptic drugs(1000mg level tracetam. The patient was monitored in their monitoring unit video E EG monitoring and he had abnormal erg. A habitual seizure was a focal

seizure without any URA. His second confusion was 5_10 seconds. The frequency of his seizures 20 per day. He experienced serial seizures of intricate egg finding consisting of hyper ventilation and photic didn't induce seizures and epileptic form discharge. His eEG background consisted of 10 hertz activity over the posterior head region. The patient had seizures for the first time six months ago. It was in the form of bilateral blinking and deviation of the face to the right, which lasted for about 5 seconds. He was unconscious during the attack .He is unconscious for about 5 to 10 seconds after the attack. The patient was born naturally with normal development and no history of fever and convulsions. birth injury. head trauma can infection. The parents of the patient are reletd. During the hospitalization, the patient had 21 seizures. While waking up and lying down, he first moved his hands. And then it contracts and makes an incomprehensive sound.He also lifts his left leg and then flexes it at the knee.

The patient's eyes are open, but he does not communicate. The patient has frequent blinking. After 90 seconds, he partially answers the nurse's questions. And after 120 seconds, he gives the correct answer. This case has demonstrated that ChAc can have a clinical manifestation with focal seizure with significant motor symptoms due to chAc The disease course is typically characterized by a progressive disorder and strong muscle .





Conclusion

Neuroacanthocytosis syndromes are characterized by the presence of “thorny” red blood cells and neurodegeneration of the basal ganglia, along with peripheral neuromuscular findings, seizures, and a variety of neuropsychiatric features.

Reference:

1. Alker RH, Jung HH, Dobson-Stone C, Rampoldi L, Sano A, Tison F, Danek A (2007).: Neurologic phenotypes associated with acanthocytosis. *Neurology*, 68(2):92-98.
2. Critchley EM, Clark DB, Wikler A(1968). Acanthocytosis and neurological disorder without betalipoproteinemia. *ArchNeurol*, 18(2):134-140.
3. Levine IM, Estes JW, Looney JM: (1968).Hereditary neurological disease with acanthocytosis. A new syndrome. *ArchNeurol*, 19(4):403-409.
4. Allen FH, Krabbe SMR, Corcoran PA(1961). A new phenotype (McLeod) in the Kell blood-group system. *Vox Sang*, 6:555-560.
5. Marsh WL, Taswell HF, Oyen R, Nichols ME, Vergara MS, Pineda A(1975). Kx antigen of the Kell system and its relationship to chronic granulomatous disease. Evidence the Kx gene is X-linked. *Transfusion*, 15:527.
6. Marsh WL, Marsh NJ, Moore A, Symmans WA, Johnson CL, Redman CM: (1981).Elevated serum creatine phosphokinase in subjects with McLeod syndrome. *Vox Sang*, 40(6):403-411.
7. Schwartz SA, Marsh WL, Symmans A, Johnson CL, Mueller KA(1982). New clinical features of McLeod syndrome. *Transfusion*, 22:404.

8. Hardie RJ, Pullon HW, Harding AE, Owen JS, Pires M, Daniels GL, Imai Y, Misra VP, King RH, Jacobs JM: (1991). Neuroacanthocytosis. A clinical, haematological and pathological study of 19 cases. *Brain*, 114(Pt 1A):13-49.
9. Rampoldi L, Dobson-Stone C, Rubio JP, Danek A, Chalmers RM, Wood NW, Verellen C, Ferrer X, Malandrini A, Fabrizi GM, et al: (2001). A conserved sorting-associated protein is mutant in chorea-acanthocytosis. *NatGenet*, 28(2):119-120.
10. Ueno S, Maruki Y, Nakamura M, Tomemori Y, Kamae K, Tanabe H, Yamashita Y, Matsuda S, Kaneko S, Sano A (2001). The gene encoding a newly discovered protein, chorein, is mutated in chorea-acanthocytosis. *Nat Genet*, 28(2):121-122.
11. Ho M, Chelly J, Carter N, Danek A, Crocker P, Monaco AP, (1994). Isolation of the gene for McLeod syndrome that encodes a novel membrane transport protein. *Cell*, 77(6):869-880. *Merritt's Neurology* FOURTEENTH EDITION



This work is licensed under Creative Commons Attribution 4.0 License

To Submit Your Article Click Here: [Submit Manuscript](#)

DOI: [10.31579/2690-1919/415](https://doi.org/10.31579/2690-1919/415)

Ready to submit your research? Choose Auctores and benefit from:

- fast, convenient online submission
- rigorous peer review by experienced research in your field
- rapid publication on acceptance
- authors retain copyrights
- unique DOI for all articles
- immediate, unrestricted online access

At Auctores, research is always in progress.

Learn more <https://www.auctoresonline.org/journals/journal-of-clinical-research-and-reports>