

# Attempted Clandestine Abortion: The Dangers of Alternative Methods

Khaoula LAKHDAR<sup>1\*</sup>, Oumaima SARHDAOUI<sup>1</sup>, Amani GHAZALAH<sup>1</sup>, Fatima Zahra BELOUEZA<sup>1</sup>, Soukaina MOUIMAN<sup>1</sup>, Aziz SLAOUI<sup>1</sup>, Amina LAKHDAR<sup>1</sup>, Aziz BAYDADA<sup>1</sup>

Gynecology-Obstetrics and Endoscopy Department, Maternity Souissi, University Hospital Center IBN SINA, University Mohammed V, Rabat, Morocco

**\*Corresponding Author:** Khaoula Lakhdar, Gynecology-Obstetrics and Endoscopy Department, Maternity Souissi, University Hospital Center IBN SINA, University Mohammed V, Rabat, Morocco.

**Received date:** July 08, 2024; **Accepted date:** July 26, 2024; **Published date:** August 12, 2024

**Citation:** Khaoula Lakhdar, Noreen. E. Agbapuonwu, Chika. C. H. Odira, (2024), Attempted Clandestine Abortion: The Dangers of Alternative Methods, *J. Women Health Care and Issues*, 7(6); DOI: [10.31579/2642-9756/217](https://doi.org/10.31579/2642-9756/217)

**Copyright:** © 2024, Khaoula lakhdar. This is an open access article distributed under the Creative Commons Attribution License, which permits unrestricted use, distribution, and reproduction in any medium, provided the original work is properly cited.

## Abstract

Clandestine abortions represent a major public health challenge, particularly in low- and middle-income countries. Although maternal mortality related to these practices has greatly decreased in developed countries, it remains a significant concern in regions where abortion is only permitted to protect the mother's health or life. We describe the case of a 24-year-old patient admitted for pelvic pain with metrorrhagia in the context of attempted clandestine abortion by intravaginal introduction of potassium permanganate. Despite emergency care, the patient presented with necrotic vaginal lesions, underscoring the potentially lethal dangers of these alternative methods. Prevention through sexuality education and improved contraceptive access remains the best solution to reduce unsafe abortions.

**Keywords:** potassium permanganate; clandestine abortion; necrotic lesion; maternal mortality; unsafe abortion

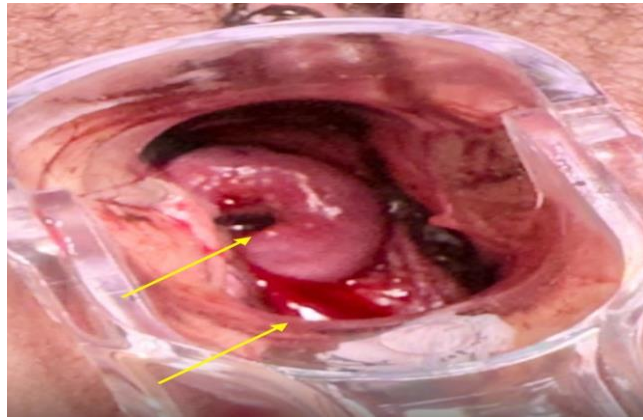
## Introduction

Unsafe abortion remains a major global public health concern, disproportionately impacting women in low- and middle-income countries (1). In regions where abortion is highly restricted, women often resort to barbaric methods, exposing themselves to life-threatening complications. While maternal mortality from unsafe abortion has significantly decreased in developed nations, it continues to be a leading cause of maternal death in developing countries (1). These dangerous procedures account for up to 13% of all maternal deaths worldwide, making them a leading cause of preventable maternal mortality (1,2). While advancements intensive care has drastically reduced abortion-related mortality in high-income nations, women in low-resource settings continue to face life-threatening complications from unsafe practices.

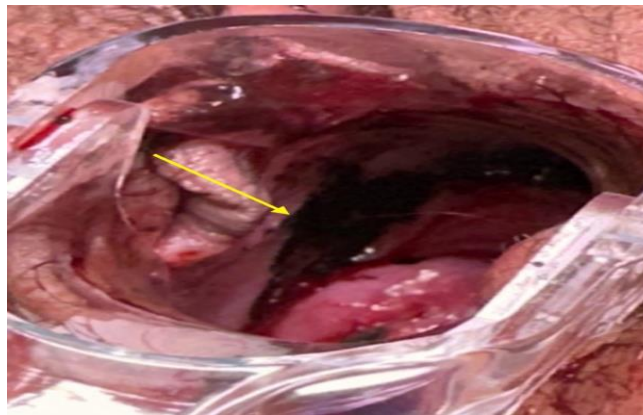
We present the case of a 24-year-old patient admitted for pelvic pain and metrorrhagia following an attempted clandestine abortion using intravaginal potassium permanganate. Despite prompt emergency management, the patient developed severe necrotic vaginal lesions, underscoring the devastating consequences of these dangerous methods. Potassium permanganate, historically used to induce abortion, can cause extensive tissue damage, hemorrhage, and even intestinal obstruction (3,4).

## Case presentation

we present the case of a young 24-year-old nulliparous patient with no medical antecedents who consulted our department's gynecological and obstetric emergency department for moderate metrorrhagia associated with cramp-like pelvic pain with no particular irradiation in the context of an 8-week ammenhorea. Clinical examination revealed a conscious patient with tachycardia at 110 beats per minute and blood pressure at 99/60 mmHg. the patient was rushed to hospital, conditioned with two good-calibre venous lines, oxygen therapy and analgesics, and a biological work-up was undertaken, with a request for blood from the reserve, as well as administering a crystalloid infusion. Transabdominal ultrasound showed an intrauterine pregnancy at 8 weeks of gestation with trophoblastic detachment. the gynecological examination was carried out in the operating room under sedation and antibiotic cover, after the valves had been placed, a saline lavage was carried out with the same antiseptic aim of clearing blood and debris, a closed cervix was seen, carbonized ulcerations on the uterine cervix and lateral vaginal walls at 11 h of the uterine cervix, no sutures were taken as the bleeding had stopped. The patient remained hospitalized for 3 days in our department, under antibiotic and antiseptic treatment, with application of hyaluronic acid-based cream. The patient was connected to the prenatal consultation circuit in our structure for pathological pregnancy monitoring. Psychological support was administered to the patient via our maternity unit's psychological unit.



**Figure 1:** Image showing carbonized lesion on the cervix



**Figure 2:** Ulcerated carbonized lesion on the upper part of the lateral vaginal

## Discussion

The case presented highlights the severe that can arise from attempted clandestine abortions, a persisting global health issue, particularly in resource-limited settings [1]. Unsafe abortion practices, such as the intravaginal instation of potassium permanganate used by this patient, can lead to devastating consequences including hemorrhage, tissue necrosis, and even death [5,6]. Globally, unsafe abortion remains a major public health concern, with an estimated 55 million unsafe abortions occurring annually, the vast majority (97%) taking place in developing countries (1). These dangerous procedures account for up to 13% of all maternal deaths worldwide, making them a leading cause of preventable maternal mortality (2). While advancements intensive care has drastically reduced abortion-related mortality in high income nations, women in low-resource settings continue to face life-threatening complications from unsafe practices (4,5).

Potassium permanganate, historically employed as an abortifacient, can cause extensive chemical burns and tissue destruction when applied intravaginally (6,7). This corrosive substance, used by our patient, may also lead to intestinal obstruction and pelvic peritonitis beyond the initial hemorrhagic risk (6,8). The severe necrotic vaginal lesions observed in our case underscore the life-threatening nature of these unsafe abortion methods. The pathophysiology of the complications associated with potassium permanganate-induced clandestine abortions is multifaceted. As a strong oxidizing agent, potassium permanganate can induce coagulative necrosis of the vaginal and cervical mucosa upon contact (6,7). This can lead to extensive tissue damage, bleeding, and increased susceptibility to infection. Furthermore, the corrosive properties of the substance may cause direct

injury to the surrounding pelvic organs, increasing the risk of complications such intestinal obstruction and perforation (6,8).

In addition to the immediate physical consequences, clandestine abortions can also have long-term sequelae, both medical and psychological. Untreated genital tract injuries and infections may result in chronic pelvic pain, menstrual disorders, and infertility (9,10). The trauma and social stigma associated with unsafe abortion can also have a significant impact on the patient's mental health, leading to conditions such as depression, anxiety, and post-traumatic stress disorder (11,12).

Comprehensive emergency management, as demonstrated in this case, is crucial to address the acute complications of clandestine abortion. This includes prompt hemodynamic stabilization, antibiotic coverage, surgical exploration, and targeted local treatment (13,14). Resuscitative measures, such as intravenous fluid administration and blood transfusion, are essential to address the life-threatening hemorrhage that can occur (15,16). Surgical intervention, including dilation and curettage or hysterectomy in severe cases, may be necessary to control bleeding and remove necrotic tissue (17,18). In the case presented, the patient underwent a thorough gynecological examination under sedation and antibiotic cover, with saline irrigation to clear blood and debris. This revealed the presence of a closed cervix and extensive carbonized ulcerations on the uterine cervix and lateral vaginal walls, highlighting the severity of the tissue damage (6,7). Fortunately, no sutures were required as the bleeding had stopped, indicating the effectiveness of the initial hemostatic measures. The long-term consequences, both physical and psychological, emphasize the need for a multidisciplinary approach to the management of clandestine abortion

complications. Integrating the patient into a high-risk pregnancy care circuit, done in this case, is crucial to monitor the progress of the pregnancy and address any ongoing complications (19,20). Additionally, the provision of psychological support through the maternity unit's mental health unit is essential to address the trauma and distress experienced by the patient (11,12).

From a global perspective, the World Health Organization (WHO) has emphasized the importance of addressing unsafe abortion as a critical component of maternal initiatives. The organization has developed evidence-based guidelines for the prevention and management of unsafe abortion, highlighting the need for a multi-pronged approach (24,25). This includes expanding access to modern contraception, providing comprehensive sexuality education, and ensuring the availability of safe, legal abortion services, particularly in resource-limited settings (24,25).

Addressing these systemic challenges requires a concerted effort from policymakers, healthcare providers, and community stakeholders to create an enabling environment for reproductive health and rights. Additionally, integrating post-abortion care services, as contraceptive counseling and mental health support, can help address the long-term needs of women who have one unsafe procedure (19,20). The case presented underscores the importance of healthcare providers being vigilant and prepared to manage the complex medical and psychological needs of patients who have attempted clandestine abortions. Familiarity with the potential complications, appropriate emergency response protocols, and a multidisciplinary approach to care are essential to optimize patient outcomes (13,14,19,20). In conclusion, the case of the young patient who developed severe vaginal necrosis following an attempted clandestine abortion using potassium permanganate highlights the urgent need to address the global burden of unsafe abortion. Comprehensive strategies that prioritize prevention through improved access to sexuality education, family planning, and safe, legal abortion services, coupled with strengthened emergency obstetric care and integrated post-abortion support, are crucial to reducing the morbidity and mortality associated with this persistent public health challenge.

## Conclusions

The prevention of unsafe abortions remains the most effective strategy to address this persistent global health disparity. Improving access to comprehensive sexuality education, family planning services, and safe, legal abortion care are essential public health interventions. Addressing the sociocultural and legal barriers that drive women to resort to clandestine methods is also crucial to reduce the burden of unsafe abortion and its associated morbidity and mortality.

## Declarations

### Ethical approval

Ethics approval has been obtained to proceed with the current study.

### Funding

There are no funding sources to be declared.

### Author contribution

Khaoula LAKHDAR: study concept and design, data collection, data analysis and interpretation, writing the paper. Oumaima SARHDAOUI: study concept and design, data collection, data analysis and interpretation, writing the paper. Amani GHAZALAH: study concept and design, data

collection, data analysis and interpretation, writing the paper. Fatima Zahra BELOUEZA: study design, data collection, data interpretation, writing the paper. Soukaina MOUIMAN: study concept and design, data collection, data analysis and interpretation, writing the paper. Aziz Slaoui study concept and design, data collection, data analysis and interpretation, writing the paper. Amina LAKHDAR: study concept and design, data collection, data analysis and interpretation, writing the paper. Aziz BAYDADA: study concept, data collection, data analysis, writing the paper.

## Guarantor

The corresponding author is the guarantor of submission.

## References

- World Health Organization.
  - Preventing unsafe abortion. 2020.
- Say L, Chou D, Gem A, et al.
  - Global causes of maternal death: a WHO systematic analysis.
  - Lancet Glob Health. 2014;2(6): p323-p333.
- Grimes DA. Unsafe abortion (2003). the silent scourge. Brd Bull.;67:99-113
- Darj E, Infanti JJ. (2009). An unsafe abortion case report from Botswana. Cases J.; 2:7530.
- Say L, Chou D, Gemmill A, et al. (2014). Global causes of maternal death: a WHO systematic analysis. Lancet Glob Health.;26): e323-e333.
- Grimes DA. Unsafe abortion. (2003). the silent scourge. Br Med Bull.;67:99-113.
- Darj E, Infanti JJ. (2009). An unsafe abortion case report from Botswana. Cases J.; 2:7530.
- Adler AJ, Filippi V, Thomas SL, Ronsmans C. (2012). Quantifying the global burden of morbidity due to unsafe abortion: magnitude in hospital-based studies and methodological issues. Int J Gynaecol Obstet.;118 Suppl 2: S65-S77.
- Acharya R, Kalyanwala S. (2012). Knowledge, attitudes and practices of certified providers of medical abortion: evidence from Bihar and Maharashtra, India. Int J Gynaecol Obstet.;118 Suppl 1: S40-S46.
- Benson J, Andersen K, Healy J, Brahmi D. (2017). What factors contribute to postabortion care patients seeking re-treatment? A systematic review. PLoS One.;12(10):e017551.
- Shellenberg KM, Hessini L, Levandowski BA. (2014). Developing a scale to measure stigmatizing attitudes and beliefs about women who have abortions: results from Ghana and Zambia. Womens Health Issues.;24(6): e291-e299.
- Bradshaw Z, Slade P. (2003). The effects of induced abortion on experiences and relationships: a critical review of the literature. Clin Psychol Rev.;23(7):929-958.
- Gülezoglu AM, Forma F, Villar J, Hofmeyr GJ. (2007). Prostaglandins for preventing postpartum haemorrhage. Cochrane Database Syst Rev.;(3):CD000494.
- World Health Organization. (2012). WHO recommendations for the prevention and treatment of postpartum haemorrhage. Geneva: WHO; 2012.
- Penny-MacGillivray T. (1993). A hemorrhagic shock experience. Nurs Clin North Am.;28(1):1-14.

16. Carlin AJ, Alfirevic Z, Gyte GM. (2010). Interventions for treating postpartum haemorrhage. *Cochrane Database Syst Rev.*;(9):CD006431.
17. Naguib AH, Morsi HM, Borg TF, SorourG, El-Kady NM. (2012). Genital tract injuries following criminal abortion attempt. *Int J Gynaecol Obstet.*;119(1):72-74.
18. Ordi J, Pepín L, Cusidó M, et al. (2009). Clinicopathological features of genital tract injuries secondary to difficult abortion procedures. *J Clin Pathol.*;62():686689.
19. Harries J, Orner P, Gabriel M, Mitchell E. (2007). Delays seeking an abortion until the second trimester: a qualitative study in South Africa. *Reprod Health.*;4:7.
20. Gerds C, Vohra D, Ahern J. (2013). Measuring unsafe abortion-related mortality: a systematic review of the existing methods. *PLoS One.*;8(1): e53346.
21. Sedgh G, Bearak J, Singh S, et al. (2016). Abortion incidence between 1990 and 2014: global, regional, and subregional and trends. *Lancet.*;388(10041):258-267.
22. Briozzo L, Rodríguez F, León I, Vidiella G, Ferreiro G, Pons JE. (2002). Unsafe abortion in Uruguay. *Int J Gynaecol Obstet.*;79(2):185-188.
23. Ganatra B, Gerds C, Rossier C, et al. (2017). Global, regional, and subregional classification of abortions by safety, 2-14: estimates from a Bayesian hierarchical model. *Lancet.*;390(10110):2372-2381.
24. World Health Organization. Safe abortion: technical and policy guidance for health systems. 2nd ed. *Geneva: WHO; 2012.*
25. World Health Organization. Health worker roles in providing safe abortion care and post-abortion contraception. *Geneva: WHO; 2015.*



This work is licensed under Creative Commons Attribution 4.0 License

To Submit Your Article Click Here:

**Submit Manuscript**

DOI: [10.31579/2642-9756/217](https://doi.org/10.31579/2642-9756/217)

**Ready to submit your research? Choose Auctores and benefit from:**

- fast, convenient online submission
- rigorous peer review by experienced research in your field
- rapid publication on acceptance
- authors retain copyrights
- unique DOI for all articles
- immediate, unrestricted online access

At Auctores, research is always in progress.

Learn more <https://www.auctoresonline.org/journals/women-health-care-and-issues>