

Role of Haemoglobin Spray in Wound Bed Preparation

Sushil Nepali ¹, Ravi Kumar Chittoria ^{2*}, Jacob Antony Chakiath ³, Kanav Gupta ³

¹Junior Resident, Department of General Surgery, JIPMER, Puducherry, India.

²Professor & Registrar (Academic) Head of IT Wing and Telemedicine, Department of Plastic Surgery & Telemedicine, JIPMER, Pondicherry, India.

³General Surgery, Senior Resident, Department of Plastic Surgery, JIPMER, Puducherry, India.

***Corresponding Author:** Ravi Kumar Chittoria, Senior Professor and Associate Dean (Academic), Head of IT Wing and Telemedicine Department of Plastic Surgery and Telemedicine, JIPMER, India.

Received date: May 02, 2024; **Accepted date:** May 20, 2024; **Published date:** June 17, 2024

Citation: Sushil Nepali, Ravi K. Chittoria, Jacob A. Chakiath, Kanav Gupta, (2024), Role of Haemoglobin Spray in Wound Bed Preparation, *J Clinical Case Reports and Studies*, 5(4); DOI:10.31579/2690-8808/197

Copyright: ©, 2024, Ravi Kumar Chittoria. This is an open access article distributed under the Creative Commons Attribution License, which permits unrestricted use, distribution, and reproduction in any medium, provided the original work is properly cited.

Abstract

Wound is a common problem following burn, trauma or infection. There are various methods to limit the infection and to cover the raw area. Before definitive cover, the wound bed must be ready to accept the reconstructive procedure. Various methods help in wound bed preparation. Recently haemoglobin spray has been advocated to hasten the wound bed preparation. In this article, we share our experience of using innovative haemoglobin spray in wound bed preparation.

Key Words: haemoglobin spray, wound healing, hyperbaric oxygen (HBO) therapy

Introduction

Wound is a common problem encountered by plastic surgeons. The wound that fails to heal in three weeks is considered as a chronic wound. Various factors may lead to chronic or non-healing wounds. Diabetes mellitus is among the most important cause that may result in a non-healing ulcer, especially in lower limbs. Many methods do exist which are claimed to hasten the healing with varying success. Poor oxygenation of tissue is a factor that leads to poor wound healing. Recently haemoglobin spray has been claimed to accelerate wound healing by delivering oxygen to wound bed. In the review of the literature, we have seen very few Indian studies on haemoglobin spray in wound management. We share our experience of using innovative haemoglobin spray in wound management.

Materials and Methods:

This is a case report of the use of innovative haemoglobin spray in an electrical burn wound. This study was conducted in a JIPMER, tertiary care hospital in 2024, a case of 8 years old male child with electrical burns (35%).

Informed written consent was taken from the patient. The patient had a raw area over the scalp following the electrical burn. The patient was thoroughly investigated. Wound tissue culture was sent and appropriate antibiotic therapy was given. Regular cleaning and dressings were done for two weeks but the wound failed to show any healthy granulation tissue. To promote the healing, decision was made to give trial therapy of innovative haemoglobin spray therapy.

Under all aseptic precautions, 2.7ml of blood was harvested from the antecubital vein. It was mixed with 0.3ml of 3.8% sodium citrate solution (Na-citrate to blood ratio=1:9) to prevent coagulation. The blood was transferred to a glass vial and a cap with the spray and nozzle mechanism was placed on it. The blood was sprayed uniformly on the wound and a sterile dressing was applied. The spray was given every time the dressing was changed (twice a week). The wound was assessed weekly by clinical examination. Six such sprays were given over three weeks period.

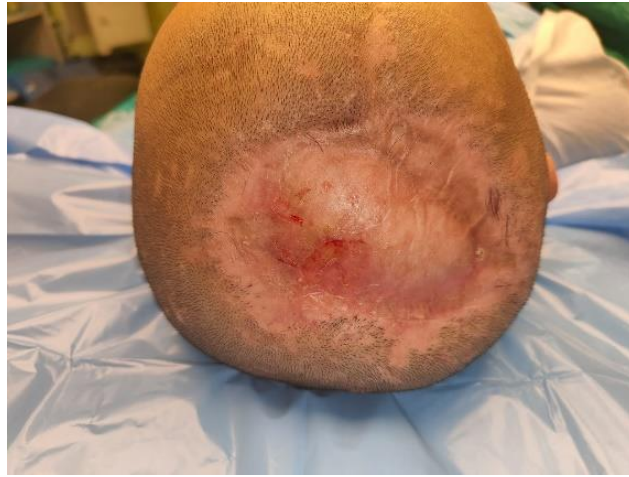

Figure 1: showing condition of raw area electrical burn at the time of presentation

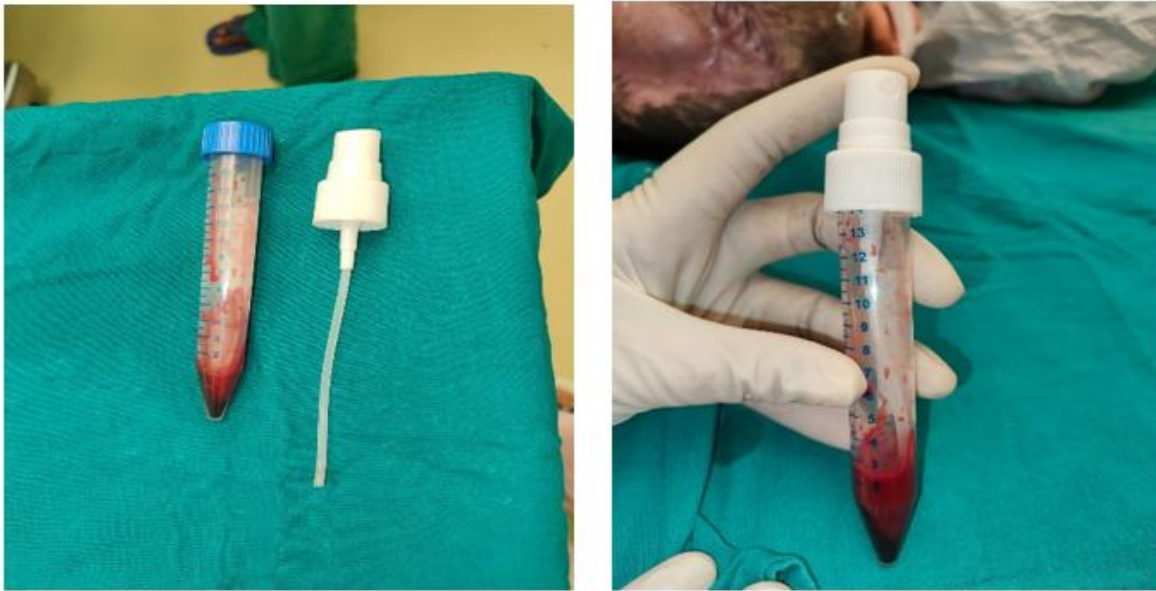


Figure 2 showing the preparation of Haemoglobin spray

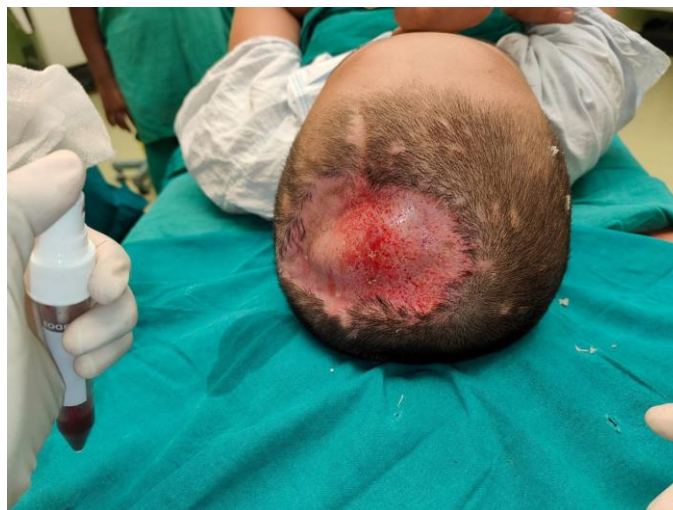

Figure 3: showing application of haemoglobin spray over the raw area.

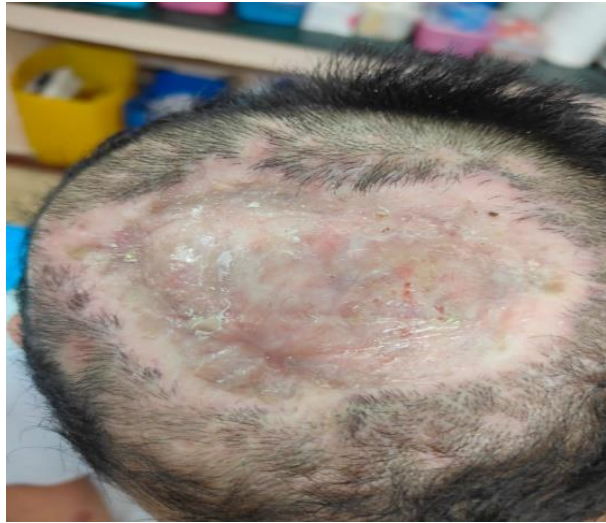

Figure 4: showing the result of the application of haemoglobin spray

Results

With regular application of haemoglobin spray, the wound starts granulating and size also decreased. The wound area was measured using digital planimetry. Before the application of haemoglobin spray, it was 5.7 cm². After three weeks, no ulcer is noted. The wound also developed red healthy granulation tissue.

Discussion

Oxygen is vital to wound healing. Temporary hypoxia stimulates wound healing while chronic hypoxia leads to a non-healing wound. The rate, at which all normal wounds heal, is shown to be oxygen-dependent. Fibroblast replication, collagen deposition, angiogenesis, resistance to infection, and intracellular leukocyte bacterial killing are oxygen-sensitive responses essential to normal wound healing. [1,2] Evidence suggests that intermittent oxygenation of wound bed starts a cascade of events that leads to wound healing. Increased tissue oxygen level leads to an increase in reactive oxygen and nitrogen species. This leads to enhanced neovascularization by increased levels of VEGF, TGF-beta, angiopoietin, etc. There is increased ECM formation due to raised FGF expression and increase rate of collagen synthesis. It also reduces inflammation by decreasing oedema, decreasing pro-inflammatory cytokines etc. [3,4] The most widely utilized modality to increase the local tissue oxygen level is hyperbaric oxygen (HBO) therapy. Hyperbaric oxygen therapy was first used in the field of wound care in the 1960s following the discovery that patients with burns who received treatment for carbon monoxide poisoning healed more quickly. More recently the role of topical oxygen therapy, without the need for full-body hyperbaric chambers, has come into existence. However, not all patients can tolerate or have access to the HBO chamber. Granulox™ is a commercially available product from In First Ltd, UK, which is designed to be more straightforward to deliver oxygen to tissue than HBO. The product, Granulox™, contains porcine haemoglobin contained in a spray canister. It is applied twice weekly to a DFU wound during redressing, and can be used

in a clinic or patient's home setting. When Granulox is sprayed, haemoglobin binds to atmospheric oxygen. Once saturated with oxygen, the haemoglobin becomes oxy-haemoglobin (HbO₂), which diffuses to the base of the wound, and increases the oxygen supply to the cells by diffusion. We have used our innovative way of using the patient's blood for spraying oxygen by using a simple glass vial and a cap with a nozzle and spray mechanism.

Conclusion

In this study, we found that haemoglobin spray has a role in wound bed preparation. The wound shows granulation at a faster rate. But since it is a single case study, a definite conclusion cannot be made. Large randomized control trials are required to confirm the efficacy of haemoglobin spray in wound bed preparation.

References:

1. Woo K, Ayello EA, Sibbald RG. (2007). The edge effect: current therapeutic options to advance the wound edge. *Adv Skin Wound Care*. 20:99–117
2. Hopf H.W., Gibson J.J. and Angeles A.P. (2015). Hyperoxia and angiogenesis. *Wound Rep Regen*. 13(6):558–564.
3. Lam, G., Fontaine, R., Ross, F. L., and Chiu, E. S. (2017). Hyperbaric Oxygen Therapy. *Advances in Skin & Wound Care*, 30(4), 181–190.
4. Thom SR. (2011). Hyperbaric oxygen: its mechanisms and efficacy. *Plast Reconstr Surg*; 127 Suppl 1(Suppl 1):131S– 141S.
5. Oxygen wound therapy: The clinical and cost impact of using topical haemoglobin spray (Granulox%). London: Wounds UK. (2017).



This work is licensed under Creative Commons Attribution 4.0 License

To Submit Your Article Click Here: [Submit Manuscript](#)

DOI:10.31579/2690-8808/197

Ready to submit your research? Choose Auctores and benefit from:

- fast, convenient online submission
- rigorous peer review by experienced research in your field
- rapid publication on acceptance
- authors retain copyrights
- unique DOI for all articles
- immediate, unrestricted online access

At Auctores, research is always in progress.

Learn more <https://auctoresonline.org/journals/journal-of-clinical-case-reports-and-studies>