

# Pediatric Cholelithiasis Single Center Experience Results of the Clinic for Pediatric Surgery kcu Sarajevo in Period 2010.-2022

N. Džih, K. Karavdić \*

Clinic for Pediatric Surgery, Clinical University Center Sarajevo, Bosnia and Herzegovina.

**\*Corresponding Author:** K. Karavdić, Clinic for Pediatric Surgery, Clinical University Center Sarajevo, Bosnia and Herzegovina.

**Received Date:** 22 May 2023 | **Accepted Date:** 30 May 2023 | **Published Date:** 07 June 2023

**Citation:** N. Džih, K. Karavdić, (2023), Pediatric Cholelithiasis Single Center Experience Results of the Clinic for Pediatric Surgery kcu Sarajevo in Period 2010.-2022. *Journal of Clinical Surgery and Research*, 4(3); DOI:10.31579/2768-2757/081

**Copyright:** © 2023, K. Karavdić. This is an open access article distributed under the Creative Commons Attribution License, which permits unrestricted use, distribution, and reproduction in any medium, provided the original work is properly cited.

## Abstract:

**Introduction.** Cholelithiasis is occurrence of one or several gallstones in the gallbladder. It can be complicated with choledocholithiasis, acute or chronic cholecystitis, cholangitis, biliary pancreatitis, biliary ileus, etc. Causes for this disorder in pediatric population can be hemolytic (hereditary spherocytosis, thalassemia, sickle cell anemia) or non hemolytic - other hereditary disorders as cystic fibrosis, Wilson's disease or ileum disorders, total parenteral nutrition, usage of certain medicaments, choledochal cysts, organ transplantation and, in adolescence, those similar to adult patients (obesity). Mostly gallstones found in children are cholesterol ones or pigmented gallstones. There are many diagnostic imaging methods for objectifying gallstones and its complications (as choledocholithiasis that requires ERCP). There is also some differential diagnoses that should be taken in consideration before the treatment (biliary dyskinesia, Oddi sphincter dysfunction, neonatal jaundice, cholestasis, pediatric cholecystitis, pediatric pancreatitis and pancreatic pseudocysts as well as pediatric pyelonephritis). First line of treatment of cholelithiasis is with diet, saline infusions and medicaments and if cholelithiasis is symptomatic and/or complicated then cholecystectomy is recommended. Having in mind operative approach it can be open procedure or laparoscopic one. Some studies show that injuries of bile ducts are more common in laparoscopic treatment of pediatric cholelithiasis but nevertheless it is shown that with experienced team and good preparation this is the golden standard in the treatment of pediatric cholelithiasis.

**Objectives.** Hereby we present a comprehensive review of literature for the clinical presentation, pathophysiology, diagnostic evaluation, and management of cholelithiasis in pediatric population.

**Methods.** Between 2010. and 2022, retrospectively, we explored data points of children who underwent laparoscopic cholecystectomy reviewed with included demographics properties, indication for cholecystectomy, used surgical technique, operative time, complications, and length of hospital stay. We performed 37 laparoscopic cholecystectomies (due to cholelithiasis and one case of cholecystitis without calculi) with 2 conversions to open procedures and via open approach we treated 3 cholelithiasis in this period. Male to female distribution was: 12 male patients and 25 female patients

**Results.** Thirty-seven children (12 male patients and 25 female patients with ages ranging from 7 to 18 years, mean: 11,9 years) underwent laparoscopic cholecystectomy. The indication for surgery was associated to symptomatic cholelithiasis in almost all patients. The surgery was performed under general anesthesia and classical 4-port approach was done in twenty-two patients, and 2-port approach in combination with 2 portless 2.3-mm percutaneous graspers was used in two patients. The operating time ranged between 45 and 120 minutes (mean: 77 minutes). Two patients were treated by open surgery. Only one patient had leakage due to choledocholithiasis, and open surgery and ERCP had to be performed. Median of hospital stay for all patients was 3-4 days.

**Conclusion.** Laparoscopic cholecystectomy is safe and effective in children, and shows the same advantages reported in adult series.

**keywords:** cholelithiasis; cholecystitis; choledocholithiasis; gallstones; laparoscopic treatment of cholelithiasis; pediatric cholelithiasis; adolescence; hemolytic

## Introduction

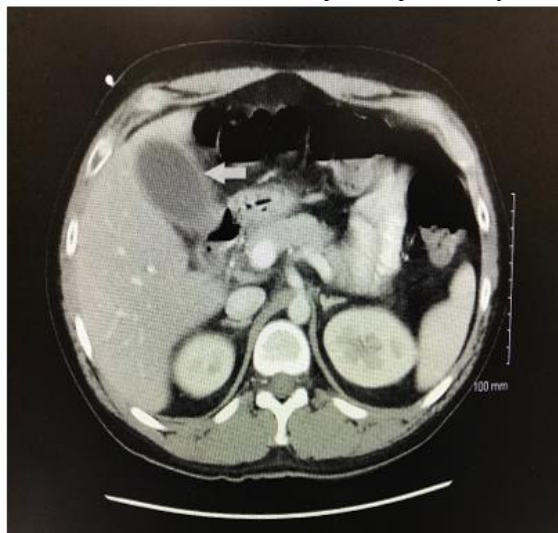Cholelithiasis is existence of one or several gallstones in gallbladder or bile ducts [1]. Cholecystitis refers to inflammation of the gallbladder. This disease is much more common within adult population, but due to obesity in adolescence and survival of neonates with short bowel syndrome (due to necrotizing colitis) or need for total parenteral nutrition or some hereditary conditions as spherocytosis, gallstones can also be formed within pediatric population [2, 3,]. Cholelithiasis is occurrence of one or several gallstones in the gallbladder. It can be complicated with choledocholithiasis, acute or chronic cholecystitis, cholangitis, biliary pancreatitis, biliary ileus, etc. Causes for this disorder in pediatric population can be hemolytic (hereditary spherocytosis, thalassemia, sickle cell anemia) or non hemolytic - other hereditary disorders as cystic fibrosis, Wilson's disease or ileum disorders, total parenteral nutrition, usage of certain medicaments, choledochal cysts, organ transplantation and, in adolescence, those similar to adult patients (obesity). The pathogenesis of cholelithiasis is similar in adult and pediatric populations. There are two main types of gallstones: cholesterol gallstones and pigmented ones [4]. Causes of cholelithiasis within pediatric population are mostly connected to preexisting conditions as can be divided in: hemolytic, nonhemolytic and idiopathic [5]. 20-40% of the children with cholelithiasis have some kind of hemolytic disease: hereditary spherocytosis, sickle cell anemia and thalassemia are the most common ones and are considered to be the biggest risk factor in the development of symptomatic cholelithiasis in pediatric population [6]. Obesity It is considered that increase of the obesity is one of the main reasons for the increase of cholelithiasis in pediatric population. Obesity as well as sudden weight loss leads to increased bilious secretion of bilirubin [7]. Infants and children younger than 5 years usually have nonspecific symptoms due to the lack of possibility of describing their discomfort [8]. Children aged 2-14 years most often have common bilious colic (50%) or nonspecific abdominal symptoms (25%), nonspecific pain and nausea. Acute abdominal pain due to cholecystitis, cholangitis and pancreatitis is rare in this age group (5-10%) and 20% of those are asymptomatic [9]. Adolescents (14-18 years) have typical bilious colic as adults. Intolerance of fatty food that is typical symptom in adults is present only in adolescents [10]. Diagnostic procedures in pediatric population are similar to those made in adult patients. Diagnosis includes laboratory findings (complete and differential blood count, ALT (alanine transaminase), AST (aspartate aminotransferase), ALP (alkaline phosphatase), total bilirubin, direct and indirect bilirubin, GGT, amylases and lipases and urine evaluation [11].

There are many diagnostic imaging methods for objectifying gallstones. Radiographic methods are X rays, ultrasound that is sensitive, cheap and reliable diagnostic method and bilious scintigraphy, CT, MRI, fluoroscopic cholangiography, ERCP (endoscopic retrograde cholangiopancreatography) where there is a suspicion for obstruction, choledocholithiasis, biopsy of suspicious lesions, obstructive jaundice, cholangitis and bilious pancreatitis [12]. There is also MRCP, ERCP. Open cholecystectomy was golden standard until early 90.s when it is replaced by laparoscopic cholecystectomy that becomes new golden standard in this disease. Carl Langebuch performed first successful cholecystectomy in 1882. and Phillip Mouret, French gynecologist, performed first laparoscopic cholecystectomy in 1987 [13].

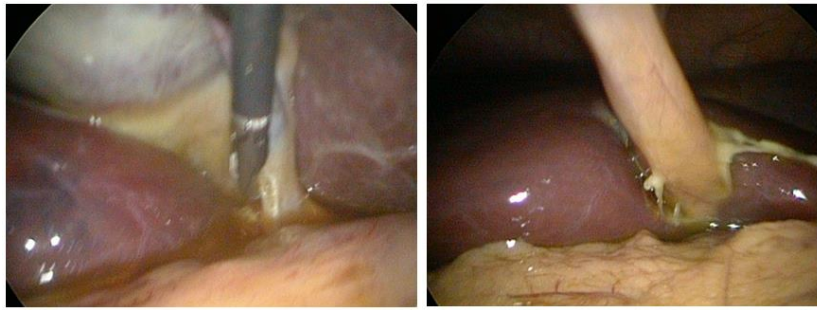
## Material And Methods

Between 2010. and 2022, retrospectively, we explored data points of children who underwent laparoscopic cholecystectomy reviewed with included demographics properties, indication for cholecystectomy, used surgical technique, operative time, complications, and length of hospital stay. In the present series, all patients were intervened using the 4-port technique (except one that was operated with 3-port technique). The pediatric laparoscopic cholecystectomy is completed with dissection of the gallbladder of the liver bed through identification of the Calot's triangle and subsequent binding of the cystic duct and the cystic artery. However, it should always be kept in mind that the biliary system can vary from patient to patient in the pediatric group just like in the adults. Bile duct injury is a frequently reported complication of cholecystectomy in adult patients. The bile duct and cystic canal junction can be easily observed in children by exposing the presence of stone in the bile duct is another problem.

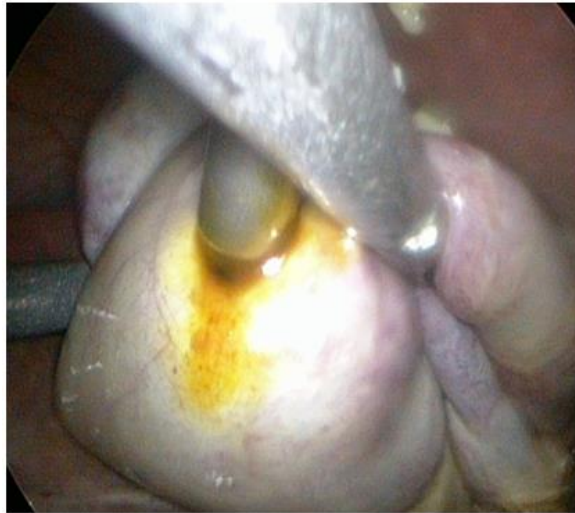We had one patient 14 years old with acute acalculous cholecystitis that was administered to Intensive care unit due to septic condition or unknown etiology. Inflammatory parameters increased and bilirubin and transaminase were within physiological limits. Abdominal ultrasound showed: „... gallbladder with a wall thickness up to 0,5 cm, filled with dense biliary content with pronounced pericholecystitis edema which diameter is 1,28 cm. Intrahepatic and extrahepatic bile ducts are not dilated. Choledochal duct is 0,49 cm in diameter. Pancreas is appropriate sized and homogenous... “. CT was done (arrow shows nonspecific finding of pericholecystic fluid with no signs of gallstones) and laparoscopic cholecystectomy performed.



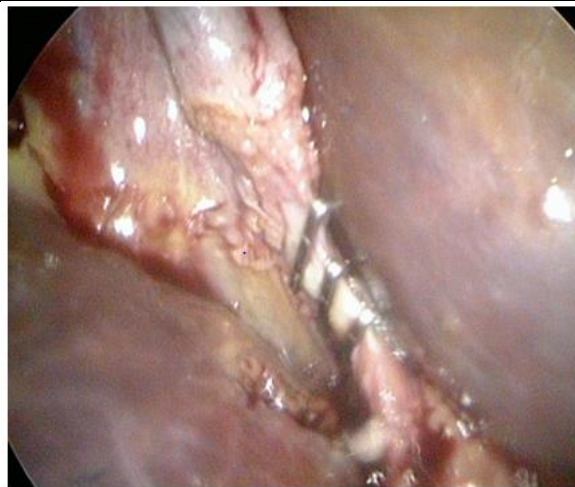**Figure 1:** CT in acalculous cholecystitis - arrow shows nonspecific finding of pericholecystic fluid with no.



**Figure 2, 3:** Acalculosis gangrenous cholecystitis with biliary peritonitis.



**Figure 4:** Punction of the gallbladder.

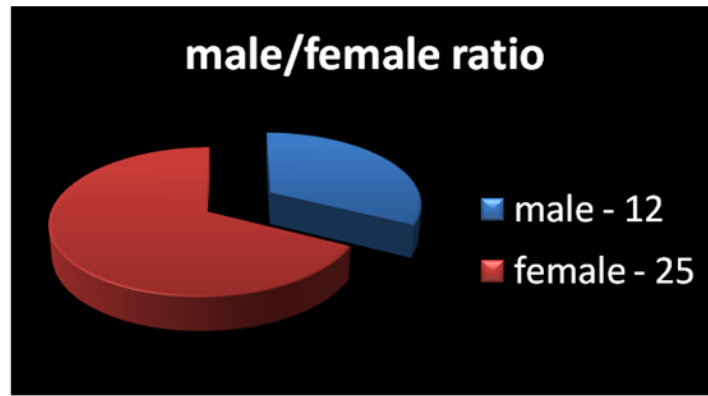


**Figure 5:** Ligation of cytic duct and artery.

## Results

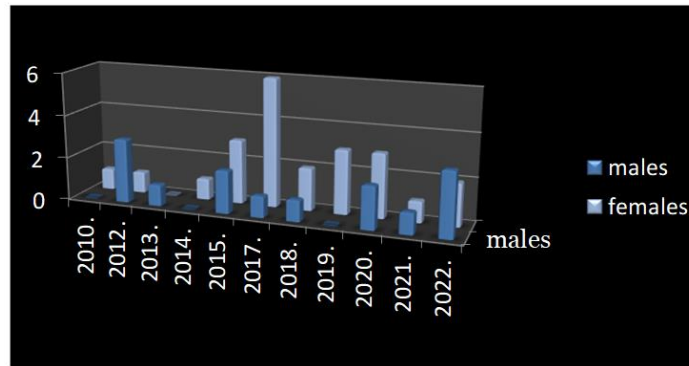
During time frame between 2010. and 2022 we operated laproscopically 37 cholecystes (due to cholelithiasis and one case of cholecystitis without calculi) with 2 conversions to open procedures and via open approach we

treated 3 cholecystes in this period. Male to female distribution was: 12 male patients and 25 female patients. (Diagram 1)



**Diagram 1:** Gender representation: 25 female and 12 males.

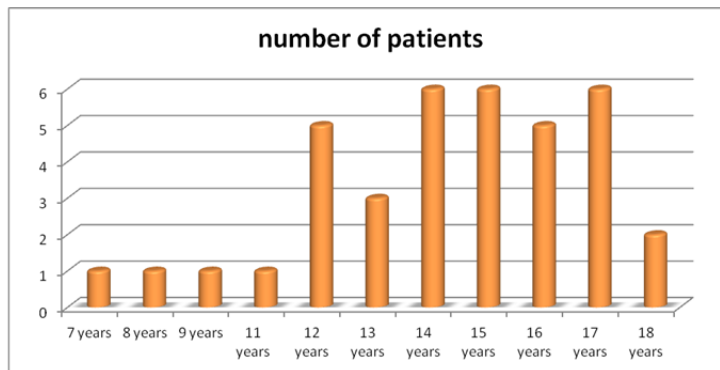
Patients distribution concerning age through years is presented in diagram 2. Most patients in the specified period with cholecystectomy were treated in 2017 (6):



**Diagram 2:** Patients distribution considerin sex through years.

Median age concerning distribution in all years was 11,9, and it is presented in diagram 3.

**Distribution of patients per age:**



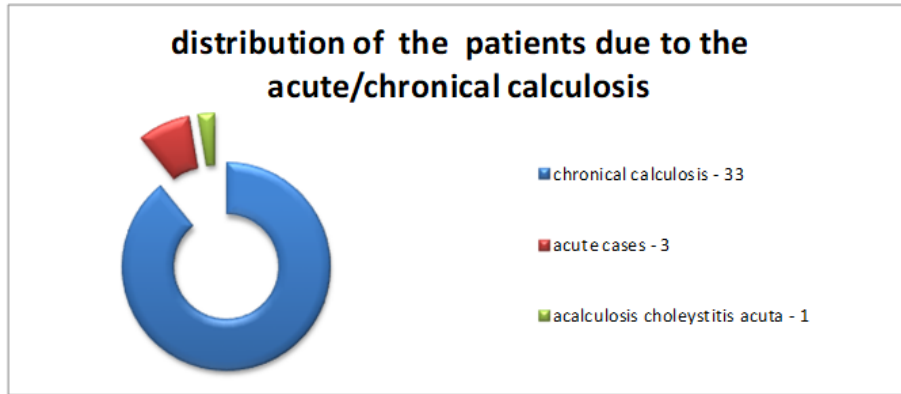
**Diagram 3:** Distribution of patients per age.

Number of hospitalisation days for patients (table 1) - median of hospital stay for all patients was 3-4 days and stay is shortening as we are closing to the later years as can be seen from the table below:

Hospitalization days	2010	2012	2013	2015	2017	2018	2019	2020	2021	2022
Number of days per patient concerning stay	13	18	14	6	4	8	5	6	5	12
Number of days per patient concerning hospital duration		10		6	4	4	6	3	3	4
		14		3	6	4	4	3		4
		11		4				3		4
		9		13				9		3

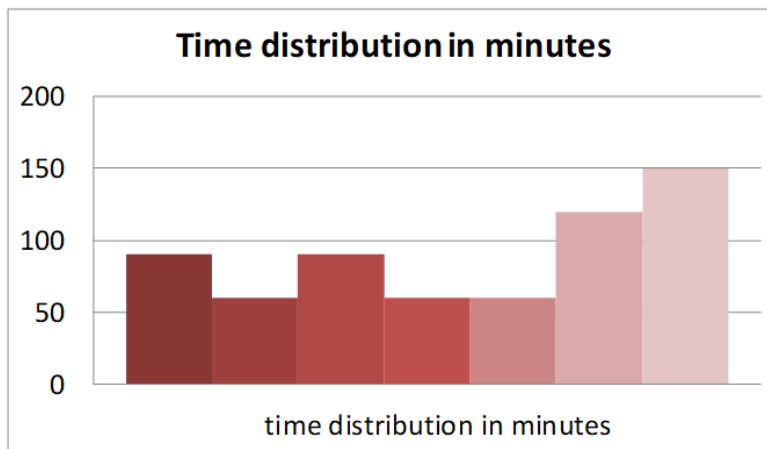
**Table 1:** Number of hospitalisation days for patients.

Most of patient were chronic cases of cholelithiasis, 3 patients were having acute symptoms and one was acute noncalculous cholecystitis with septic condition who was hospitalized at ICU and operated on our Clinic (diagram 4).



**Diagram 4:** distribution of the patients due to acute/chronical calculus.

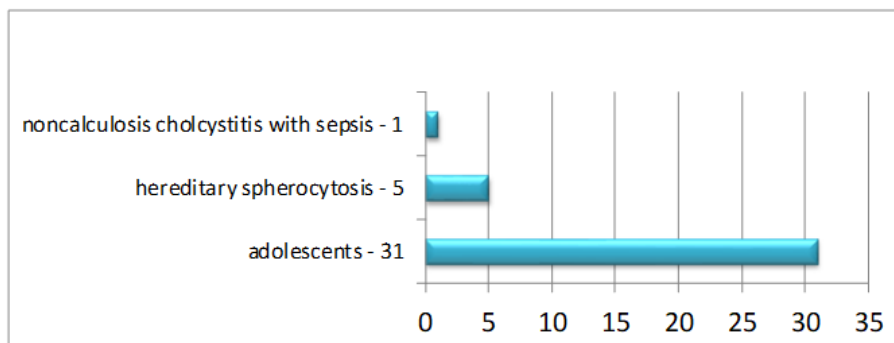
Procedure time was observed during last three years in 9 patients and median is 77 minutes (diagram 5).



**Diagram 5:** Duration of the surgical procedure.

Causes of the cholecystectomies is presented on diagram 6. Out of 37 patients, 5 had hereditary spherocytosis (one had open splenectomy a year after laparoscopic cholecystectomy), one patient had sepsis and noncalculous cholecystitis and other patients were adolescent and therefore had causes like adults:

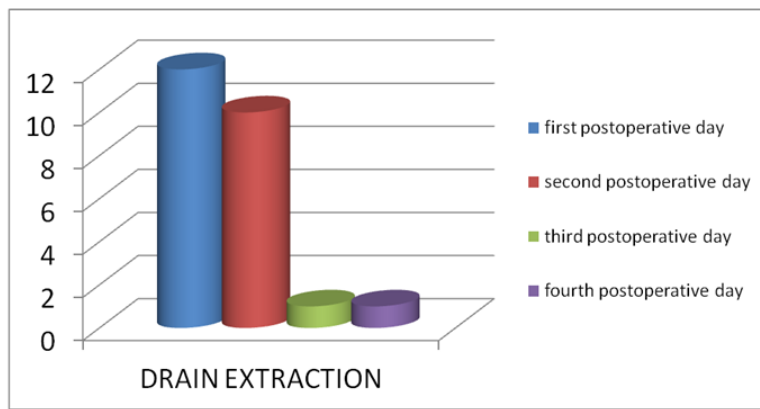
Causes of the cholecystectomies is presented on diagram 6. Out of 37 patients, 5 had hereditary spherocytosis (one had open splenectomy a year after laparoscopic cholecystectomy), one patient had sepsis and noncalculous cholecystitis and other patients were adolescent and therefore had causes like adults:



**Diagram 6:** Causes of the cholecystectomies.

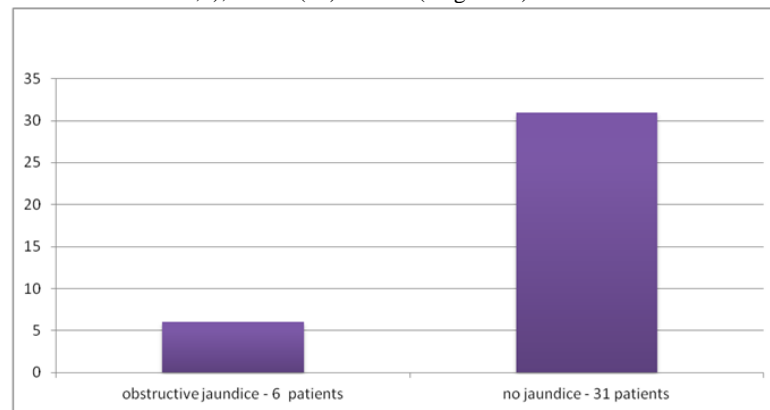
Drain is extracted between first and fourth postoperative day with median of 1,16 days. In several cases we do not have data about time of the drain extraction (diagram 7).





**Diagram 7:** Duration of abdominal drainage.

6 patients had obstructive jaundice (one had direct bilirubine 50,6), others (31) did not (diagram 8).



**Diagram 8:** Existence of obstructive jaundice in patients with cholelithiasis.

**Antibiotic therapy**

Most of the patients were given antibiotics (not to several patients), 4 were treated on ICU, and of those who were administrated with antibiotics (median of antibiotic usage is 6,5 days) these are the data: (Table 2)

Antibiotics	Number of patients	Days of administration median
Cephasolin	15	4, 5, 9, 9, 8, 5, 7, 4, 5, 8, 7, 6, 4 (6,2)
Cephasolin + Metronidasol	9	3, 4, 5, 5, 6, 5, 4, 3, 4 (4,3)
Imipenem + Metronidasol	1	6
Meropenem + Amikacin + Metronidasol	1	12
Amikacin + Longaceph + Metronidasol	1	7
Vankomycin + Longaceph + Metronidasol	1	4

**Table 2:** Types of antibiotics, number of patients and duration of antibiotic administration.

**Discussion**

Boys and girls are equally affected in early childhood, but as in adults, most previous studies reported a female predominance in pediatric gallbladder disease starting from puberty [13,14]. In the study by Wesdrop et al. [15], a female predominance was noted only after the age of 14 years. Kennedy et al [16]. reported equal gender frequency overall. Female gender then increased to 55% above the age of 12 years, although there was no significant difference in sex distribution. In the present study, we found out of 37 patients 67,5% were female patients whereas 32,4% were boys. Above the age of 10 years, females were predominant (p=0.004). As in adults, this corresponds with the time at which cholesterol saturation in bile increases partly due to the secondary effects

of estrogens, preceding the development of cholesterol-related gallstones [17].

The patients included in this study had undergone hematologic and gastroenterologic investigations preoperatively; no hemolytic, endocrinologic or metabolic disorder was detected. It was found out that the patients aged less than six years had received ceftriaxone therapy because of urinary tract infection. Obesity has been reported to be a potential cause of gallbladder stone in children; 16 of our patients were obese.

Related studies in the field have suggested that 80% of the gallbladder stones is symptomatic in adults whereas only 10-33% is symptomatic in children. [18] Esposito et al. [19] stated that non-calcified stones may spontaneously resolve within 3-6 months. Symptomatic or incidentally

detected asymptomatic calcified stones should be intervened through a surgical procedure. 4 of gallbladder stones in our series were symptomatic at the time of administration for operative treatment and we detected only 6 patients who had specific symptoms (jaundice). In our series, the diagnosis was made using ultrasonography for all patients. There are differences between adults and children regarding the cholecystectomy indications and results. While cholecystectomy is frequently performed due to acute inflammation in adults, the main reason for cholecystectomy in pediatric patients without inflammation signs is the prophylactic removal of gallbladder stones [20]. In our study, we operated on only 10,81% of patients in an acute condition, while 89,1% were operated on as a chronic calculous disease. All but one patient had calculous cholecystitis. Since 1987, the year when it was first performed on an adult patient; laparoscopic cholecystectomy has been increasingly used in gallbladder pathologies [21].

In 1991, laparoscopic cholecystectomy was reported to be safe and effective to use in pediatric patients for the first time. (22) After that date, laparoscopic cholecystectomy has become a standard method implemented in children. Laparoscopic cholecystectomy can also be performed through the single-incision laparoscopic surgery technique despite the need for longer time and difficulty of the manipulation of the anatomical structures [23]. The 4-port laparoscopic cholecystectomy is considered as the gold standard for treatment of gallbladder pathology [24]. In the present series, all patients were intervened using the 4-port technique (except one that was operated with 3-port technique). The pediatric laparoscopic cholecystectomy is completed with dissection of the gallbladder of the liver bed through identification of the Calot's triangle and subsequent binding of the cystic duct and the cystic artery. However, it should always be kept in mind that the biliary system can vary from patient to patient in the pediatric group just like in the adults [25]. Bile duct injury is a frequently reported complication of cholecystectomy in adult patients [26]. The bile duct and cystic canal junction can be easily observed in children by exposing the presence of stone in the bile duct is another problem. Although intra-operative cholangiography can be performed in such cases, it is not always a necessity, since this situation is relatively rare. None of our patients needed intra-operative cholangiography during laparoscopy. Postoperative endoscopic retrograde cholangiopancreatography has been suggested to be performed following laparoscopic cholecystectomy in patients in whom such a situation is suspected [27]. If the surgical team encounters difficulties related to previous cholecystitis (e.g., bleeding, perforation of the gallbladder), they may use the alternative of open procedure; however, the open technique was necessary for 1 of our patients [28].

## Conclusions

There are certain specificities in diagnose and treatment in pediatric population when it comes to cholelithiasis that should be taken in consideration.

Children (if not adolescent who usually have same causes for cholelithiasis as adults) can have cholelithiasis due to hereditary hemolytic and non hemolytic diseases, medicaments as well as ceftriaxone and total parenteral nutrition due to existence of ICU where babies who require this treatment now can survive and need this kind of treatment if it is not a case of transient cholelithiasis.

Pediatric cholelithiasis is more prone to complications in some cases so its presentation can occur with complication symptoms.

Unlike in adults where cholelithiasis is not recommended to be treated immediately, in pediatric population cholelithiasis should be treated when it is diagnosed due to possible and often complications.

When it comes to treatment although there are some studies that show that in pediatric population injuries of bile ducts are in higher percentage when

it comes to pediatric laparoscopy, this method of treatment is golden standard for treatment of pediatric cholelithiasis.

## References

- Hinfey P. (2018), Pediatric Pyelonephritis. Updated: Dec 10, 2018.
- Vrbovac B, Jakšić B, Reiner Ž, Vucelić B, editors. Interna medicina. 4. Izmijenjeno i dopunjeno izdanje. Zagreb. Izdavač: Naklada Ljevak, 2008.
- Spitz L, Coran A, Teitebaum D, Tan HL, Pierro A. Operative Pediatric Surgery, 7th edition. Copyright by Taylor & Francis Group, LLC.
- Townsend CM, Evers BM, Beauchamp RD, Mattox KL, Sabiston Textbook of Surgery, 20. Edition. Philadelphia: Elsevier; 2017. pg 1482-1506
- Tannuri AC, Leal AJ, Velhote MC, Goncalves ME, Tannuri U. (2012), Management of gallstone disease in children: a new protocol based on the experience of single center. *J Pediatr Surg.* 47:2033-8.
- Ashley Stanley W. ACS Surgery: Principles and Practice 7th ed. BC Decker INC; 2014.
- Junqueira LC, Carneiro J. Osnovi histologije 10th American edition. Zagreb: Školska knjiga; 2005. pg: 344-6
- Jovanović D. Uticaj lokalnog anestezika na bol posle laparaskopske holecistektomije (disertation). Novi Sad: Medicinski fakultet Univerziteta u Novom Sadu, 2016. 175.p
- Elvan AM. Critical view of safety and Rouvier's sulcus: extrahepatic biliary landmarks as a guide to safe laparoscopic cholecystectomy. *Sci J Al-Ahzar Med Fac Girls* [serial online] 2019 [cited 2020 Jul 12]; 3:297-301.
- The application of the 'open' Hasson blunt trocar insertion technique to the pediatric patients, K. Karavdić, N. Džih, A. Jonuzi, A. Firdus, E. Milišić, A. Karamustafić, *J Surg & Surgical Tech.* 2020;2(1):1-5,
- Brunt M. Strategies of Minimizing Bile Duct Injuries: Adopting a Universal Culture of Safety in Cholecystectomy.
- Strasberg SM, Brunt LM. (2010), Rationale and use of the critical view of safety in laparoscopic cholecystectomy. *J Am Col Surg*; 211(1):132-138.
- Gowda DJ, Agarwal P, Bagdi R, Subramanian B, Kumar M, et al. (2009), Laparoscopic cholecystectomy for cholelithiasis in children. *J Indian Assoc Pediatr Surg*; 14:204-6.
- Haricharan RN, Proklova LV, Aprahamian CJ, Morgan TL, Harmon CM, et al. (2008), Laparoscopic cholecystectomy for biliary dyskinesia in children provides durable symptom relief. *J Pediatr Surg*; 43:1060-1064.
- Wesdorp I, Bosman D, de Graaff A, Aronson D, Van Der Blij F, et al. (2000), Clinical presentations and predisposing factors of cholelithiasis and sludge in children. *J Pediatr Gastroenterol Nutr*; 31 (4):411-417.
- Jensen S W. Postcholecystectomy Syndrome. Updated: Nov 28, 2018.
- Curro G, Iapichino G, Lorenzini C, Palmeri R, Cucinotta E. (2006), Laparoscopic cholecystectomy in children with chronic hemolytic anemia. Is the outcome related to the timing of the procedure? *SurgEndosc*; 20:252-5.
- Chandler NM, Danielson PD. Single-incision laparoscopic cholecystectomy in children: a retrospective comparison with traditional laparoscopic cholecystectomy. *J Pediatr Surg*.

19. Esposito C, Gonzalez Sabin MA, Corcione F, Sacco R, Esposito G, et al. (2001), Results and complications of laparoscopic cholecystectomy in childhood. *Surg Endosc*; 15:890-892.
20. Koebnick C, Smith N, Black MH, Porter AH, Richie BA, et al. (2012), Pediatric obesity and gallstone disease. *J Pediatr Gastroenterol Nutr*; 55:328-333.
21. Bailey PV, Connors RH, Tracy TF, Jr., Sotelo-Avila C, LewisJE, et al. (1989), Changing spectrum of cholelithiasis and cholecystitis in infants and children. *Am J Surg*; 158:585-8.
22. Siddiqui S, Newbrough S, Alterman D, Anderson A, Kennedy A, Jr. (2008), Efficacy of laparoscopic cholecystectomy in the pediatric population. *J Pediatr Surg*; 43:109-113.
23. Reynolds W, Jr. (2001), The first laparoscopic cholecystectomy. *JSL*; 5:89-94.
24. Holcomb GW, 3rd, Olsen DO, Sharp KW. (1991), Laparoscopic cholecystectomy in the pediatric patient. *J Pediatr Surg*; 26:1186-1190.
25. Newman KD, Marmon LM, Attorri R, Evans S. (1991), Laparoscopic cholecystectomy in pediatric patients. *J Pediatr Surg*; 26:1184-1185.
26. Ergun O, Tiryaki S, Celik A. (2011), Single center experience in single-incision laparoscopic surgery in children in Turkey. *J Pediatr Surg*; 46:704-707.
27. St Peter SD, Keckler SJ, Nair A, Andrews WS, Sharp RJ, et al. (2008), Laparoscopic cholecystectomy in the pediatric population. *J Laparoendosc Adv Surg Tech A*; 18:127-30.
28. Lacher M, Yannam GR, Muensterer OJ, Aprahamian CJ, Haricharan RN, et al. (2013), Laparoscopic cholecystectomy for biliary dyskinesia in children: frequency increasing. *J Pediatr Surg*; 48:1716-1721.



This work is licensed under Creative Commons Attribution 4.0 License

To Submit Your Article Click Here:

**Submit Manuscript**

DOI:10.31579/2768-2757/081

#### Ready to submit your research? Choose Auctores and benefit from:

- fast, convenient online submission
- rigorous peer review by experienced research in your field
- rapid publication on acceptance
- authors retain copyrights
- unique DOI for all articles
- immediate, unrestricted online access

At Auctores, research is always in progress.

Learn more <https://www.auctoresonline.org/journals/journal-of-clinical-surgery-and-research>