

Pediatric Subarachnoid Hemorrhage: Rare Events with Important Implications

Abeer Dagra*, Eric Williams, Sina Aghili-Mehrizi, Michael A Goutnik, Melanie Martinez, Ryan C Turner, Brandon Lucke-Wold

Division of Neurosurgery, College of Medicine, University of Florida, USA.

*Corresponding Author: Abeer Dagra, Division of Neurosurgery, College of Medicine, University of Florida, USA.

Received Date: March 01, 2022 | Accepted Date: March 09, 2022 | Published Date: March 26 2022

Citation: A Dagra, E Williams, Sina A Mehrizi, Michael A Goutnik, M Martinez, et al. (2022). Pediatric Subarachnoid Hemorrhage: Rare Events with Important Implications. *J Brain and Neurological Disorders*. 5(1); DOI:10.31579/2642-9730/020

Copyright: © 2022, Abeer Dagra, This is an open access article distributed under the Creative Commons Attribution License, which permits unrestricted use, distribution, and reproduction in any medium, provided the original work is properly cited.

Abstract:

Rupture of an aneurysm is the leading cause of subarachnoid hemorrhage (SAH) which results in accumulation of blood between the arachnoid and pia mater, consequently increasing intracranial pressure. This often results in life threatening conditions like herniation or clinical presentations including focal neurological deficits. In children, these events, although rare, have significant implications. Pediatric SAH is associated with better outcomes in the hospital setting and may even be prevented proactively by the recognition of potential risk factors. Specifically, better recognition of genetic predispositions, metastatic lesions, and infectious causes of aneurysms is important to understand their growth and prevent hemorrhagic events. This review highlights the causes of pediatric SAH, reviews the models of current understanding of this etiology, and discusses the current treatment schema to provide a succinct summary and highlight gaps in current knowledge. This may lead to future investigations aimed at further improving prevention strategies, patient care, and patient outcomes.

Keywords: subarachnoid hemorrhage; aneurysm; SAH management; pediatric population.

Introduction:

Pediatric subarachnoid hemorrhage (pSAH) is a relatively rare clinical event with life-threatening implications that affect 0.5 percent to 4.6 percent of children [[1, 28, 31, 43, 44, 49]]. Aneurysms, arteriovenous malformations, and pediatric tumors are the most common causes of pSAH. Increased predilection is based on genetics or underlying infection. Common symptoms of pSAH include lethargy, irritability, seizures, increased or decreased muscular tone, altered consciousness, vomiting, poor eating, breathing problems, and apnea [[18]]. Common causes of pSAH include genetic and infectious etiologies that predispose children to develop aneurysms. One of the probable complications of pSAH is brain swelling, or hydrocephalus; this buildup of cerebrospinal fluid (CSF) and blood between the brain and the skull raises the intracranial pressure [29, 58, 62, 63, 75]. In an event of SAH, blood vessels in the brain can become irritated and damaged by the breakdown of blood products (including oxyhemoglobin) leading them to constrict which limits intracerebral blood flow [15, 58, 62]. This could lead to stroke and further exacerbation of the existing injury. Potential consequences of the bleeding include lifelong brain damage, paralysis, or coma in severe circumstances. Given these implications of pSAH, the need for understanding the causation and to plan the management of these events is vital for improved patient outcomes.

Genetics:

Aneurysms in children are thought to be characterized by changes in arterial flow, extracellular matrix, and arterial wall deterioration or repair, all of which may trigger molecular alterations that lead to formation of aneurysms [33, 76]. Genetic and infectious predispositions include: Alagille syndrome, sickle cell anemia, irradiation, cardiac myxoma (Carney complex), HIV/AIDS, tuberous sclerosis, vascular anomalies, Marfan syndrome, syphilis, Moya Moya disease, pseudoxanthoma elasticum, type IV Ehlers-Danlos syndrome, fibromuscular dysplasia, von Hippel-Lindau syndrome, arterio-venous malformations secondary to Osler-Weber-Rendu Syndrome, hypertension, coarctation of the aorta and polycystic kidney disease. [13, 31, 76] (summarized in Table 1). In addition, compared to the adult population, mycotic aneurysms make up a greater fraction of aneurysms (4%) in the pediatric population [5, 28]. In immunocompetent individuals, *Staphylococcus aureus* and *Streptococcus* are the causal organisms, while in immunocompromised patients, *Aspergillus*, *Candida*, and *Phycomycetes* are the causative organisms [3, 31, 76].

Although uncommon, pSAH secondary to neoplasms has been recorded in 3-10% of cases, with medulloblastoma (malignant), primitive neuroectodermal tumors, malignant astrocytomas, and ependymomas being the most prevalent [24, 72]. Possible disruption of tumor vasculature due to the increasing tumor size, direct tumor infiltration of

vessels, and/or aberrant tumor vascularity are some of the theorized mechanisms for aneurysm development and rupture [72].

Etiology	Description	Genetic mutation	References
Alagille syndrome	Chronic cholestasis due to a lack of intrahepatic bile ducts, congenital heart disease primarily affecting the pulmonary outflow tract and vasculature, butterfly vertebrae, a broad forehead, posterior embryotox and/or anterior segment abnormalities of the eyes, and pigmentary retinopathy are among the main clinical features and malformations of this autosomal dominant defect. Intracranial hemorrhage and renal dysplasia are two prominent characteristics.	JAG1 NOTCH2 mutation (rare cases)	[58, 65, 76]
Sickle cell anemia	This autosomal recessive genetic disorder causes sickle-shaped red blood cells that are sticky and defective, resulting in ischemia. Despite the fact that cerebral infarctions are more common, aneurysm growth contributes to SAH in the population.	HBB gene on chromosome 11	[59, 61]
Carney Complex	Myxomas that begin in childhood and reoccur, causing disruptive cardiac outflow, embolic, and aneurysmal problems that contribute to stroke, are all symptoms of this autosomal dominant pattern disorder.	PRKAR1A/2p16 and 17q22-24 (unknown gene)	[59, 67]
Sturge-Weber Syndrome	Causes the growth of aberrant blood vessels in a child's face, brain, or both. Venous congestion is thought to be a key cause of SAH and ICH in this population. Majority of children are born with a mark on their face termed a capillary malformation or port wine stain.	GNAQ gene on chromosome 9q21	[40, 45, 59]
Tuberous Sclerosis	Mental retardation, epilepsy, and adenoma sebaceum are the classic triad of this autosomal dominant defect. Multiple intracranial aneurysms and kidney cysts are associated with it.	TSC1 on chromosome 9 and TSC2 on chromosome 16	[40, 59]
vascular anomalies	The inability to repair or maintain vascular integrity, as well as the presence of less stable versions of normal anatomy that are prone to aneurysm formation.	Secondary to various congenital diseases	[40, 59]
Marfan syndrome	Aneurysms and hemorrhagic strokes are among the neurovascular consequences of this autosomal dominant musculoskeletal disorder.	Fibrillin-1 on chromosome 15	[40, 59]
Moya Moya Disease (MMD)	Autosomal dominant inheritance disease with thickened intima of major branches of the circle of Willis and Moya Moya arteries as a general finding. In individuals with MMD, intracerebral hemorrhage is a common cause of mortality.	Mutations in chromosome 3p24.2-26, and 17q	[10, 23, 35, 59]
Pseudoxanthoma elasticum	An autosomal dominant and recessive inheritance condition that generates cerebral and cardiovascular aneurysms.	ABCC6/16p13.1	[59]
Type IV Ehlers-Danlos syndrome	Ehlers-Danlos syndrome is characterized by hyperplastic skin and hyperextensible joints due to an autosomal dominant collagen synthesis deficiency. Furthermore, Ehlers-Danlos vascular type IV is associated with spontaneous rupture of arteries, including intracranial arteries.	type III procollagen (COL3A1) on chromosome 2q	[40, 59]
von Hippel-Lindau Syndrome (VHL)	Through the activities of transcription factors, growth factors, and matrix metalloproteinases, the VHL tumor suppressor gene may be causally linked to aneurysm formation, resulting to SAH in some cases. Although hemangioblastomas in VHL are noninvasive, their increasing size can compress tissue and disrupt blood flow or they may hemorrhage, resulting in the observed clinical symptoms.	VHL gene on chromosome 3	[8, 12, 59]

Osler-Weber-Rendu Syndrome or Hereditary Hemorrhagic Telangiectasia (HHT)	Telangiectasias of the skin and mucosal membranes, as well as arteriovenous abnormalities in internal organs, contribute to hemorrhagic strokes.	Endoglin (ENG)/9q33–q34.1 and ALK1 or ACVRL1/12q11–q14	[59]
Autosomal Dominant Polycystic Kidney Disease (ADPKD)	Intracerebral aneurysms caused by ADPKD are uncommon in children, but they are highly influenced by family history. Documented prevalence rates range from 0% to 41%.	PKD1 gene on chromosome 16 PKD2 gene on chromosome 4	[19, 40, 48, 55, 59, 69]

Table 1: Genetic Predispositions of Pediatric Subarachnoid hemorrhage

Vascular abnormalities:

Pediatric aneurysms differ from classical adult aneurysms; they are rarer, tend to be larger, have an overall male predominance, are commonly caused by infection or trauma, and have increased predilection for the posterior circulation [28, 31, 44, 50, 52, 70]. Additionally, aneurysms in children tend to be associated with congenital disorders [3, 5, 13, 31, 40, 44, 47, 50, 66] (table 1).

Intracranial aneurysms may present in children commonly 2–4 weeks (but up to 10 years) following trauma, usually a closed head injury (72% of cases) and may present with massive epistaxis [26, 57]. Traumatic brain injury may damage the distal anterior carotid artery (ACA) in 40% of cases, the major vessels along the skull base in 35% of cases, and the distal cortical vessels in 25% of cases [37]. The patient presents with hemorrhage in about 50% cases and can present with subarachnoid hemorrhage, sub- or extradural hematoma, or intracranial hypertension [51].

Arteriovenous malformation (AVM) is perhaps the most important cause of intracranial vascular aneurysm formation responsible for 30–50% of spontaneous intracranial hemorrhages in this population [14]. An AVM is an abnormal connection between arterial and venous blood vessels that can occur anywhere in the body. When they occur, high pressure arterial blood does not flow into capillaries and tissue but instead, directly into the thin-walled venous structures. These venous structures become damaged due to the high flow and pressure, leading to aneurysm and rupture. Intracranial hemorrhage is the presenting clinical manifestation in 75–80% of pediatric patients with AVMs and is associated with a high morbidity and mortality [53]. In a study by Zheng et al., 70.9% of their cohort of 127 children with AVMs presented with hemorrhage, and size and deep venous drainage were found to be independently associated with hemorrhage risk [74]. Another study looked at a cohort of 132 children with AVMs over a 40 year span and found that 79% of their patients ended up hemorrhaging [36]. In this study, the mortality was found to decrease from 39% to 16% after the introduction of computed tomography (CT), with an overall series mortality of 25% and location being the primary causative factor; 8/14 patients with cerebellar AVM passed away, while only 2/44 patients with cerebral hemisphere AVM passed [36].

Intracranial aneurysms associated with infection, or infectious intracranial aneurysms (IIAs), account for about 15% of all pediatric intracranial aneurysms. The most common etiology of IIAs is septic emboli secondary to bacterial endocarditis, an intravascular source of infection which causes vegetation of an infected cardiac valve and subsequent embolization [17, 37, 46]. The bacterial source for IIAs is most commonly *Staphylococcus aureus*, but they can also be caused by fungal or viral infection [17, 37]. Blood and CSF cultures show the causative organism in about 2/3 of patients. The typical locations include the distal small arteries, the skull base, and cavernous sinus. The clinical presentation is varied but generally presents after severe intracranial hemorrhage and carries a 60–90% mortality when bacterial, while fungal infections are even more lethal [[17, 37, 46]]. IIAs are typically friable

and thin walled, with a resultant high rupture tendency, however, even without rupture, IIAs are associated with a mortality of up to 30% [17]. Unlike other sources of aneurysm, in which size is a predictive factor in likelihood for rupture, size is not predictive of rupture for IIAs. Small IIAs rupture at high rates while larger ones tend to produce symptoms through mass effect [17].

Pre-clinical models of Juvenile SAH:

Due to the rarity of SAH in the pediatric population, proposed models regarding this fatal condition are limited. However, retrospective studies help in better understanding the factors that contribute to SAH between the adult and the pediatric population. For example, male children develop cerebral aneurysms more commonly than female children. In adulthood, however, this pattern reverses and females have a greater tendency to develop aneurysms [64]. Aneurysms typically form at the internal carotid artery (ICA) bifurcation, where rupture occurs in most pediatric patients [30]. It is also important to note that pediatric patients are more likely to present with SAH than adult patients [70]. This is clinically important because if there is a factor of interest between the adult and pediatric population then it could be an area of research that can be focused on to better understand the prevalence of pediatric SAH.

Although, AVM or neoplasm development present a risk for SAH, most pediatric SAHs mostly occur when a cerebral aneurysm develops due to these etiologies or independently of them [30]. Trauma induced aneurysmal development, whether it be accidental or non-accidental, is the most common cause of SAH in the pediatric population [66]. Traumatic SAHs result from the tearing and weakening of intracerebral blood vessels, resulting in intracranial aneurysms, due to the force of the trauma. Non-traumatic SAHs are seen in patients with pre-disposing factors associated to an impairment to the arterial wall. A possible explanation for pediatric non-traumatic SAHs may be due to a deficiency of a necessary protein essential for arterial wall functionality [64]. Studies have highly suggested the prevalence of SAH among the pediatric population may be due to a degradation of the internal elastic lamina and arterial medial layer. A possible explanation for this could be a lack of α_1 -antitrypsin [70]. α_1 -antitrypsin is a glycoprotein whose function is to inhibit proteases, like elastase and collagenase, from degrading connective tissue, specifically, connective tissue that surrounds the tunica media in the arterial wall [55]. This protein deficiency may increase aneurysm rupture incidence among the pediatric population, and it should be considered that this may also explain the larger appearance of pediatric intracranial aneurysms, which is not typical with adult intracranial aneurysm cases [66]. There is also a hemodynamic stress factor that might add to the propensity of developing cerebral aneurysms, and rupture, in children because of their susceptibility to develop aneurysms at the ICA bifurcation [59].

SirT1 is another protein that has gotten attention because of its involvement in regulating the vasculature through various mechanisms but importantly vascular smooth muscle structural and functional homeostasis [11, 20, 25, 41]. Physiological cyclic stretch maintains

vasoconstriction by promoting VSM contractile characteristics via SirT1/FOXO3a [32]. A study found that the absence of SirT1 in VSM-specific SirT1-ablated mice does not result in any obvious vascular functional impairment, but when exposed to pro-inflammatory and pro-oxidant stressors, such as angiotensin II (angII) infusion, arterial ligation, hyperlipidemic apoE^{-/-} genetic background, aging, and a diet high in fat and sucrose, this defect in SirT1 causes vascular disease, including atherosclerosis, aortic stiffness and dissection [20, 21, 25]. Sirtuin 1 may be repressed with changes in brain function and vasculature in some vulnerable populations which has been connected to the role of nutrition and xenobiotics; and may be relevant to pediatric subarachnoid hemorrhage treatment [9, 16, 20, 22, 32, 41].

Finally, the infectious model of Juvenile pSAH highlights mycotic aneurysms which usually arise from the arterial adventitia and present at arterial branches. They typically hemorrhage due to vessel wall impairment [59]. Bacterial organisms, such as staphylococcus aureus, lead to the degradation of the arterial wall by inflammatory processes. Because of the bacterial presence, neutrophils will be attracted to the area and infiltrate the tissue causing acute and chronic inflammation possibly through neutrophils' effector functions, thus degrading the arterial's media as well as the internal elastic lamina [73]. With these factors in play, a mycotic aneurysm will grow with continuous inflammation and decreased tissue healing leading to hemorrhage.

Treatment:

Pediatric SAH may be treated effectively by either microsurgery or endovascular techniques such as coil embolization whereby an aneurysm is stabilized to prevent rupture by placing a coil that prevents enlarging of false lumen [30, 42, 50, 54, 56, 59, 60, 71]. Choice of procedure may be decided based on location, Hunt and Hess grade, complex shape, amenability to coiling, vessel occlusion probability, and parental choice [50, 56, 60, 71]. The decision should not be influenced by aneurysm size [60]. Depending on the preferences of the institution, endovascular approaches may be employed for specific anatomic locations, such as the basilar trunk and posterior cerebral artery (PCA) [56]. Surgical excision remains the treatment of choice for parenchymal AVMs in children [36, 53, 74], with complete removal achieved in most patients (upto 90%). Complete AVM resection usually results in normal neurological outcome [36].

Treatment options also include endovascular embolization and stereotactic radiosurgery alone or in combination. The Spetzler-Martin (SM) grading scale, which estimates the risk for patient with undergoing neurosurgery by evaluating the AVM size, location, and pattern of venous flow, is often used to determine the treatment modality, with low grade, accessible SM grade 1-3 AVMs being best managed with surgery, while low grade inaccessible AVMs are best treated with stereotactic radiosurgery. High grade (SM grade 4-5) AVMs in pediatric patients are often deep or inaccessible making surgical excision less possible. The best treatment modality for these AVMs is unclear [53]. Conservative management for children with AVMs is generally not recommended, with an annual risk of rupture increasing by 2-4% per year [14, 36, 37, 53, 74].

Aggressive management is likely to result in superior clinical outcomes in pediatric patients [36, 37, 53, 74]. Moreover, Stiefel et al. suggested that surgical intervention may be first line, but coil embolization is preferred when surgery is not viable, or the aneurysm is located at the basilar apex [50]. Long-term follow up studies are needed to compare the durability of coiling compared to standard microsurgical clipping because of better outcomes in children contributing to longer survival. Thus, comparing the modalities in preventing future hemorrhage is a uniquely important consideration in the pediatric population [50, 71].

Pediatric patients are more likely to have favorable post-surgical outcomes, compared to adults [68]. Favorable outcomes range from approximately 63.6% to 90% depending on the preoperative status as determined by Hunt and Hess classification [50, 56, 60, 71]. In one study involving 22 children with aneurysms, 21 of whom presented with SAH, 13 had a good preoperative Hunt and Hess Grades (between I and III), while 8 had a poor preoperative grade (IV or V) [50]. 11/13 (84.6%) children with good Hunt and Hess grade had a favorable outcome compared to 2/8 (25%) with poor Hunt and Hess grade (54). Causes of poor postsurgical outcome include rebleeding, infarct secondary to vasospasm, meningitis, and thrombosis [42, 50, 56].

As in adults, it is important to prevent rebleeding and vasospasm in pSAH. Rebleeding appears to occur more frequently in children (as high as 60%), perhaps because of delayed SAH diagnosis [50, 68]. This may be the result of children presenting in better neurological condition than adults [68]. Early intervention following SAH diagnosis is important for the prevention of this complication [34]. Regarding vasospasm, oral nimodipine may be employed as prophylaxis [2]. In one study involving 12 children with SAH, the mean oral dose of nimodipine was approximately 1mg/kg every 4 hours [27]. However, hypotension was a common side effect in the pediatric population, and in over 3/4 of the subjects, medical intervention was required as a result [7].

Furthermore, postoperative angiographs confirmed vasospasm may be asymptomatic more often in children [38, 50]. Proust et al. hypothesized that this pediatric vasospasm tolerance could be due to collateral circulation which reduces vasospasm-related hypoperfusion [50]. When vasospasm does occur, it can be treated with "triple-H" therapy, which consists of volume expansion, mild hypertension induction, and hemodilution with aims of increasing perfusion and preventing vascular constriction which may prevent ischemic events and parenchymal damage; Although the efficacy of the therapy is not unanimously agreed upon, it has been used when needed, however it comes with its own risks including pulmonary edema, myocardial ischemia, hyponatremia, indwelling venous catheter-related complications, cerebral hemorrhage, and cerebral edema. [7, 38, 39].

Of note, perimesencephalic nonaneurysmal subarachnoid hemorrhage (PNSH) is a benign, idiopathic SAH seen in approximately 15% of children with atraumatic SAH and presents with perimesencephalic or prepontine blood products on CT with negative subsequent angiogram [4]. Up to 19% of pSAH may be idiopathic, so PNSH should not be missed as it does not require significant treatment like aneurysmal SAH [30]. Furthermore, a case of non-aneurysmal SAH related to SARS-CoV-2 has been reported in a pediatric patient [6]. Thus, the COVID-19 pandemic perhaps may influence the development of pSAH and needs to be further studied.

Prior to surgical intervention, common pSAH management practices include Hunt and Hess grading, CT scan, digital subtraction angiography, aggressive intensive care, vasospasm prophylaxis, and EVD and ICP monitoring for those with poor preoperative grade [42, 50, 56, 60]. Rationale for surgical modality was discussed above, and this decision should be made by a multidisciplinary team consisting of neuro-interventionalists and fellowship-trained pediatric neurosurgeons [42, 50, 60]. Early treatment (within 3 days of diagnosis) is preferred.

Postoperatively, a standard protocol should include nimodipine, seizure prophylaxis, steroids, and "triple-H" therapy for those who develop vasospasm [38, 56]. Then, routine CT scanning or angiography should be done yearly until the age of 18, followed by noninvasive imaging every 5 years thereafter [50, 60]. Those younger than 2 years old may be evaluated by geneticists [60] Based on this information, a treatment algorithm for pSAH is proposed in Figure 1.

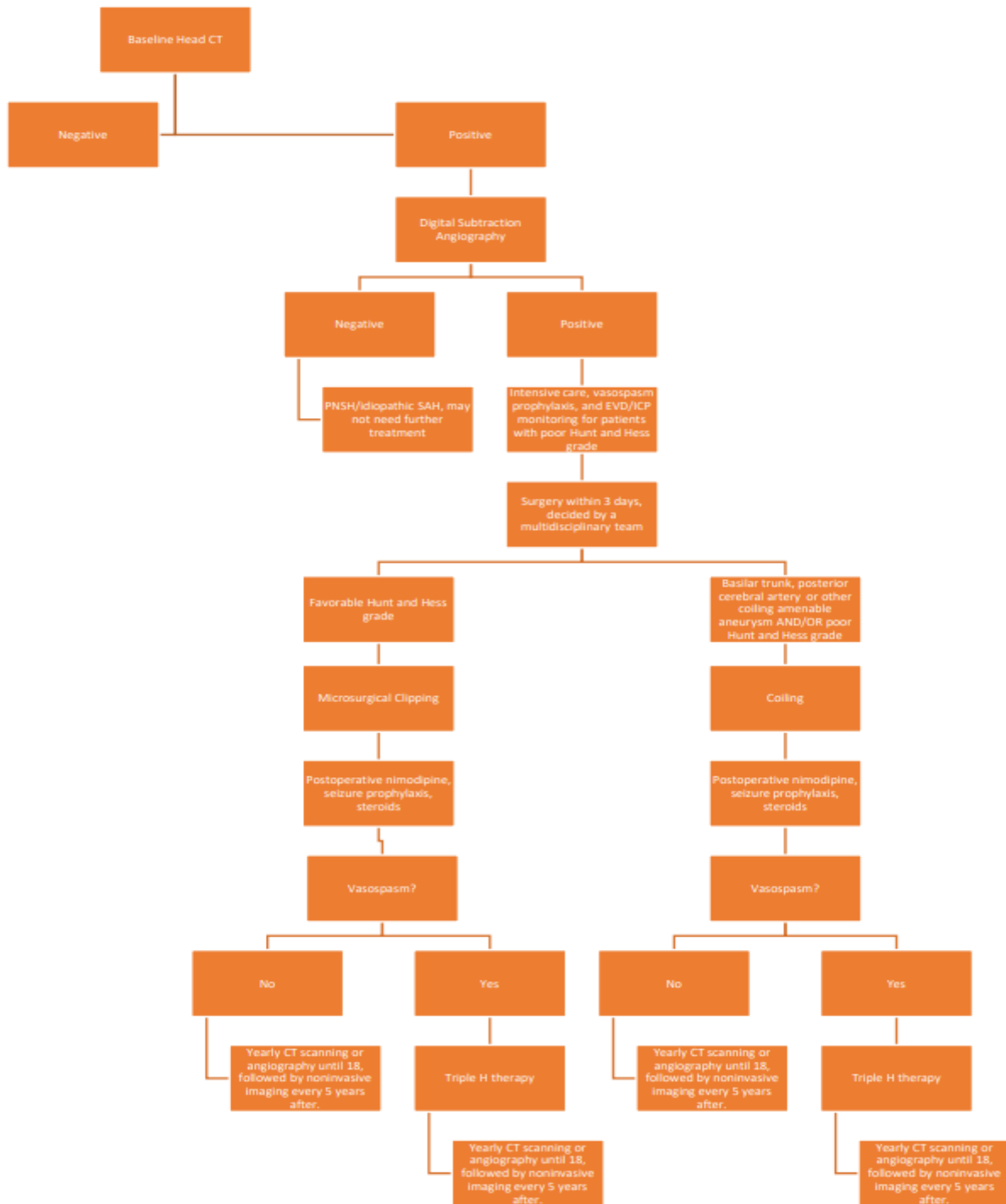


Figure 1: The figure shows a schematic of the SAH diagnosis and management according to current literature. CT scan is performed for initial screening for suspected subarachnoid hemorrhage and the consequent algorithm represents treatment options and monitoring strategies which are currently the standard of treatment.

Conclusion:

SAH is associated with trauma, infection, and vascular abnormalities in the pediatric population, and it requires high levels of care during management and after discharge. However, when identified in a timely manner, the outcomes for patients with pSAH are more favorable in this population. Specifically, preventing rebleeding and vasospasms, using

pharmacotherapy to improve blood flow, and closely monitoring symptoms and vitals help prevent neurologic and hemodynamic complications. Patients who may develop such complications may require extended hospital stay, additional surgeries, and therapies like Triple-H. Many SAH survivors may develop chronically disabling medical disorders, including issues with mood, neurophysiological function, and memory. For populations with predisposing genetic conditions that affect

vasculature (e.g. AVM formations), early monitoring may be an effective preventative measure for these acute events. Moreover, closing the knowledge gap on epidemiological and biochemical predisposition to aneurysmal growth and rupture will inspire better preventive, management, and treatment protocols for pSAH.

References

1. Agid, R. et al. (2007). Diagnostic characteristics and management of intracranial aneurysms in children. *Neuroimaging clinics of North America*. (17)2:153-163.
2. Allen, G.S. et al. (2010). Cerebral Arterial Spasm-A Controlled Trial of Nimodipine in Patients with Subarachnoid Hemorrhage. (308)11:619-624.
3. Allison, J.W. et al. (1998). Intracranial aneurysms in infants and children. *Pediatric radiology*. (28) 4:223-229.
4. Anderson, R.C. et al. (2002). Perimesencephalic Nonaneurysmal Subarachnoid Hemorrhage in the Pediatric Population: Case Report and Review of the Literature. *Pediatric Neurosurgery*. (37)5: 258-261.
5. Aryan, H.E. et al. (2006). Aneurysms in children: review of 15 years' experience. *Journal of clinical neuroscience: official journal of the Neurosurgical Society of Australasia*. (13)2:188-192.
6. Basirjafari, S. et al. (2021). Association of pediatric COVID-19 and subarachnoid hemorrhage. *Journal of medical virology*. (93)2:658-660.
7. Bederson, J.B. et al. (2009). Guidelines for the management of aneurysmal subarachnoid hemorrhage: A statement for healthcare professionals from a special writing group of the stroke council, American heart association. *Stroke*. 40(3):994-1025.
8. Binderup, M.L.M. et al. (2017). Survival and causes of death in patients with von HippelLindau disease. *Journal of medical genetics*. (54)1:11-18.
9. Budbazar, E. et al. (2020). The Role of Sirtuin-1 in the Vasculature: Focus on Aortic Aneurysm. *Frontiers in Physiology*. 11:1047.
10. Burke, G.M. et al. (2009). Moyamoya disease: a summary. *Neurosurgical focus*. (26)4:1-10.
11. Chen, H.Z. et al. (2016). Age-Associated Sirtuin 1 Reduction in Vascular Smooth Muscle Links Vascular Senescence and Inflammation to Abdominal Aortic Aneurysm. *Circulation research*. (119) 10:1076-1088.
12. Chew, M.Y. (2005). OCULAR MANIFESTATIONS OF VON HIPPEL-LINDAU DISEASE: CLINICAL AND GENETIC INVESTIGATIONS. *Transactions of the American Ophthalmological Society*. 103:495.
13. Cowan, J.A. et al. (2004). Progression of a posterior communicating artery infundibulum into an aneurysm in a patient with Alagille syndrome. Case report. *Journal of neurosurgery*. (101)4:694-696.
14. Darsaut, T.E. et al. (2011). Management of pediatric intracranial arteriovenous malformations: experience with multimodality therapy. *Neurosurgery*. (69)3:540-556.
15. Director, E. et al. MEDICAL ADVISORY BOARD Southeast Regional Directors.
16. Donato, A.J. et al. (2011). SIRT-1 and vascular endothelial dysfunction with ageing in mice and humans. *The Journal of Physiology*. (589)18:4545.
17. Ducruet, A.F. et al. (2010). Intracranial infectious aneurysms: A comprehensive review. *Neurosurgical Review*. (33)1:37-46.
18. Duhaime, A.-C. et al. (1998). Nonaccidental head injury in infants--the "shaken-baby syndrome." *The New England journal of medicine*. (33)25:1822-1829.
19. Forster, F.M. and Alpers, B.J. (1943). ANEURYSM OF CIRCLE OF WILLIS ASSOCIATED WITH CONGENITAL POLYCYSTIC DISEASE OF THE KIDNEYS. *Archives of Neurology & Psychiatry*. (50)6:669-676.
20. Fry, J.L. et al. (2015). Vascular Smooth Muscle Sirtuin-1 Protects Against Aortic Dissection During Angiotensin II-Induced Hypertension. *Journal of the American Heart Association*. (4)9.
21. Fry, J.L. et al. (2016). Vascular Smooth Muscle Sirtuin-1 Protects Against Diet-Induced Aortic Stiffness. *Hypertension (Dallas, Tex.: 1979)*. (68)3:775-784.
22. Frye, R.A. (2000). Phylogenetic classification of prokaryotic and eukaryotic Sir2-like proteins. *Biochemical and biophysical research communications*. (273)2:793-798.
23. Fukui, M. et al. (2000). Moyamoya disease. *Neuropathology: official journal of the Japanese Society of Neuropathology*. 20:61-64.
24. Garg, A. et al. (2004). Juvenile pilocytic astrocytoma presenting with subarachnoid hemorrhage. Case report and review of the literature. *Journal of neurosurgery*. (100)5:525-529.
25. Gorenne, I. et al. (2013). Vascular smooth muscle cell sirtuin 1 protects against DNA damage and inhibits atherosclerosis. *Circulation*. (127)3:386-396.
26. Hahn, Y.S. et al. (1990). Traumatic intracavernous aneurysm in children: massive epistaxis without ophthalmic signs. *Child's nervous system : ChNS : official journal of the International Society for Pediatric Neurosurgery*. (6)6:360-364.
27. Heffren, J. et al. (2015). Nimodipine for the prevention of cerebral vasospasm after subarachnoid hemorrhage in 12 children. *Pediatric neurology*. (52)3:356-360.
28. Herman, J.M. et al. (1991). Pediatric intracranial aneurysms: simple and complex cases. *Pediatric neurosurgery*. (17)2:66-73.
29. Hourihan, M.D. et al. (1984). Subarachnoid hemorrhage in childhood and adolescence. *Journal of Neurosurgery*. (60)6:1163-1166.
30. Hourihan, M.D. et al. (1984). Subarachnoid hemorrhage in childhood and adolescence. *Journal of Neurosurgery*. (60)6:1163-1166.
31. Huang, J. et al. (2005). Intracranial aneurysms in the pediatric population: case series and literature review. *Surgical neurology*. (63)5:424-432.
32. Huang, K. et al. (2015). SIRT1 and FOXO Mediate Contractile Differentiation of Vascular Smooth Muscle Cells under Cyclic Stretch. *Cellular physiology and biochemistry: international journal of experimental cellular physiology, biochemistry, and pharmacology*. (37)5:817-1829.
33. Kassam, A.B. et al. (2004). Altered arterial homeostasis and cerebral aneurysms: a molecular epidemiology study. *Neurosurgery*. (54)6:1450-1462.
34. Kassell, N.F. et al. (1990). The International Cooperative Study on the Timing of Aneurysm Surgery: Part 2: Surgical results. *Journal of Neurosurgery*. (73)1:37-47.
35. Kobayashi, E. et al. (2000). Long-term natural history of hemorrhagic moyamoya disease in 42 patients. *Journal of neurosurgery*. (93)6:976-998.
36. Kondziolka, D. et al. (1992). Arteriovenous Malformations of the Brain in Children: A Forty Year Experience. *Canadian Journal of Neurological Sciences*. (19)1:40-45.
37. Krings, T. et al. (2010). Pathomechanisms and treatment of pediatric aneurysms. *Child's Nervous System*. (26)10:1309-1318.
38. Krishna, H. et al. (2005). Intracranial aneurysms in patients 18 years of age or under, are they different from aneurysms in adult population? *Acta neurochirurgica*. (147)5:469-476.

39. Lee, K.H. et al. (2006). "Triple-H" therapy for cerebral vasospasm following subarachnoid hemorrhage. *Neurocritical care.* (4)1:68-76.
40. Levy, M.L. et al. (2021). Pediatric Cerebral Aneurysm. *Brain Imaging with MRI and CT: An Image Pattern Approach.* 297-298.
41. Li, L. et al. (2011). SIRT1 acts as a modulator of neointima formation following vascular injury in mice. *Circulation research.* (108)10:1180-1189.
42. Liang, J. et al. (2009). The clinical features and treatment of pediatric intracranial aneurysm. *Child's nervous system: ChNS: official journal of the International Society for Pediatric Neurosurgery.* (25) 3:3170-324.
43. Locksley, H.B. (1966). Natural history of subarachnoid hemorrhage, intracranial aneurysms and arteriovenous malformations. Based on 6368 cases in the cooperative study. *Journal of neurosurgery.* (25)2:219-0239.
44. Meyer, F.B. et al. (1989). Cerebral aneurysms in childhood and adolescence. *Journal of neurosurgery.* (70)3:420-425.
45. Nakajima, M. et al. (2014). Sturge-Weber syndrome with spontaneous intracerebral hemorrhage in childhood. *Journal of neurosurgery. Pediatrics.* (13)1:90-93.
46. Ocak, P.E. et al. (2017). Intracranial Infectious Aneurysms. *Contemporary Neurosurgery.* (39)10:1-5.
47. Ogungbo, B. et al. (2003). Aneurysmal subarachnoid hemorrhage in young adults. *Journal of neurosurgery.* (98)1:43-49.
48. Poutasse, E.F. et al. (1954). POLYCYSTIC KIDNEY DISEASE AND INTRACRANIAL ANEURYSM. *Journal of the American Medical Association.* (154)9:741-744.
49. Proust, F. et al. (2001). Pediatric cerebral aneurysms. *Journal of neurosurgery.* (94)5:733-0739.
50. Proust, F. et al. (2001). Pediatric cerebral aneurysms. *Journal of neurosurgery.* (94)5:733-739.
51. Rao, V.R.K. and Mathuriya, S.N. (2011). Pediatric aneurysms and vein of Galen malformations. *Journal of Pediatric Neurosciences.* (6)1:109.
52. Reece, R.M. and Sege, R. (2000). Childhood Head Injuries Accidental or Inflicted?. *neurochirurgica.* (142)2:145-158.
53. Sanai, N. et al. (2006). Pediatric intracranial aneurysms: durability of treatment following microsurgical and endovascular management. *Journal of neurosurgery.* (104)2:82-89.
54. Schievink, W.I. et al. (1992). Saccular intracranial aneurysms in autosomal dominant polycystic kidney disease. *Journal of the American Society of Nephrology: JASN.* (3)1:88-95.
55. Sharma, B.S. et al. (2007). Pediatric intracranial aneurysms-clinical characteristics and outcome of surgical treatment. *Child's nervous system: ChNS: official journal of the International Society for Pediatric Neurosurgery.* (23)3:327-333.
56. Simpson, R.K. et al. (1988). Emergency balloon occlusion for massive epistaxis due to traumatic carotid-cavernous aneurysm. Case report. *Journal of neurosurgery.* (68)1:142-144.
57. Sorteberg, A. and Dahlberg, D. (2013). Intracranial Non-traumatic Aneurysms in Children and Adolescents. *Current Pediatric Reviews.* (9)4:343.
58. Sorteberg, A. and Dahlberg, D. (2013). Intracranial Non-traumatic Aneurysms in Children and Adolescents. *Current Pediatric Reviews.* (9)4:343.
59. Stiefel, M.F. et al. (2008). ENDOVASCULAR AND SURGICAL TREATMENT OF RUPTURED CEREBRAL ANEURYSMS IN PEDIATRIC PATIENTS. *Neurosurgery.* (63)5:859-866.
60. Strouse, J.J. et al. (2004). Risk Factors for Intracranial Hemorrhage in Children with Sickle Cell Anemia. *Blood.* (104)11:1657-1657.
61. Subarachnoid haemorrhage – NHS.
62. Subarachnoid Hemorrhage - UCLA Neurosurgery, Los Angeles, CA.
63. Thompson, J.R. et al. (2012). CEREBRAL ANEURYSMS IN CHILDREN. (118)1:163-175.
64. Turnpenny, P.D. and Ellard, S. (2012). Alagille syndrome: pathogenesis, diagnosis and management. *European journal of human genetics: EJHG.* (20)3:251-257.
65. Westra, D.L. and Colohan, A.R.T. (2008). Pediatric subarachnoid haemorrhage. *Acta Neurochirurgica, Supplementum.* (104)104:401-405.
66. Wilkes, D. et al. (2006). Inherited disposition to cardiac myxoma development. *Nature reviews. Cancer.* (6)2:157-165.
67. Wojtacha, M. et al. (2001). Cerebral aneurysms in childhood. *Child's nervous system: ChNS : official journal of the International Society for Pediatric Neurosurgery.* (17)1:37-41.
68. Xu, H.W. et al. (2011). Screening for intracranial aneurysm in 355 patients with autosomal dominant polycystic kidney disease. *Stroke.* (42)1:204-206.
69. Xu, R. et al. (2021). Epidemiology and outcomes of pediatric intracranial aneurysms: comparison with an adult population in a 30-year, prospective database. *Journal of Neurosurgery: Pediatrics.* (28)6:685-694.
70. Yang, M. et al. (2008). Management of intracranial aneurysm in children: clipped and coiled. *Child's Nervous System.* (24)9:1005.
71. Yokota, A. et al. (1987). Subarachnoid hemorrhage from brain tumors in childhood. *Child's nervous system: ChNS: official journal of the International Society for Pediatric Neurosurgery.* (3)2:65-69.
72. Yuan, S.M. and Wang, G.F. (2017). Cerebral mycotic aneurysm as a consequence of infective endocarditis: A literature review. (59)3:257-265.
73. Zheng, T. et al. (2014). Clinical features and endovascular treatment of intracranial arteriovenous malformations in pediatric patients. *Child's nervous system: ChNS: official journal of the International Society for Pediatric Neurosurgery.* (30)4:647-653.
74. Ziu, E. and Mesfin, F.B. (2021). Subarachnoid Hemorrhage. *StatPearls.*
75. 2009. Cerebral Vasospasm: New Strategies in Research and Treatment. *AJNR: American Journal of Neuroradiology.* (30)7:105.



This work is licensed under Creative Commons Attribution 4.0 License

To Submit Your Article Click Here:

Submit Manuscript

DOI: [10.31579/2642-9730/020](https://doi.org/10.31579/2642-9730/020)

Ready to submit your research? Choose Auctores and benefit from:

- fast, convenient online submission
- rigorous peer review by experienced research in your field
- rapid publication on acceptance
- authors retain copyrights
- unique DOI for all articles
- immediate, unrestricted online access

At Auctores, research is always in progress.

Learn more <https://www.auctoresonline.org/journals/brain-and-neurological-disorders>