

Cystectomy of Ovarian Borderline and Malignant Tumors for Fertility Sparing: Outcome of Seventeen Cases

Junko Wroblewski^{1,6}, Miyoko Takita¹, Haruka Eto¹, Rikiko Yamamichi¹, Tomoko Yoneda¹, Daisuke Nishi¹, Toshiaki Matsuura¹, Tomoyoshi Maruyama¹, Gregory Wroblewski², Seiya Kato³, Ayako Muta³, Shinsuke Sato³, Sakika Sanada⁴, Tomohiro Nakayama⁵, Daisuke Okamoto⁵ and Kunihiko Sakai¹.

¹Department of Obstetrics and Gynecology, Saiseikai Fukuoka General Hospital

²Faculty of Languages & Cultures, Kyushu University

³Department of Pathology, Saiseikai Fukuoka General Hospital

⁴Department of Pathology, Kurume University Faculty of Medicine

⁵Department of Radiology, Saiseikai Fukuoka General Hospital

⁶Department of Gynecology, Kyushu Central Hospital

Corresponding Author: Junko Wroblewski, Department of Obstetrics and Gynecology, Saiseikai Fukuoka General Hospital.

Received date: April 22, 2021; **Accepted date:** July 21, 2021; **Published date:** August 19, 2021

Citation: Wroblewski J. , Takita M. , Eto H. , Yamamichi R. , Yoneda T. , Nishi D. , Matsuura T. , Maruyama T. , Wroblewski G. , Kato S. , Muta A. , Sato S. , Sanada S. , Nakayama T. , Okamoto D. and Sakai K. (2021) Cystectomy of Ovarian Borderline and Malignant Tumors for Fertility Sparing: Outcome of Seventeen Cases. *J. Obstetrics Gynecology and Reproductive Sciences* 5(6) DOI:10.31579/2578-8965/079

Copyright: © 2021, Junko Wroblewski, This is an open access article distributed under the Creative Commons Attribution License, which permits unrestricted use, distribution, and reproduction in any medium, provided the original work is properly cited.

Abstract

Background: Here we present a retrospective study of 17 cases in which the ovary on the affected side was spared in fertility-sparing surgery (FSS) during treatment for ovarian borderline malignant or malignant tumor. We determine that cystectomy is a suitable treatment for ovarian borderline tumors.

Methods: A retrospective observation study was conducted at Saiseikai Fukuoka General Hospital in Japan between April 2009 and September 2020. Our hospital experienced 89 cases of FSS during treatment for ovarian borderline or malignant tumor. Of those, there were 17 cases in which the ovary on the affected side was spared. We examined recurrent and pregnant cases by stage, preoperative diagnosis, intraoperative pathological diagnosis, postoperative pathological diagnosis, and adjuvant therapy.

Result: Of the 17, 12 cases were borderline malignant tumor, 4 were immature teratoma grade 1 (G1), and 1 case was endometrioid adenocarcinoma G1. Rapid intraoperative pathological diagnosis was conducted in 9 of the cases, and there were 6 in which surgical method was chosen based on the aforementioned results. Laparoscopic surgery was performed in 2 cases in which tumors were deemed benign via preoperative diagnosis, 2 cases of mature teratoma, and 2 in which borderline ovarian tumor was suspected. One (1) case of paraovarian cystectomy in a patient with history of multiple cesarean sections turned out to be serous borderline tumor. Postoperative treatment took place in only 1 case: endometrioid adenocarcinoma. There were 2 cases of recurrence, and 4 cases were eventually able to become pregnant naturally post-surgery. These pregnant cases included 1 in which serous borderline tumor recurred and we performed both cystectomy and lymphadenectomy, and one in which chemotherapy was performed after cyst enucleation for endometrioid adenocarcinoma G1.

Conclusion: At present, there is no clear policy for FSS in cases such as stage Ib in which there are bilateral tumors. Accordingly, in the current study a radiologist was consulted for preoperative diagnosis, and surgical method was chosen with a view towards possible borderline malignancy or malignancy. In cases where fertility preservation of the affected ovary is a high priority, it is crucial to clearly explain the possibility of recurrence to the patient. We also stress the importance of detailed consultation among the surgical team during rapid intraoperational frozen section pathological examination for making the appropriate decision to ensure fertility preservation mid-surgery.

Key words: cystectomy; ovarian borderline tumors; fertility-sparing surgery (FSS)

Introduction

Ovarian borderline tumors (BTs) are defined as tumors displaying a histology that is intermediate between malignant and benign, and because of their relatively low malignancy, have a reputation as rarely if ever leading to death even in the event of recurrence after a long lapse. In Japan, there has been an increasing annual trend of such cases [1, 2]. The most common histological type are either serous, mucus, or serous mucous, and in Japan, mucus

and serous constitute 57.7% and 20.4% of cases, respectively. The standard surgical approach for early-stage ovarian cancer consists of bilateral salpingo-oophorectomy in a complete staging procedure also consisting of peritoneal washing cytology, peritoneal biopsy and omentectomy for the detection of any suspicious implants. In contrast to the standard approach, fertility sparing surgery (FSS) utilizes peritoneal biopsy and unilateral salpingo-oophorectomy in addition to the complete surgical staging mentioned above [3]. FSS has

been recommended for young women [3], but because bilateral onset of BTs is not uncommon and fertility sparing unilateral salpingo-oophorectomy and unilateral cystectomy are often selected, tumorigenesis on the remaining side often occurs. Malignant ovarian germ cell tumors are often young-onset, and fertility sparing must be considered in such cases accordingly. Furthermore, diagnosis of borderline malignant tumor or immature teratoma during preoperative examination is difficult, and there are many cases in which surgical method is based upon rapid intraoperational frozen section pathology mid-surgery. FSS is performed first, and the necessity of secondary radical operation is considered after postoperative permanent section diagnosis. In the current study, we review cases at our hospital where FSS was performed in borderline malignant and malignant tumor patients, including recurrences as well as patients who eventually became pregnant.

Materials and method

A retrospective investigation was performed on 17 cases of cystectomy in FSS for patients of ovarian borderline and malignant tumors at our hospital between the period April 2009 and September 2020. Age at preoperative diagnosis, surgical procedure performed, frozen section and postoperative diagnoses, tumor stage, treatment, follow-up, recurrence and pregnancy were all noted.

Results

General characteristics for the 17 cases surveyed can be seen in Table 1. Median age at primary treatment was 26.2 years (range 16-33 years), and 16 of 17 had no reproductive history. Median follow-up until recurrence was 13 months (range 8-20 months). Three (3) of 17 cases involved the right ovary, 5 involved the left, and 9 were bilateral (52.9%). Eight (8) of the 17 (47.1%) received laparoscopic surgery as primary treatment, and 6 of the 8 were judged benign during preoperative diagnosis. None of the 8 cases in the laparoscopic surgery group experienced recurrence (Table 2).

Characteristics	
Median age (range)	26.2 (16-33)
Reproductive history	
Yes	1 (5.9%)
No	16 (94.1%)
Follow up until recurrence, Median (range)	13 (8-20months)
Tumor site	
Right	3 (17.6%)
Left	5 (29.4%)
Bilateral	9 (52.9%)

Surgery	
Laparoscopic	8 (47.1%)
Laparotomy	9 (52.9%)
Preoperative diagnosis	
Benign	
Endometrial cyst	2 (11.8%)
Ovarian cystadenoma	3 (17.6%)
Mature teratoma	4 (23.5%)
Borderline malignant	6 (35.3%)
Malignant	2 (11.8%)
Pathology	
Serous borderline	5 (29.4%)
Mucinous borderline	2 (11.8%)
Seromucinous borderline	1 (5.9%)
Endometrioid adenocarcinoma G1	1 (5.9%)
Not available	8 (47.1%)
Postoperative diagnosis	
Serous borderline	5 (29.4%)
Mucinous borderline	4 (23.5%)
Seromucinous borderline	3 (17.6%)
Endometrioid adenocarcinoma G1	1 (5.9%)
Immature teratoma G1	4 (23.5%)
Stage	
Ia	2 (11.8%)
Ib	1 (5.9%)
Ic1	10 (58.9%)
Ic2	1 (5.9%)
Ic3	2 (11.8%)
IIc	1 (5.9%)
Adjuvant therapy	
	1 (5.9%)
Recurrence	
	2 (11.8%)
Pregnancy	
	4 (23.5%)

Table 1. . Patient demographics and clinical characteristics.

Table 2 displays the clinical characteristics for the 17 cases. Nine (9) were examined by frozen section pathology during surgery, and in 7 cases, surgical method was reconsidered based on frozen section diagnosis. Of those 7 cases, the frozen section diagnosis matched the permanent pathological diagnosis (postoperative diagnosis) (Table 2).

N0	Age	G/P	site	Preoperative diagnosis	cytology	Surgery	Stage	Frozen diagnosis	section	Postoperative diagnosis	Treatment	status	Total follow up (in months)
1	23	G0P0	Bil	endometrial cyst, ruptured	positive	BC	1c2	SBT		SBT	N	NED	135
2	16	G0P0	Rt	mature teratoma	-	TLRC	1c1	-		immature teraroma G1	N	NED	91
3	28	G0P0	Bil	BT	negative	LSO, RC, OMTx, AppDx	1c1	MBT		MBT	N	NED	81
4	26	G0P0	Bil	bilateral ovarian cancer	positive	RSO, LC Peritoneal resection	2c	MBT		MBT desmoplastic implant(+)	N	NED	80
5	22	G0P0	Bil	SBT or cancer	negative	RSO, LC	1c1	SBT		seromucinous borderline tumor	N	NED	65
6	33	G0P0	Bil	endometrial cyst, BT	positive	LSO, RC, OMTx, AppeDx, Peritoneal resection	1c3	endometrioid adenocarcinoma G1 with atypical endometrial hyperplasia		endometrioid adenocarcinoma G1 with atypical endometrial hyperplasia	Y GnRH antagonist +TC 6 cycles	NED	55
7	20	G0P0	Lt	mucinous cystadenoma	-	LC	1c1	-		MBT	N	NED	53
8	29	G0P0	Bil	seromucinous BT	negative	TLBC, OMTx	1c1	seromucinous BT		seromucinous BT	N	NED	37
9	26	G0P0	Bil	mature teratoma	-	TLBC	1c1	-		Lt: immature teraroma G1 Rt: mature teratoma	N	NED	26
10	28	G0P0	Lt	mucinous cystadenoma	-	TLLC	1c1	-		MBT	N	NED	25
11	19	G0P0	Rt	mature teratoma with torsion	-	TLRC	1c1	-		immature teraroma G1	N	NED	22
12	30	G0P0	Rt	BT	negative	TLRC	1a	SBT (minor component)		SBT(minor component)	N	NED	19
13	25	G0P0	Lt	mature teratoma with torsion	-	TLRC	1c1	-		immature teraroma G1	N	NED	19
14	29	G6P2	Lt	ovarian cyst	-	LC+(C/S)	1a	-		SBT	N	NED	13
15	32	G0P0	Lt	endometrial cyst	-	TLLC	1c1	-		seromucinous BT	N	NED	7
16	33	G0P0	Bil	mature teratoma or cancer suspected	negative	BC	1b	SBT		SBT	N	NED	6
17	26	G0P0	Bil	SBT, ruptured	positive	RSO, LC	1c3	Lt: BT Rt: necrotic BT with torsion		SBT	N	NED	2

Abbreviations

G gravity, P parity, Bil bilateral, Lt left, Rt right, BC bilateral cystectomy, LC left cystectomy, RC right cystectomy, LSO left salphingo-oophorectomy, RSO right salphingo-oophorectomy, TL translaparoscopsurgery, C/S caesarean section, OMTx omentectomy, AppeDx appendectomy, G1 grade 1, N no, Y yes, GnRH gonadotropin releasing hormone, T TC paclitaxel+carboplatin chemotherapy, NED no evidence of disease, BT borderline tumor, SBT serous borderline tumor, MBT mucinous borderline tumor

Table 1. . Characteristics for all 17 cases.

Table 3 shows clinical characteristics for the 2 cases of recurrence. Case 1 experienced recurrence on the right ovary with peritoneum dissemination for which frozen section pathology displayed serous borderline tumor. Right salphingo-oophorectomy and omentectomy along with peritoneum and lymph node dissection were performed. Permanent pathology diagnosis revealed noninvasive implants and no metastasis, and for this reason we declined follow-up treatment after surgery. Case 4 originally

displayed mucinous borderline tumor on both ovaries and desmoplastic implants. The patient experienced a recurrence on the left ovary eleven months later, and frozen section pathology revealed serous borderline tumor. We subsequently decided on left ovarian cystectomy only.

No	Primary tumor site	Surgery	Stage	Postoperative diagnosis	Adjuvant	Disease free after primary treatment (months)	Recurrence site	Second surgery	Frozen diagnosis of recurrent tumor	Diagnosis of recurrent tumor	Therapy after second surgery
1	Bil	BC	1c2	SBT	N	20	Rt ovary	RSO, OMTx, LNs & peritoneal resection	SBT	SBT non-invasive implant (+)	N
4	Bil	RSO, LC, Peritoneal resection	2c	MBT desmoplastic implant (+)	N	11	Lt ovary	LC	MBT	MBT	N

Abbreviations

Bil bilateral, Lt left, BC bilateral cystectomy, RSO Right saopingo-oophorectomy, LC left cystectomy, N no, OMTx omentectomy, LNs lymph nodes, BT borderline tumor, SBT serous borderline tumor, MBT mucinous borderline tumor

Table 3. Characteristics of the 2 recurrent cases.

No	Primary tumor site	Surgery	Stage	Postoperative diagnosis	Adjuvant	Disease free after primary treatment (months)	Recurrence site	Second surgery	Diagnosis of recurrent tumor	Therapy after second surgery	Pregnancy after surgery
1	Bil	BC	1c2	SBT	N	20	Rt ovary	RSO, OMTx LNs & Peritoneal resection	SBT non-invasive implant (+)	N	Y (naturally) Preg 38W TVD
6	Bil	RSO, LC	1c3	endometrioid adenocarcinoma G1	Y GnRH antagonist +TC 6 cycles						Y (naturally) Preg 36W C/S
9	Bil	TLBC	1c1	Lt: immature teratoma G1 Rt: mature teratoma	N						Y (naturally) Preg 6W
16	Bil	BC	1b	SBT	N						Y (naturally) Preg 15w

Abbreviations

Bil bilateral, BC bilateral cystectomy, RC right cystectomy, LSO left salphingo-oophorectomy, RSO right salphingo-oophorectomy, TL translaparoscopiesurgery, OMTx omentectomy, LNs lymphnodes, G1 grade 1, GnRH gonadotropin releasing hormone, TC paclitaxel+carboplatin chemotherapy, Preg pregnancy, C/S caesarean section, BT borderline tumor, SBT serous borderline tumor, MBT mucinous borderline tumor

Table 4. Characteristics of the 4 pregnant cases.

Of the 17 cases, 4 patients were able to become pregnant naturally without intervention. Table 4 shows the clinical characteristics for pregnant cases. Case 1 experienced recurrence twenty months after primary surgery but became pregnant fifty-five months after secondary surgery. Case 6 was bilateral ovarian cancer (endometrial adenocarcinoma G1). Preoperative diagnosis was borderline malignant tumor, but the patient strongly desired fertility preservation even after consultation concerning the high risk of recurrence and possibility of death. During surgery, the attending physician and pathologist reviewed frozen section diagnosis with a view towards ovary preservation. Our pathologist judged the left ovarian

cancer as more aggressive than the right and that the right ovarian endometrial adenocarcinoma G1 displayed a great deal of background hyperplasia. Subsequently, we decided upon right ovarian tumor cystectomy for fertility-sparing purposes. Following primary surgery, the patient was treated with 6 cycles (6 months) paclitaxel-carboplatine (PC) chemotherapy + gonadotropin-releasing hormone (GnRHa). Only three months after primary treatment, the patient became pregnant (Figure 1). Case 9 became pregnant twenty-four months after primary surgery, and case 16 did so six months after primary surgery.

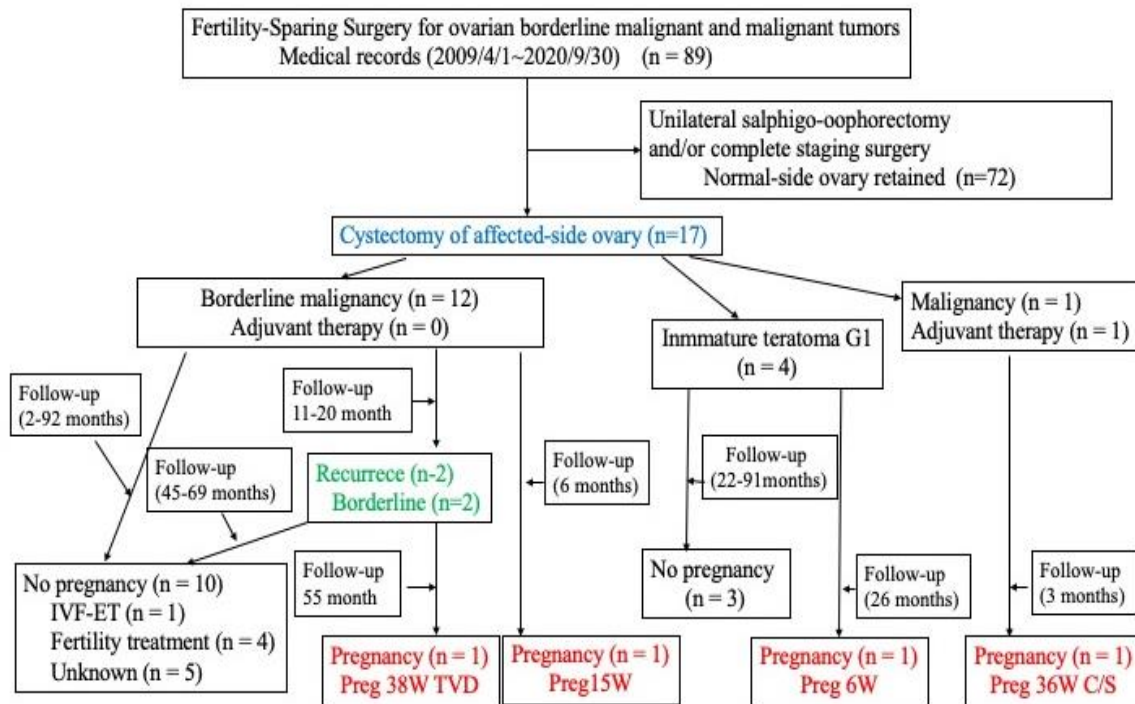


Figure 1. Flowchart of reproductive outcomes.

Discussion

In Japan, owing to a trend towards delayed marriage and pregnancy later in life, consideration of FSS in young patients with ovarian borderline malignant or malignant tumors is becoming increasingly important. Immature teratoma G1 has been classified by the WHO [4] as malignant and a two-tiered system has been adopted in which G1 is considered low-grade and G2 and G3 as high-grade [2,3,4,5]. For G1 stage 1, adjuvant chemotherapy is often prescribed [6], and salpingo-oophorectomy is suggested by the National Cancer Institute (2020) [7]. If postoperative diagnosis reveals immature teratoma G1 stage 1 after cystectomy in which preoperative diagnosis was mature teratoma, recurrence will likely not be discovered without resection of the affected ovary, and there is still no consensus on whether an additional salpingo-oophorectomy should be performed in the case of G3 stage 1[8,9]. In our case, when preoperative diagnosis was mature teratoma we performed cystectomy, and when it was immature teratoma G1, we continued close observation. According

to ESMO-ESGO guidelines[10], cystectomy of bilateral BTs is acceptable due to its insignificant effect on life prognosis, and recurring tumors are often borderline malignant. Because there are many cases of invasive cancers following the cystectomy of mucinous borderline tumors [6,11], salpingo-oophorectomy is recommended, and a standard surgical approach should be considered at the point when maintaining fertility is no longer the utmost priority. On the other hand, in the event of performing FSS for serous borderline tumor with invasive implant or residual tumor tissue, there are reports of recurrence of invasive cancer resulting in death[12]. Mid-surgery, peritoneal inspection, biopsy, and implant removal are necessary.

According to a Swedish national study [13], investigation of survival outcomes and long-term follow-up times reduces the risk of underestimating overall survival (OS) rates. In their particular cohort, the median time until death was 41 months (range 21-66), but BTs can appear up to 10 years later [6]. It has been mentioned by Xu et al [14] that close

follow-up is important due to the high recurrence rates many years post-diagnosis.

In the current study, for Case 4 stage 2c, we conducted a peritoneal examination and subsequent biopsy and dissection. We have yet to perform adjuvant chemotherapy because it was a non-invasive implant, and there has yet to be a recurrence despite 80 months having passed at time of press. Case 1 recurred 20 months after primary surgery, and we performed salpingo-oophorectomy and omentectomy, as well as lymph node and peritoneal dissection. After 55 months passed, she was able to become pregnant naturally. For Case 6, BTs were suspected during preoperative examination, with FSS strongly desired after lengthy discussion with the patient and family members. We decided that even if frozen section pathology showed malignancy, we would first perform FSS, and if the permanent section pathology results came back malignant, we would then consider secondary surgery. Consequently, even though it was endometrioid adenocarcinoma G1, FSS was performed. Mid-surgery, the pathologist was consulted for determination on which tissue appeared more aggressive and/or which side could be saved, and cystectomy was performed on the right ovary. Even though post-surgical diagnosis was endometrioid adenocarcinoma G1, because the main part was atypical hyperplasia, the patient declined additional surgery. We then administered adjuvant chemotherapy, with 6 cycles of paclitaxel+carboplatin (TC therapy). To prevent chemotherapy-induced premature ovarian failure (POF), we used gonadotropin-releasing hormone antagonist (GnRHa) during chemotherapy, and 3 months post-chemotherapy the patient became pregnant. For endometrioid borderline cases, the 5-year recurrence-free survival rate is significantly higher in cases of salpingo-oophorectomy than cystectomy[15]. Despite administration of chemotherapy, close follow-up will be necessary and possibly necessitate radical surgery later.

In the current study, the recurrence rate (11.8%) was somewhat high but similar to previous published reports in which FSS was performed [13,16,17]. The pregnancy rate of 23.5% (4/17) was also consistent with previous reports [13,16]. Four (4) patients became pregnant naturally (Figure 1), with 13 yet to do so and 5 patients currently in fertility treatment. Concerning the use of GnRHa to protect from chemotherapy-induced POF, there have been a mixture of positive and negative reports in the literature [18,19,20]. Recently Demeestere I et al [21] suggested that there is no evidence for the benefit of GnRHa in preserving ovarian function and fertility. In case 7, we were not sure that GnRHa worked against POF, but after first menstruation following chemotherapy, she surprisingly became pregnant.

The current study is a retrospective examination of affected-ovary cystectomy, and the number of cases is admittedly limited. Nevertheless, here we highlight the importance of conducting joint discussion with pathologists, and in cases of suspected borderline malignancy or malignancy following review of preoperative diagnostic imaging and clinical findings, we perform laparotomy whenever possible and submit frozen section pathology mid-surgery. Even mid-surgery, we exchange detailed information with pathologists concerning laparoscopic findings and pathology when deciding upon a subsequent surgical approach. Radiologists, gynecologists, and pathologists also consult post-surgery, confirming a final diagnosis and deciding upon next course of action treatment-wise. With such a backdrop of cooperation and support, treatment featuring cystectomy in FSS will no doubt continue at our institution. While cases to present have consisted mainly of relatively short-term follow-up necessitating long-term follow-up in the future, we

hope to hone treatment featuring cystectomy in FSS at our institution going forward.

Conflict of Interest

Statement: Authors declare there are no conflicts of interest associated with this manuscript.

Patient Consent:

This manuscript was deemed exempt from Saiseikai Fukuoka General Hospital Review Board.

Financial Disclaimer: None.

Author Contributions:

All authors were substantially involved in the acquisition of case report data, contributing to drafting of the manuscript, and critically revising the manuscript for important intellectual content.

Reference

1. Japan Society Obstetrics and Gynecology Gynecology committee. Annual report. *Acta Obstetrica et Gynaecologica Japonica.* (2018) ;70: 1372-1444.
2. Japan Society Obstetrics and Gynecology Gynecology committee. Annual report. *Acta Obstetrica et Gynaecologica Japonica.*(2019); 71: 702-719.
3. Guidelines for treatment of ovarian cancer, fallopian tube cancer and primary peritoneal cancer: Japan Society Obstetrics and Gynecology Gynecologic Oncology. (2020)edition.
4. Kurman RJ, Carcahgiu ML, Herrington CS, Yong RHE. WHO classification of Tumors of Female Reproductive Organs, 4th edition. Lyon:IARC 2014.
5. O'Connor DM, Norris HJ. (1994) The influence of grade on the outcome of stage I ovarian Immature (malignant) teratomas and reproductibility of grading. *Int J Gynecol Pathol.*;13:283-289.
6. Gershenson DM.(2007) Management of ovarian germ cell tumors. *J Clin Oncol* ;25:2938-2943.
7. NCI ovarian germ cell tumors treatment (PDQ) Health professional Version.
8. Cushing B, GillerR, Albin A, Cohen L, Cullen J,Hawkins E,et al.(1999) Surgical resection alone is effective treatment for ovarian immature teratoma in children and adolescents: a report of the pediatric oncology group and the children's cancer group. *Am J Obst Gynecol*; 181:353-358.
9. Marina NM, Cushing B, Giller R, Cohen L, Lauer SJ, Ablin A et al. (1999) Complete surgical excision is effective treatment for children with immature teratomas with malignant elements: A Pediatric Oncology Group Intergroup Study. *J Clin Oncol*;17:2137-2143.
10. ESMO-ESGO Ovarian Cancer Consensus Conference Working Group. ESMO-ESGO consensus conference recommendations on ovarian cancer; Pathology and molecular biology, early and advanced stage, borderline tumors and recurrent disease. *Ann Oncol* (2019);30(5):672-705.
11. Uzan C, Kikpayam M, Ribassin-Majed L, Gouy S, Bendifallah S,Cortez A. et al.(2014) Influence of histological subtypes on the risk of an invasive recurrence in a large series of stage I borderline ovarian tumor including 191 conservative treatments. *Ann Oncol*;25:1312-1319.
12. Du Bois A, Ewald-Riegler N, de Gregorio N, Reuss A, Mahner S, Fotopoulpu C. et al. Borderline tumors of the ovary:A cohort study of the Arbeitsgemeinschaft Gynakologische Onkologie (AGO) Study Grou18p. *Eur J Cancer* 2013;49:1905-1914.

13. Johansen G, Dahm-Kahler P, Staf C, Floter RA, Rodriguez-Wallberg KA. (2020) Productive and obstetrical outcomes with the overall survival of fertile-age women treat with fertility-sparing surgery for borderline ovarian tumors in Sweden: A prospective nationwide population based study. *Fertil Steril*; Sep 22; S0015-0282
14. Mengwei Xu, Bowei Wanf, Yonghua Shi. (2020) Bordrlne tumor in the pediatric and adolescent population: A clinopathologic analysis of fourteen cases. *Int J Clin Exp Pathol*;13(5):1053-1059.
15. Jia SZ, Zhang JJ, Liang ZY, Yang JJ, Xiang Y, Jia CW, Leng JH.(2018) Safety and fertility outcomes after the conservative treatment of endometrioid borderline ovarian tumors.*BMC Cancer*;18:1160.
16. Chevrot A, Pouget N, Bats AS, Huchon A, Guyon F, Chopin N, et al .(2020) Fertility and prognosis of borderline ovarian tumor after conservative management: Rwsult of the multicentric OPTIBOT study the GINECO & TMRG group. *Gynecol Oncol*;157:29-35.
17. Satoh T, Hatae M, Watanabe Y, Yaegashi N, Ishiko O, Kodama S.et al.(2010) Outcome of fertility-sparing surgery for stage I epithelial ovarian cancer: A proposal for patient selection. *J Clin Oncol*; 28(10):1727-1732.
18. Blumenfeld Z, Patel B, Leiba R, Zuckerman T. (2012)Gonadotropin-releasing hormone agonist may minimize premature ovarian failure in young women undergoing autologous stem cell autologous stem cell transolantation. *Fertil Steril*;98:1266-1270.
19. Demeestere I, Breice P, Peccatori FA,(2013). Gonadotropin-releasing hormone agonist for the prevention of chemotherapy-induced ovarian failuar in patients with lymphoma:1 year follow up of prospective randomized trial. *J Clin Oncol*;31:903-909.
20. Lambertini M, Boni I, MichelottiA,(2015) GIM Study Group. Ovarian suppression with triprorelin during adjuvant breast cancer chemotherapy and long-term ovarian function, pregnancies, and disease-free survival: A randomized clinical trial. *JAMA*.;314:2632-40.
21. Demeestere I, Brice P, Peccatori FA, Kentos A, Dupuis J, Zachee. P et al(2016). No evidence for the benefit of gonadotropin-releasing hormone agonist in preserving ovarian function and fertility in lymphoma survivors treated with chemotherapy: Final long-term report of a prospective randomized trial. *J Clin Oncol*;34(22):2565-2574



This work is licensed under Creative Commons Attribution 4.0 License

To Submit Your Article Click Here: [Submit Manuscript](#)

DOI: [10.31579/2692-9406/069](https://doi.org/10.31579/2692-9406/069)

Ready to submit your research? Choose Auctores and benefit from:

- ❖ fast, convenient online submission
- ❖ rigorous peer review by experienced research in your field
- ❖ rapid publication on acceptance
- ❖ authors retain copyrights
- ❖ unique DOI for all articles
- ❖ immediate, unrestricted online access

At Auctores, research is always in progress.

Learn more www.auctoresonline.org/journals/obstetrics-gynecology-and-reproductive-sciences