

Bilobed Odontogenic Pterygoid Abscess Masquerading as Malignancy

Jeanie Sozansky Lujan^{1,2}, Eve Tranchito^{3*}, Nipun Chhabra^{1,2,4}

¹Case Western Reserve University Department of Otolaryngology, Cleveland, OH, USA.

²University Hospitals Ear, Nose & Throat Institute, Cleveland, OH, USA.

³Northeast Ohio Medical University, Rootstown, OH, USA.

⁴Louis Stokes Cleveland VA Medical Center, Cleveland, OH, USA.

*Corresponding Author: Eve Tranchito, Northeast Ohio Medical University, Rootstown, OH, USA. E-mail: etranchito@neomed.edu

Received Date: November 26, 2019; Accepted Date: December 23, 2019; Published Date: December 30, 2019.

Citation: Jeanie Sozansky Lujan, Eve Tranchito, Nipun Chhabra. Bilobed Odontogenic Pterygoid Abscess Masquerading as Malignancy, Journal of Clinical Otorhinolaryngology, 1(1): Doi: [10.31579/2692-9562/001](https://doi.org/10.31579/2692-9562/001).

Copyright: © 2019 Eve Tranchito, This is an open-access article distributed under the terms of the Creative Commons Attribution License, which permits unrestricted use, distribution, and reproduction in any medium, provided the original author and source are credited.

Abstract

Pterygoid abscess from dental origin has been established. These abscesses can masquerade as malignancy. Various approaches to drainage have been described with specific nuances. We present an effective and safe transoral technique for drainage of a large, odontogenic intra-pterygoid muscle abscess.

Key words: pterygoid abscess; dental origin; malignancy

Introduction

The infratemporal fossa is a potential space shaped like an inverted pyramid. It is bounded superiorly by the greater wing of the sphenoid, inferiorly by the medial pterygoid muscle, anteriorly by the posterior wall of the maxillary sinus, posteriorly by the temporal bone and styloid process, laterally by the ramus of the mandible, and medially by the lateral pterygoid plate [1, 2]. Up to 1% of benign and malignant tumors can arise in this area [3]. Abscesses most commonly extend to this space from a dental origin [4]. While a variety of approaches exist to drain abscesses here, no consensus exists on the optimal procedure. We present a rare case of an infratemporal infection involving the lateral pterygoid muscle that was initially misdiagnosed as malignancy.

Case report

A 94-year-old gentleman without significant tobacco or alcohol usage presented with two months of right-sided jaw pain, lip, and chin numbness. He underwent dental extraction of tooth #29 and 30 with subsequent poor wound healing and persistent symptoms. Exam demonstrated a firm perifacial mass, oropharyngeal erythema, moderate trismus, and right lower facial hypoesthesia. Contrasted CT revealed a 4 x 3 cm heterogenous and bilobed mass replacing the right lateral pterygoid muscle with extensive erosion of the hemi-mandible, subperiosteal inflammation, and proximal lymphadenopathy (Fig 1, 2). A PET scan showed significant hypermetabolism of the right parapharyngeal space which was concerning for malignancy (Fig 1).

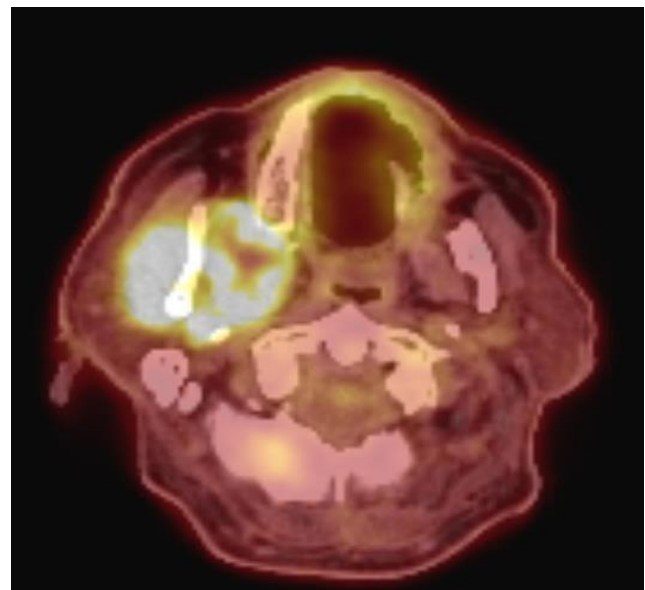
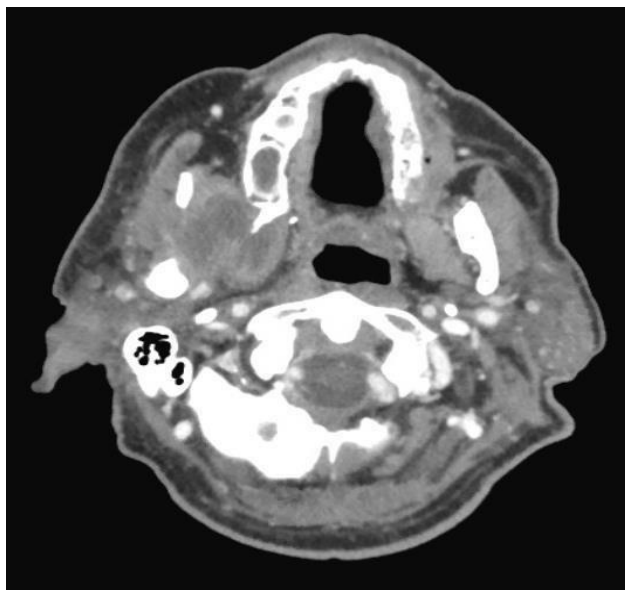


Fig 1: A) Axial CT demonstrates enhancement within the right pterygoid musculature
B) PET avid uptake concerning for neoplasm

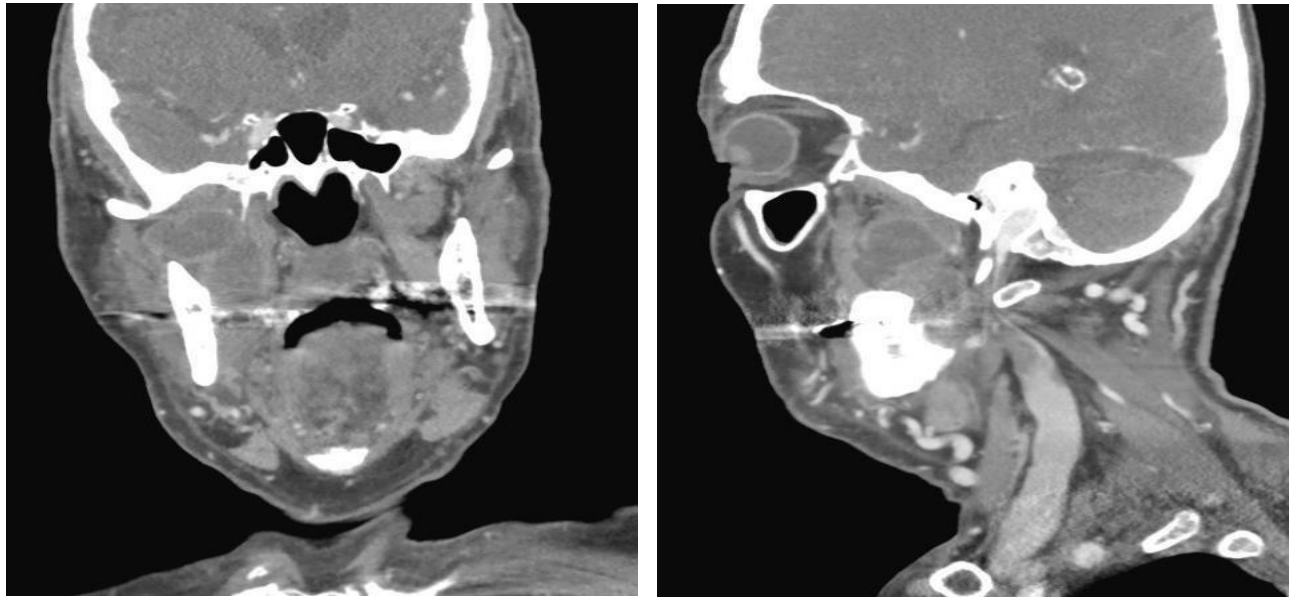


Fig 2: A) Coronal CT shows a bilobed infratemporal fossa mass
B) Boundaries of the infratemporal fossa and extent of the abscess on sagittal section

The patient was taken to the operating room for formal exploration. The hamulus and ascending mandibular ramus were used to localize placement of an incision approximately 1 cm superior to the right retromolar trigone and in an area of fullness medial to the vertical ramus. Blunt dissection was performed until the pterygoid musculature and tendons were identified and probed. A copious amount of purulence was released and the muscle layers were separated until the large multiloculated abscess cavity was visualized. A passive drain was placed and the mucosa was reapproximated. Biopsies showed inflammation and necrosis without evidence of malignancy. He was treated with appropriate culture-directed antibiotic therapy and made a full recovery.

Discussion

In this case a large lateral pterygoid intramuscular abscess arose from a dental infection, which is the most common etiology [1]. Other sources that may spread to the infratemporal fossa include maxillary sinusitis, facial fractures, and malignant otitis externa [1]. The close proximity to the orbit, pterygopalatine fossa, skull base, and deep neck space mandates prompt treatment. Trismus is a hallmark sign of abscesses due to pterygoid muscle inflammation and was present in this case [4]. The patient's hypoesthesia in the V3 distribution was likely related to local inflammation of the infratemporal foramen. The infection was initially thought to be a malignancy because of its chronicity and appearance on imaging. A variety of approaches exist to access infections within the infratemporal fossa including periauricular, transtemporal, transnasal, and transoral [1]. Amongst these approaches, the transoral, infratemporal approach affords the least morbidity with quick healing, greatest safety with blunt dissection, shortest operating time with efficient localization, limited need for specialized equipment, and optimal post-surgical gravity

drainage with ease of wound maintenance.

Conclusion

Pterygoid abscesses can be mistaken for malignancy in certain cases. The transoral approach is an efficient and safe method for drainage and incorporates the initial source of infection for complete extirpation.

Acknowledgement

The authors have no relevant funding, financial relationships, or conflicts of interest to disclose

Declarations of interest: None

References

1. Varshney R, Zawawi F, Tewfik MA. (2013). Endoscopic Drainage of an Odontogenic Pterygoid Muscle Abscess. *Case Reports in Otolaryngology*.215793.
2. Sundaram SS, Rajan P, Balasubramanian A. (2014). Endoscopic transmaxillary drainage of an infratemporal fossa abscess. *BMJ Case Rep.*; bcr-2013-200637.
3. Robinson S, Patel N, Wormald PJ. (2005). Endoscopic management of benign tumors extending into the infratemporal fossa: a two-surgeon transnasal approach. *Laryngoscope*. 115(10 I):1818–1822.
4. Kamath MP, Bhojwani KM, Mahale A, Meyyappan H, Abhijit K. (2009). Infratemporal fossa abscess: a diagnostic dilemma. *Ear, Nose and Throat Journal*. 88(5):p. E23.