

Spinal Cord Constriction Secondary to Scaphoid Nonunions

Samuel Langhorne

Department of Psychological Medicine, USA.

***Corresponding Author :** Samuel Langhorne, Department of Psychological Medicine, USA. E-mail: langhorne_samuel32@gmail.edu**Received date:** September 07,2017;**Accepted date :** September 15,2017; **Published date:** September 27,2017.**Citation for this Article:** Samuel Langhorne. Spinal Cord Constriction Secondary to Scaphoid Nonunions . J Psychology and Mental Health Care . Doi: 10.31579/2637-8892/018**Copyright :** © 2017 Samuel Langhorne. This is an open-access article distributed under the terms of The Creative Commons Attribution License, which permits unrestricted use, distribution, and reproduction in any medium, provided the original author and source are credited.**Keywords:** Spinal Cord Compression; Hardware.

A 57 year old female with history of diabetes mellitus, diabetic peripheral neuropathy and scoliosis with four previous spinal fusions (T4 to pelvis) presented with worsening ambulating for the past one month. She was previously at baseline ambulating with a walker. Her physical exam demonstrated normal cranial nerve functions. Motor exam revealed full strength in bilateral upper extremities, 3+/5 MRC strength in bilateral hip flexors, 5-/5 MRC in bilateral hip abductors, adductors, knee flexors/extensors, and ankle dorsiflexors/plantar flexors, with increased muscle tone in the lower extremities. Sensory exam revealed decreased sensation to pinprick below T6 level. Deep tendon reflexes were 2+ symmetric in upper extremities as well as at the knees and 4+ at ankles with non-sustained clonus. A positive Babinski's sign was elicited bilaterally. A CT thoracic spine revealed the pedicle screws traversing the disc space at the T3-4 level, with the deformity associated with moderate to severe central stenosis (Figure 1).

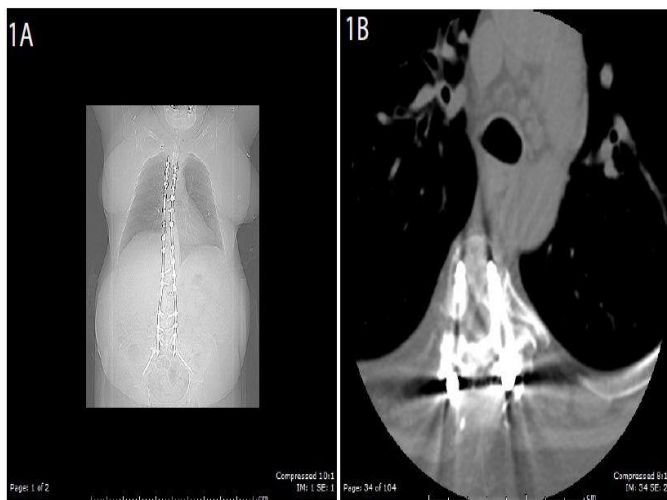


Figure 1: CT thoracic spine (coronal view figure 1a and axial view figure 1b) revealing pedicle screws traversing the disc space at the T3-4 level. Figure 1b reveals the surgical screw causing moderate to severe central stenosis.

Due to the severe spinal cord compression at the T3 to T4 level, she underwent another surgery – T4 to T12 segmental spinal instrumentation removal, a T4 vertebral column resection and a T3 to T10 fusion. She tolerated the procedure well and the strength in her lower extremities improved before discharge in one week. A follow up visit at three months after the surgery showed stable strength in her lower extremities. A repeat CT thoracic spine revealed the resolved cord compression at T3-4 level (Figure 2).

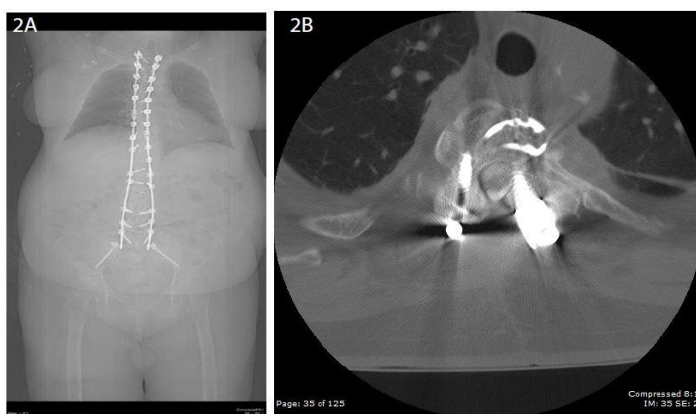


Figure 2: Three month follow up CT thoracic spine (coronal view figure 2a and axial view figure 2b) revealing resolving of moderate to severe central stenosis at the T3-4 level.

Spinal cord compression due to external fixation abnormalities is a rare but important potential adverse event in patients who have had previous fusion surgeries. Major spinal surgery is associated with a high incidence of intra- and postoperative complications. Although instrumentation failure is reportedly lower, the potential for permanent and/or long term sequelae is concerning [1,2]. To our knowledge the extent to which our patient's hardware traversed the disc space is previously unreported.

References

1. Amankulor NM, Xu R, Iorgulescu JB, Chapman T, Reiner AS, et al. (2013) The incidence and patterns of hardware failure after separation surgery in patients with spinal metastatic tumors. *Spine J* 14: 1850-1859.
2. Street JT, Lenehan BJ, DiPaola CP, Boyd MD, Kwon BK, et al. (2012) Morbidity and mortality of major adult spinal surgery. A prospective cohort analysis of 942 consecutive patients. *Spine J* 12: 22-34.