

Incidental Finding of Unilateral Parotid Gland Agenesis: A Case Report

Tyler J. Hagler¹, Andrew C. Jenzer^{2*}, Joseph W. Ivory³, Jai-ik Cho⁴

¹PGY-3 Resident Department of Oral and Maxillofacial Surgery Eisenhower Army Medical Center Fort Gordon, GA 30905

²Residency Assistant Program Director Department of Oral and Maxillofacial Surgery Eisenhower Army Medical Center Fort Gordon, GA 30905

³Residency Program Director Department of Oral and Maxillofacial Surgery Eisenhower Army Medical Center Fort Gordon, GA 30905

⁴PGY-4 OMS Resident Department of Oral and Maxillofacial Surgery Eisenhower Army Medical Center Fort Gordon, GA, 30905

***Corresponding Author:** Andrew C. Jenzer, Residency Assistant Program Director Department of Oral and Maxillofacial Surgery Eisenhower Army Medical Center Fort Gordon, GA 30905

Received Date: February 10, 2021; Accepted Date: June 11, 2021; Published Date: June 16, 2021

Citation: Tyler J. Hagler, Andrew C. Jenzer, Joseph W. Ivory, Jai-ik Cho, (2021) Incidental Finding of Unilateral Parotid Gland Agenesis: A Case Report. *J. General medicine and Clinical Practice*, 4(1); **Doi:10.31579/2639-4162/046**

Copyright: © 2021 Andrew C. Jenzer, This is an open-access article distributed under the terms of the Creative Commons Attribution License, which permits unrestricted use, distribution, and reproduction in any medium, provided the original author and source are credited.

Abstract

A 34-year-old male active duty soldier presented to the Dwight David Eisenhower Army Medical Center (DDEAMC) Oral and Maxillofacial Surgery Clinic on referral from a local General Dental Clinic for a reported history of temporomandibular joint painful popping and clicking, favoring the right side. As a component of the patient's outpatient clinical workup, an MRI of the bilateral temporomandibular joints was ordered with an incidental finding noted of partial-to-complete absence of the left parotid gland. The patient completed a conservative therapy regimen and subsequently underwent a non-arthroscopic lysis and lavage of the right temporomandibular joint with resolution of the index symptoms.

Key words: maxillofacial surgery; maximal interocclusal opening

CASE REPORT:

A 34-year-old male active duty soldier was referred to the DDEAMC Oral and Maxillofacial Surgery Clinic for evaluation and treatment of temporomandibular joint pain favoring the right side. The patient had a non-contributory past medical history with a reported allergy to sulfa based medications. His surgical history was notable for septoplasty and a vasectomy with subsequent reversal. On initial evaluation, the patient reported frequent, painful clicking and popping of the right temporomandibular joint. These symptoms were described as progressive in nature over the preceding three years.

On clinical examination, the patient was found to have a stable occlusion in a good state of repair with missing teeth #1, 16, 17, and 32. Bilateral temporomandibular joint pain was appreciated on opening, to include reciprocal popping and clicking observed on the right side. Maximal Interocclusal Opening (MIO) was noted to be approximately 37 millimeters without pain. No deviation of the mandible was noted and occlusal range of motion was found to be repeatable. The patient denied tenderness on palpation of the bilateral muscles of mastication. A Mahan Test was performed at chairside with negative findings.

A series of existing dental plain film radiographs and a panoramic image were all reviewed with unremarkable findings. At the conclusion of the initial evaluation, the patient was provided instructions on conservative therapy measures to include soft diet modification, application of warm compresses to the affected areas, stretching exercises, and the use of as-needed non-steroidal anti-inflammatory (NSAIDS) medications. In addition, an MRI of the temporomandibular joints was ordered to facilitate final diagnosis of the patient's suspected internal derangement of the right joint.

A Multiplan Multisequence Image (MRI) of the bilateral temporomandibular joints was completed without intravenous contrast. The study was reviewed by a radiologist and the oral surgery team. There was no evidence of focal abnormalities involving the left disc tissue, though subtle anterior displacement of the left discal tissue was noted. The right disc was found to be of appropriate morphology and appreciated in the appropriate position on both opening and closing. An incidental finding of missing left parotid gland tissue was noted with fatty tissue in the expected anatomical position (**Figures 1, 2, 3**).

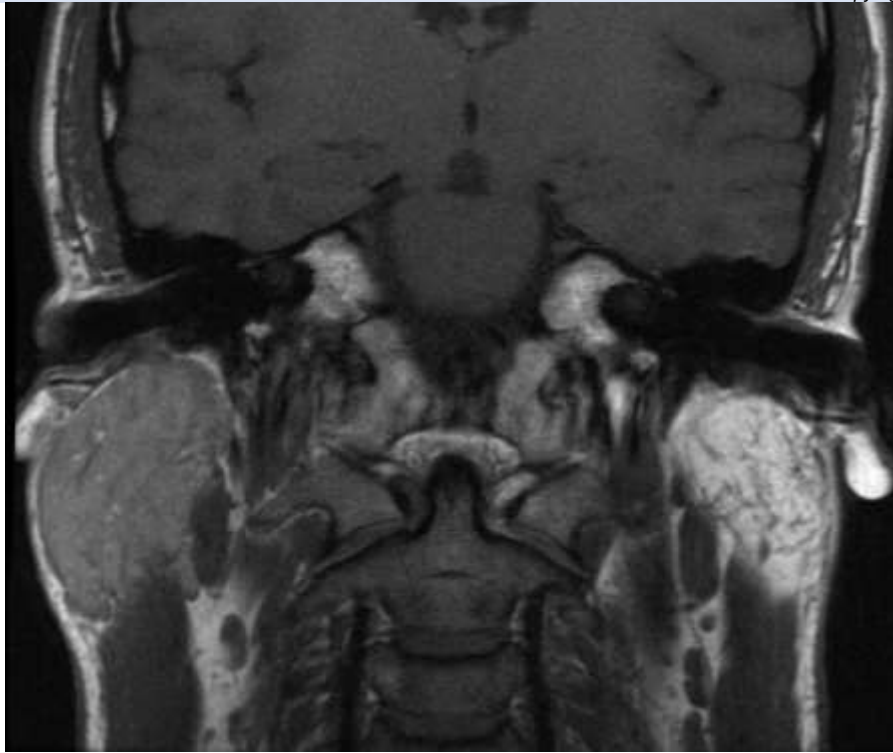


Figure 1: MRI coronal slice demonstrating normal right parotid gland and missing left gland

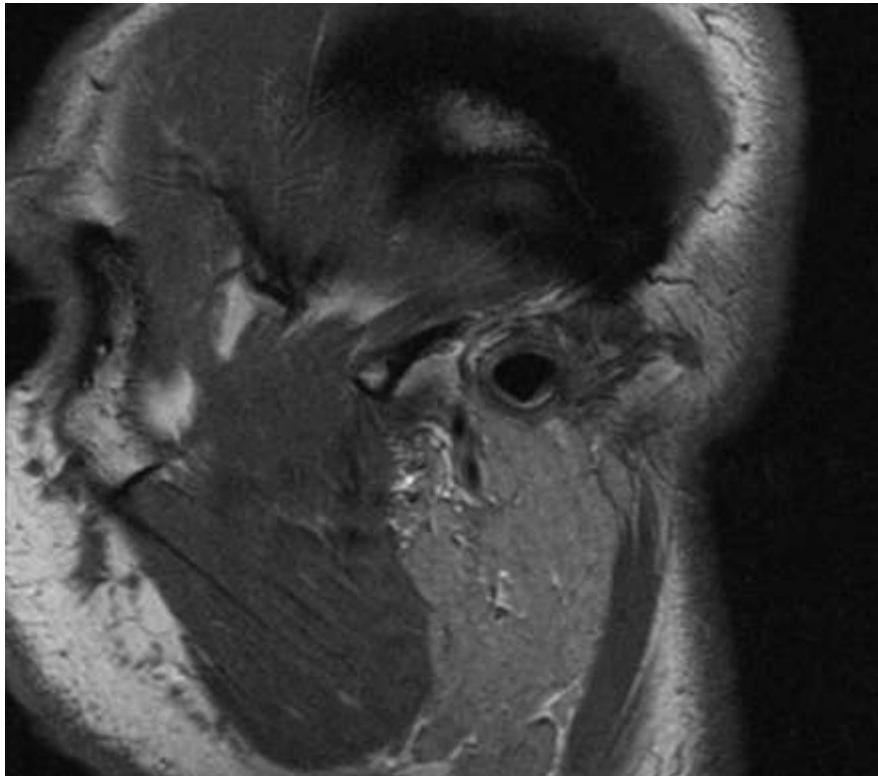


Figure 2: MRI sagittal slice demonstrating normal right parotid gland

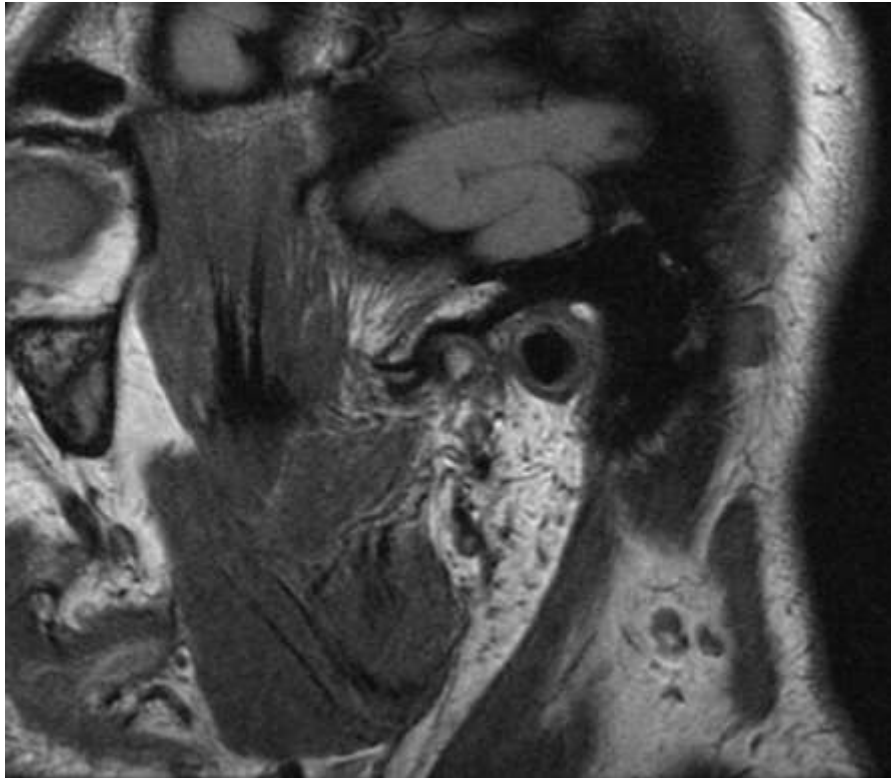


Figure 3: MRI sagittal slice demonstrating missing left parotid gland and associated soft tissues

The right parotid gland was observed and found to be unremarkable. Formal review by the radiologist highlighted the unusual nature of this findings and indicated that absence of the left parotid gland is likely congenital with the observed overlying soft tissue structures representing a rudimentary gland.

The patient was re-evaluated and diagnosed with Anterior Disc Displacement (ADD) with Reduction of the Right Temporomandibular Joint with examination findings consistent with a Wilkes Stage II disease classification. The patient denied any benefit from conservative therapy measures and elected to pursue surgical options given the continued pain and reported impact on daily quality of life. The patient was consented for non-Arthroscopic lysis and lavage of the right temporomandibular joint with placement of medications into the joint and manipulation under anesthesia. The procedure was completed without complication, as an outpatient in operating room setting, under general anesthesia. Therapeutics included intra-articular administration of both Kenalog and Hyaluronic Acid. The patient was seen on follow-up and reported satisfaction with the procedure with an improvement in symptom severity and frequency. No additional procedures were discussed and the patient remains on as-needed recall with Oral and Maxillofacial Surgery Service.

DISCUSSION:

Incidental discovery of missing salivary glands, commonly known as agenesis of the salivary glands, represents an exceedingly rare phenomenon.[1,2] In particular, congenital agenesis of the parotid gland has been described in the literature with both unilateral, bilateral, and presentations involving multiple other major salivary glands. [7,8,9,10]

There have been cases reported with syndromic associations such as hemifacial microsomia, cleft palate, Levy-Hollister Syndrome, but also single cases Klinefelter Syndrome and Down Syndrome. [3,13]

This condition is frequently described as asymptomatic in nature and this case represents a new asymptomatic, incidental discovery on routine imaging for an unrelated condition. [11] Symptomatic patients can experience xerostomia leading to a higher incidence of dental caries and possible facial asymmetry. The precise incidence of unilateral congenital parotid gland agenesis is difficult to ascertain and less than 30 cases have been reported in the literature to date. [1-6] There does not appear to be a gender predilection and a wide range of ages have been reported on discovery. Of note, unilateral agenesis of the right parotid gland has been reported more than twice as frequently as unilateral agenesis of the left side. [9,11,12]

In many of the reported cases, authors have described hypertrophy of the contralateral parotid gland thought to be secondary to a compensatory function. This present case did not demonstrate any gross evidence of contralateral hypertrophy. Additional modalities such as salivary function scintigraphy and computed tomography may be useful to better appreciate the presence of any accessory parotid tissue as well as the general status of the duct system in this patient.

Given the asymptomatic nature of the present case, the patient was informed of the findings and no further workup was indicated. This case is limited in that the authors were unable to classify this patient into any known maxillofacial syndromes or combination presentations.

DISCLAIMER:

The views expressed herein are those of the authors and do not reflect the official policy of the Department of the Army, Department of Defense, or the United States Government.

DISCLOSURE:

None of the authors reported any disclosures.

REFERENCES:

1. Bakir S, Gumus H, Varolgunes A, Meric F. Unilateral absence of the parotid gland: a rare disorder. *Journal of Clinical and Experimental Investigations*. 2011;2(1):88-90.
2. Daniel SJ, Blaser S, Forte V. Unilateral agenesis of the parotid gland: an unusual entity. *International Journal of Pediatric Otorhinolaryngology*. 2003;67:395-397.
3. Martin-Granizo R, Garca-Gonzalez D. Unilateral agenesis of the parotid gland: a case report. *Oral Surgery, Oral Medicine, Oral Pathology, Oral Radiology, and Endodontics*. 2004;98:712-714.
4. Teymoortash A, Hoch S. Congenital unilateral agenesis of the parotid gland: A case report and review of the literature. *Case Reports in Dentistry*. 2016 2672496.
5. Higley MJ, Walkiewicz TW, Miller JH, Curran JG, Towbin RB. Aplasia of the parotid glands with accessory parotid tissue. *Pediatric Radiology*. 2010;40(3):345-347.
6. Sasankoti Mohan RP, Verma S, Tyagi K. Non-syndromic non-familial agenesis of major salivary glands: a report of two cases with review of literature. *Journal of Clinical Imaging Science*. 2013;3(Suppl 1):2.
7. Gulati V, Mirza A, Gulati P. An unusual case with a missing parotid gland: a case report. *Indian Journal of Radiology and Imaging*. 2020 Apr-Jun;30(2):237-239.
8. Maithani T, Pandey A, Acharya S. Congenital agenesis of unilateral parotid gland with ipsilateral type 1 first branchial cleft anomaly: a rare presentation. *Egyptian Journal of Ear, Nose, Throat and Allied Sciences*. 2014;15(1):53-56.
9. Seith AB, Gadodia A, Sharma R, Parshad R. Unilateral parotid agenesis associated with pleomorphic adenoma of ipsilateral accessory parotid gland. *Ear, Nose & Throat Journal*. 2013;92(1):E13-15.
10. Togni L, Mascitti M, Santarelli A, Contaldo M, Romano A, Serpico R, Rubini C. Unusual conditions impairing saliva secretion: developmental abnormalities of salivary glands. *Frontiers in Physiology*. 2019;10:855.
11. D'Ascanio L, Cavuto C, Martinelli M, Salvinelli F. Radiological evaluation of major salivary glands agenesis: a case report. *Minerva Stomatologica*. 2006;55(4):223-228.
12. Berta E, Bettega G, Jouk PS, Billy G, Nugues F, Morand B. Complete agenesis of major salivary glands. *International Journal of Pediatric Otorhinolaryngology*. 2013;77(10):1782-1785.
13. Yavuz Fuat Yilmaz, Ali Titiz, et al. Congenital bilateral parotid gland agenesis in Klinefelter syndrome. *Journal of Cranio-Maxillo-Facial Surgery*, 2010-06-01, 38-4: 248-250



This work is licensed under Creative Commons Attribution 4.0 License

To Submit Your Article Click Here: [Submit Manuscript](#)

DOI:10.31579/2639-4162/046

Ready to submit your research? Choose Auctores and benefit from:

- ❖ fast, convenient online submission
- ❖ rigorous peer review by experienced research in your field
- ❖ rapid publication on acceptance
- ❖ authors retain copyrights
- ❖ unique DOI for all articles
- ❖ immediate, unrestricted online access

At Auctores, research is always in progress.

Learn more <https://www.auctoresonline.org/journals/general-medicine-and-clinical-practice>