

Homeopathic Medicines in the Early Treatment of Acne Preventing Formation of Acne Scar

Swami Shraddhamayananda

Monk in Charge of Medical Unit at Belur Math, Ramakrishna Mission, Charitable Dispensary, Belur Math, Howrah, West Bengal, Pin Code:711202, India.

***Corresponding author:** Swami Shraddhamayananda, Monk in Charge of Medical Unit at Belur Math, Ramakrishna Mission, Charitable Dispensary, Belur Math, Howrah, West Bengal, Pin Code:711202, India.

Received date: July 07, 2020; **Accepted date:** July 28, 2020; **published date:** August 03, 2020

Citation: Swami Shraddhamayananda. Homeopathic Medicines in the Early Treatment of Acne Preventing Formation of Acne Scar. J Clinical Research and Reports, 5(2); DOI:10.31579/2690-1919/105

Copyright: © 2020 Swami Shraddhamayananda. This is an open access article distributed under the Creative Commons Attribution License, which permits unrestricted use, distribution, and reproduction in any medium, provided the original work is properly cited.

Abstract

Acne is the enhanced activities of the oil glands at the base of hair follicles leading to papular and pustular eruptions over face, forehead, chest and back. Psychological problems are the main setback of acne which generally affects the adolescent population. Hyperkeratinization, obstruction of sebaceous follicles, stimulation of sebaceous gland secretion, *Propionibacterium acnes* colonization of pilosebaceous units are some of the important pathogenetic factors of the disease. Acne scars are the most important consequence of inflammatory acne. It is very common to those persons who are repeatedly infected. Thus timely control of inflammation can prevent scar formation. In many cases conventional treatment being unsuccessful and the patients become helpless in this condition. Thus in this study a possible curative as well as preventive role of homeopathic medicines was explored in such cases based on a pilot study done earlier at our Institute. A group of 500 such cases were enrolled in the study following consideration of all ethical issues and inclusion and exclusion criteria formulated at our Institute. There was also a control group of 40 cases where only placebo was given, which were similar in appearance containing only vehicle of the medicine. Single oral homeopathic medicine (*sulphur 30* or *tuberculinum 200*) was given in the test group, based on clinical case history as observed in the pilot study. No local application was used in this study. Out of 500 cases, 484 (96.8 %) cases showed significant improvements within five months of treatment, including cure and prevention of scar formation, while the control group showed no significant improvements even after six months. The results of this study were very encouraging indicating a definite role of homeopathic medicine in acne, which also prevents formation of acne scar.

Key words: Acne; Acne scar; Homeopathic medicines

Introduction

Acne is a very familiar disease in adolescents and very often it leads to development of atrophic scars (1). However, its actual prevalence is largely unknown, as different reports indicated gross disparity of the results (2). Acne vulgaris, is characterized by formation of comedones, papules, pustules, cysts, nodules and it leads to scar formation. Again pathogenesis of acne scar is also not properly known, however, cytokines, chemokines, enzymatic damage of collagen fibres may play important role in this respect, under various genetic control (3,4). Acne is often associated with follicular hyperkeratosis, hyper secretion of sebaceous glands, *Propionibacterium acnes* colonization, hypersensitivity and chronic inflammatory reactions. Some hormones e.g., excess secretion of androgen and progesterone increase sebum secretion and sebum secretion is reduced by estrogen, however, in many patients with acne these hormones are within normal limits. Excessive sebum can breakdown cellular wall causing *Propionibacteria* bacteria to grow. In our clinic 5% cases have positive family history.

It is well known that early therapy prevents development of post-acne scarring (4). Many psychological problems are associated with acne particularly in severe scarring (5). Although there are many therapeutic options of acne scar therapy (6), like laser treatment, dermabrasion,

chemical peels, punch excision techniques, percutaneous collagen induction etc., but many cases failed to improve even with most costly treatment. Thus my aim in this paper is to present extremely low cost homeopathic medicines - an alternative system of medicine without any side effects in our body, but at the same time lead to outstanding recovery from acne, blocking pathways of scar formation.

Acne commonly affects face, anterior chest and upper part of back(7). It usually begin in the teen age years (between 12 and 18 yrs) and lasts for 5 – 10 yrs. It may persist in adulthood (beyond 30 yrs). Male and female are equally affected. High glycaemic load diet and milk products may be important exciting factors. Different types of acne are given in Table 1. Differential Diagnosis of acne should be done with keratosis pilaris, rosacea and chloracne.

Most of the patients in this study came after prolonged conventional treatment (6 months to 3 years) without any significant benefit.

Materials and Methods

The patients:

Total 500 patients were enrolled in this study. There were also 40 control cases those were given placebo and followed for two months to see if there was any change. Most of the patients aged between 11 to 30 yrs (90

%), their mean age was 18 yrs. Beyond 40 yrs of age there was only few female patients (2% of total patients). Age distribution of patients is given in Fig. 1. Male: Female ratio was 0.94:1. All patients were diagnosed, categorized and followed up by our dermatologist of the Institution. The patients were enrolled after taking consent from the patients or from their parents. Permission of this study was also taken from Ethical committee of the Institute. Multiple open comedone (non-inflammatory), multiple closed comedone, papule and pustule (with moderate inflammation), multiple pustules and cysts (in inflammatory acne), severe inflammatory acne on forehead/central forehead/ nose/ chin - all these varieties of patients were treated. As most of the patients came after prolonged conventional treatment so in most of the cases all types of comedones were observed. In most of the cases face was commonly involved and although in 277 cases the patients could not remember the age of onset, among remaining 223 cases in 98 cases the age of onset was in between 14-17 years (Table 2).

Homoeopathic medicines and treatment:

The same medicines were given to all the patients except in the control group, where only lactose pills were given which looks similar to our medicines and lactose was the vehicle of these medicines. The medicine was purchased from reputed homeopathic medicine shop (HAPCO) in Kolkata. In the placebo group there were 20 males and 20 females.

Random selection was done of both sexes, of different casts and ages. Medicines were given as 4 pills (one dose) daily for 7 days then one dose in 15 days intervals. Only single oral homeopathic medicine (either “Sulphur” or “Tuberculinum”) was used orally without any local application.

Results and discussion

Earliest response was seen in majority number cases after 7 days and 484 patients were improved within 3 months. No response was noticed in 16 cases after 6 months of treatment. After two years follow up we have seen relapse in 18 cases. In placebo cases after 2 months follow up, out of 40 patients eruptions were increased in 22 patients and no change occurred in remaining 18 patients. Details of the results are given in Table 2-3 and in Fig. 2-4 . This study indicated a definite role of homeopathic medicines in the treatment of acne, not only comedones but also against inflammatory acne cases. Probably the most interesting finding in this study is remission of acne associated with scars. The average scoring of 3.6 of the scar associated acne became zero scoring after the treatment. The real mechanism of action of these homeopathic medicines is very difficult to explain, and so far there is no definite explanation of the mechanism of action of these medicines. Thus possible attempts should be made in future studies to find out the mechanism. This preliminary report may help the suffering humanity at large.

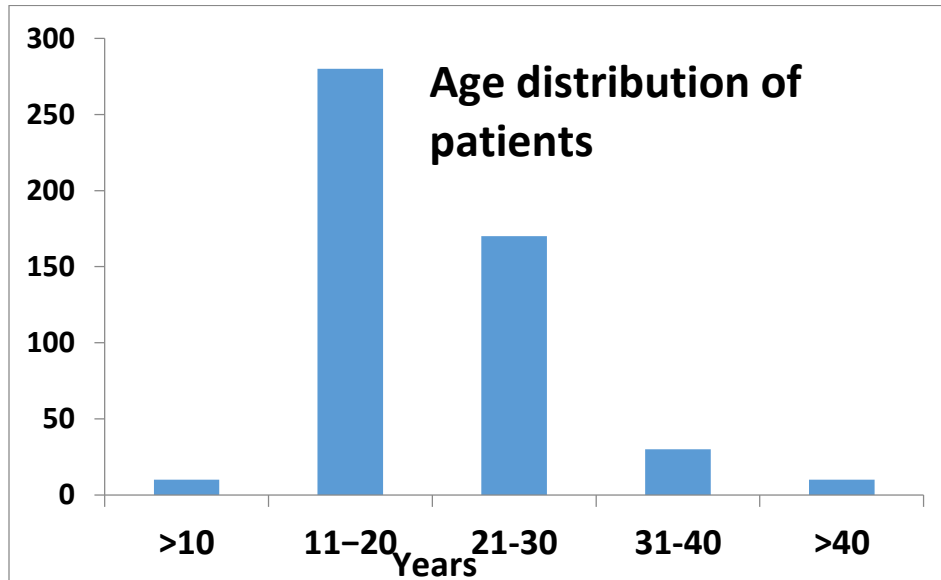


Fig 1: Age distribution of acne cases

(According to the manifestation, various terms used to clinical variants of acne like Papules, pustules, nodules, cystic, excorice, black headed, white headed etc.)

<p>A. Inflammatory</p> <ol style="list-style-type: none"> 1. Papules (pinheads) 2. Pustules (pimples) 3. Nodules (cyst) 4. Excorice (eroded papule) <p>B. Non Inflammatory</p> <ol style="list-style-type: none"> 1. Open comedones (Black headed) 2. Closed comedones (white heads).
--

Table1: Types of acne

Face (478 , 95.6%)
 Face and trunk (18, 3.6%)
 Trunk (4, 0.8%)

Age of onset
 ≤ 9 years (22 cases)
 10 years (24 cases)
 11 years (30 cases)
 12 years (21 cases)
 13 years (28 cases)
 14 – 17 years (98 cases)
 Not known (277 cases)

Table 2: Number and percentage of patients with acne, regarding affected area and age of onset

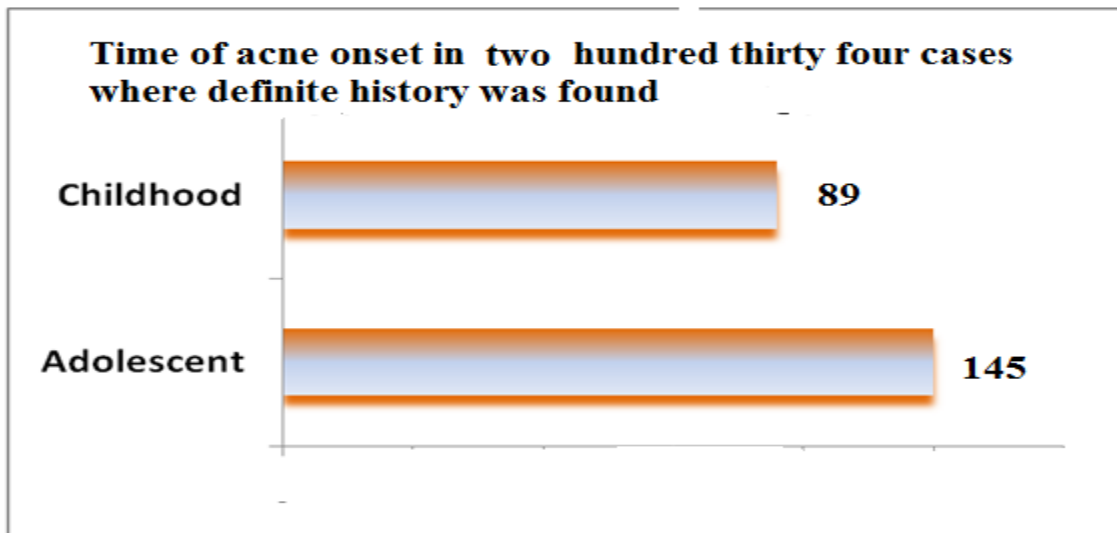


Fig 2: Graph showing onset time of acne




Severity	Age range in years	Sex		Outcome of treatment		Original scoring in acne with scar	Scoring in acne with scar after treatment
		Male	Female	Remission time	No remission		
Acne inflammatory (papule, pustule, nodule) 	16-25	96	88	2-3 months	2	-	-
Acne comedonal, noninflammatory 	12-24	24	26	1 month		-	-
Acne with scar  Ice Pick Boxcar Rolling Hypertrophic Acne Scar types	20-45	122	144	6-12 months	14	Moderate - 206 Severe- 42 Very severe- 18 (Average scoring 3.6)	0

Table 3: Acne according to severity and their outcome of treatment

Scoring in acne with scar: Clear 0 No visible scars from acne; Almost clear 1 Hardly visible scars from 2.5m Away; Mild 2 Easily recognizable; less than half the face involved; Moderate 3 More than half the face involved; Severe 4 Entire face involved; very severe 5 Entire face with prominent atrophic or hypertrophic scar.

GRADE – III Acne (Papules, pustules with severe inflammation)

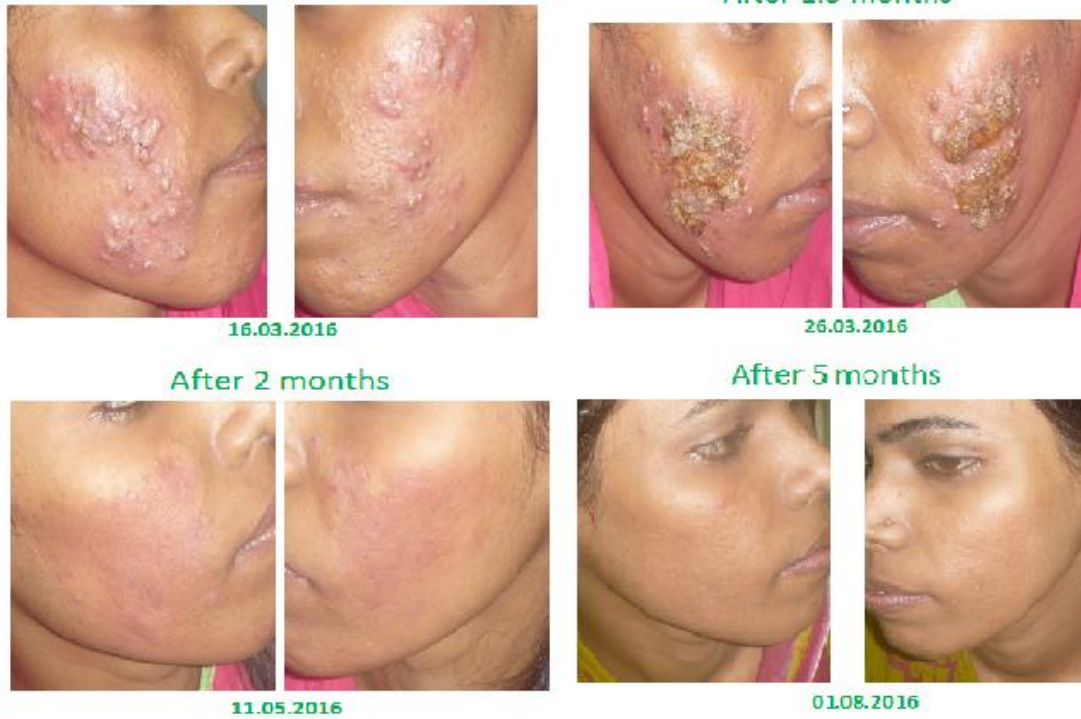

Fig. 3: RD, F, 25 yrs suffering from Grade III Acne and her cured within 5 months without any scar and pigmentation.

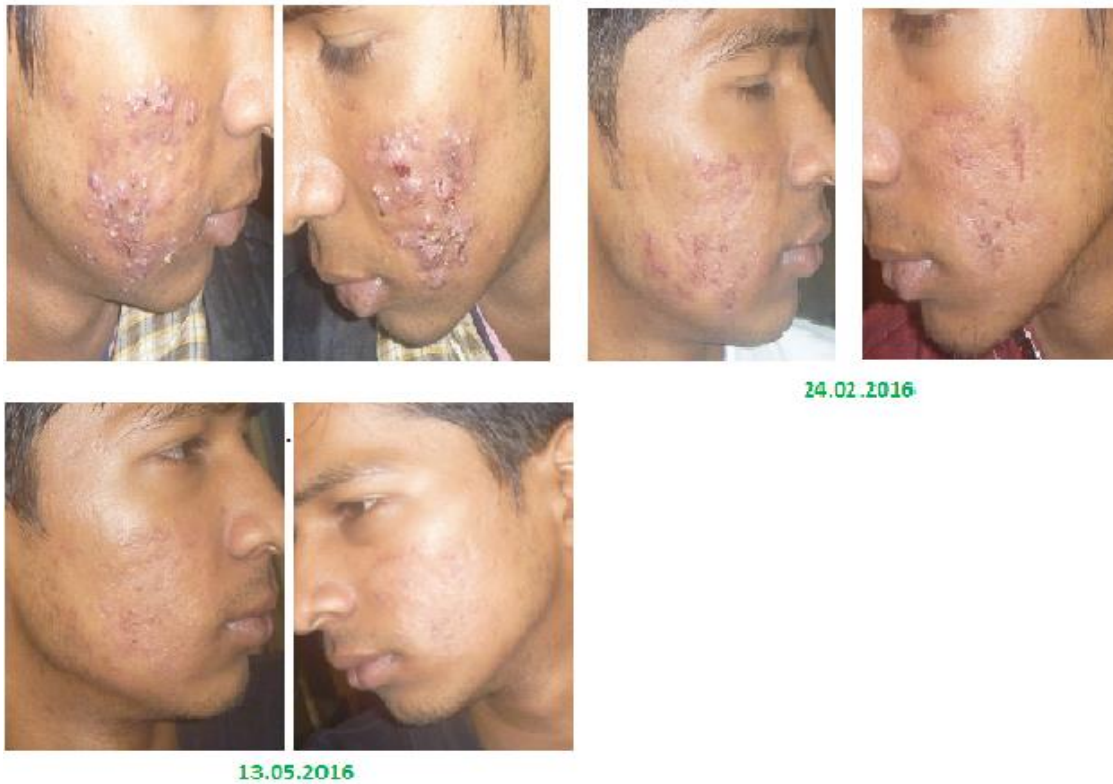

Fig. 4: AB, M, 22 yrs suffering from Grade III Acne and he cured within 5 months without any scar and pigmentation.

References

1. Capitanio B, Sinagra JL, Bordignon V, Fei PC, Picardo M, et al. Underestimated clinical features of postadolescent acne. *J Am Acad Dermatol* ,2010, 63:782-788.
2. Poli F, Dréno B, Verschoore M , An epidemiological study of acne in female adults: results of a survey conducted in France. *J Eur Acad Dermatol Venereol*,2001, 15: 541-545.
3. Holland DB, Jeremy AH, Roberts SG, Seukeran DC, Layton AM, et al. Inflammation in acne scarring: a comparison of the responses in lesions from patients prone and not prone to scar. *Br J Dermatol* ,2004,150: 72-81.
4. Fabbrocini G, Annunziata MC, D'Arco V, De Vita V, Monfrecola G, et al. Acne scars: pathogenesis, classification and treatment. *Dermatol Res Pract* 2010: 893080.
5. Koo J, The psychosocial impact of acne: patients' perceptions. *J Am Acad Dermatol* ,1995,32(Suppl): S26-S30.
6. Fabbrocini G, Vita VD, Cozzolino A, Marasca C, Mazzella C, et al. The Management of Atrophic Acne Scars: Overview and New Tools. *J Clin Exp Dermatol Res*,2012, S5:001.
7. Shen Y, Wang T, Zhou C, Wang X, Ding X, Tian S, et al. Prevalence of acne vulgaris in chinese adolescents and adults: a community-based study of 17,345 subjects in six cities. *Acta Derm Venereol*. 2012;92:40-4.



This work is licensed under Creative Commons Attribution 4.0 License

To Submit Your Article Click Here: [Submit Article](#)

DOI: [10.31579/2690-1919/0105](https://doi.org/10.31579/2690-1919/0105)

Ready to submit your research? Choose Auctores and benefit from:

- ❖ fast, convenient online submission
- ❖ rigorous peer review by experienced research in your field
- ❖ rapid publication on acceptance
- ❖ authors retain copyrights
- ❖ unique DOI for all articles
- ❖ immediate, unrestricted online access

At Auctores, research is always in progress.

Learn more www.auctoresonline.org/journals/journal-of-clinical-research-and-reports