

Pattern of Congenital Heart Diseases in Children with Congenital Malformations: An Echocardiographic study from a Tertiary Health facility in Sokoto, Nigeria

Isezuo KO^{1*}, Sani UM¹, Waziri UM¹, Garba BI¹, Adamu A¹, Musa N², Falaye MA¹, Jiya FB¹

¹Department of Paediatrics, Usmanu Danfodiyo University Teaching Hospital, Sokoto

²Department of Surgery, Usmanu Danfodiyo University Teaching Hospital, Sokoto

*Corresponding Author: Isezuo KO, Department of Paediatrics, Usmanu Danfodiyo University Teaching Hospital, Sokoto

Received Date: February 12, 2021; Accepted Date: March 30, 2021; Published Date: April 08, 2021

Citation: Isezuo KO., Sani UM., Waziri UM., Garba BI., Adamu A., et al (2021) Pattern of Congenital Heart Diseases in Children with Congenital Malformations: An Echocardiographic study from a Tertiary Health facility in Sokoto, Nigeria. *J. Clinical Cardiology and Cardiovascular Interventions*, 4(7); Doi:10.31579/2641-0419/143

Copyright: © 2021 Isezuo KO, This is an open-access article distributed under the terms of the Creative Commons Attribution License, which permits unrestricted use, distribution, and reproduction in any medium, provided the original author and source are credited.

Abstract

Background: Children with congenital malformations (CM) may have congenital heart diseases (CHDs) which may be initially asymptomatic. These need to be recognised and managed early in order to reduce unnecessary morbidity in affected patients. We report the pattern of CHDs in children with congenital malformations who had echocardiography over a one year period in UDUTH, Sokoto.

Materials and Methods: A cross-sectional study carried out in the Paediatric Cardiology Unit from 1st January to 31st December 2019. Children presenting with CM were recruited and had echocardiographic screening for CHDs. Data were analysed with SPSS 23 version. Statistical significance was taken at $p < 0.05$.

Results: 81 children were seen with CM, comprising 42 females and 39 males (M:F=0.93:1); age range of 2 days to 13 years. Most frequent malformations were anorectal malformations (ARM) in 28 (34.6%), Down syndrome in 17 (21.0%), multiple CM 10 (8.1%) and ocular abnormalities in 4 (4.9%). Thirty two (39.5%) of the patients with CM were diagnosed with CHD, out of which 24 (29.6%) had cardiac murmur. Most frequent CHD was atrioventricular septal defect in 9 (28.1%) followed by ventricular septal defect in 8 (25.0%) and patent arterial duct in 4 (12.5%). CHDs were found in all (100%) those with ocular abnormalities, in 76.5% of Down syndrome and in 14.3% of patients with ARM. Presence of murmur was significantly associated with CHD ($\chi^2=18.0$; $p=0.001$; OR=8.2; 95% C.I=2.8 – 24.1).

Conclusion: Congenital malformations, particularly Down syndrome and ocular abnormalities, are significantly associated with CHDs. Cardiac murmurs were suggestive of CHD in children with congenital malformations.

Keywords: congenital malformations; congenital heart disease; echocardiography; pattern

Background

Congenital malformations (CM) are structural abnormalities or conditions that arise in the fetus consequent to preconceptional and intragestational factors and are present at birth, but can also be diagnosed prenatally or much later in life. [1] Congenital malformations are permanent changes produced by an intrinsic abnormality in the development of a body structure prenatally. [1] Congenital malformations can potentially affect the child's health, development and survival because they can be associated with abnormalities in many body systems including congenital heart disease (CHD). [2]

Congenital heart diseases (CHD) consist of defects of the cardiac architecture which interfere with the venous drainage, septation of the cardiac segments and their sequences and regular function of the valve apparatuses. [3]

Some Congenital malformations may require emergent surgical intervention and the presence of a comorbid cardiac defect may be an anaesthetic risk. [2] Such risks may warrant delay of surgical interventions if echocardiography is not available to rule out significant CHD. [4] These

need to be recognised and managed early in order to reduce unnecessary morbidity in affected patients.

Screening such children for CHD is therefore important and those conditions more frequently associated with CHD must be recognized clinically by presence or absence of symptoms and signs of cardiac disease. The aim of the study was to ascertain the proportion and types of CHD in children with external Congenital malformations and compare with their cardiac symptoms.

Materials and Methods

Study design

This study was carried out in the Paediatric Cardiology Unit, Paediatrics department of Usmanu Danfodiyo University Teaching Hospital (UDUTH), Sokoto which is the major tertiary health facility in Sokoto State. The unit receives referrals of children with cardiac conditions from other units within the department and hospital as well as other health facilities within and outside the state and neighbouring border countries in the West African sub-region.

It was a cross-sectional study of children aged 15 years and below presenting to the Paediatric Cardiology Unit between January 2019 to December 2019. Children presenting with external Congenital malformations were recruited and had echocardiographic screening for CHDs.

Sampling method: Universal sampling method was used.

Inclusion criteria: All children presenting with major external congenital malformations that gave informed consent shall be recruited.

Exclusion criteria: Those who were very ill, limiting full examination for congenital and screening echo.

Case definition: Visible external congenital malformations affecting 1 or more systems OR >2 minor malformations as defined in the CDC checklist of surveillance of birth defects. [5]

The specific type of Congenital malformations which was the reason for their echo request was additionally confirmed before echocardiography by a complete physical examination.

Echocardiography: Cardiac diagnosis was done using two-dimensional and Doppler transthoracic echocardiography (TTE). Patients were examined in the supine and left lateral positions. The younger ones who were not cooperative were distracted with colourful toys and other techniques with the participation of the parents. The heart was examined through the standard parasternal, apical, subcostal, and suprasternal views using the Hewlett Packard Sonos 5500 echocardiography machine (Bloomfield CT 06002, USA) and 8MHz transducer.

The specific echocardiographic diagnosis was confirmed by 2 or 3 independent echocardiographers with complete agreement in all the cases.

Data Collection: A structured proforma was used to collect their demographic characteristics including age, gender, social status of the parents. The cardiac diagnosis at echocardiography was also recorded.

Ethical issues: Ethical approval for the study was obtained from the Ethics and Research Committee of Usmanu Danfodiyo University Teaching Hospital, Sokoto (UDUTH/HREC/2021/1023/V1) while consent was obtained from the parents of the children. Confidentiality was maintained as well as privacy.

Data Analysis

All relevant data were entered into a proforma sheet then analyzed using SPSS statistical software version 23. Quantitative data were expressed as means and standard deviation while categorical variables were expressed as proportions. Chi-square or where necessary, Fisher's Exact test, was used to test for statistical significance. A p-value of <0.05 was considered statistically significant.

Results

Eighty-one children were seen with external Congenital malformations, comprising 42 females and 39 males (M:F= 0.93:1); age range of 2 days to 13 years.

Most frequent malformations were anorectal malformations (ARM) in 28 (34.6%), Down syndrome in 17 (21.0%), multiple anomalies 10 (8.1%), isolated anomalies 22 (27.1%) and ocular abnormalities (cataract) in 4 (4.9%) (**Table 1**).

Type of anomaly	Frequency (%)
Anorectal malformations	28 (34.6)
Down syndrome	17 (21.0)
Multiple CM	10 (8.1)
Omphalocele	5 (6.2)
Bladder extrophy	3 (3.7)
Ocular abnormalities	4 (4.9)
Polydactyly	4 (4.9)
Encephalocele	3 (3.7)
Prune-belly	1 (1.2)
Sacroccygeal teratoma	2 (2.5)
Multiple herniae	2 (2.5)
Others	2 (2.5)
Total	81 (100)

Table 1: Showing the types and frequencies of the external anomalies

The source of referral of the cases of CM was mainly from the Paediatric surgical unit, followed by Paediatric neurology and Neonatology. (**Figure 1**)

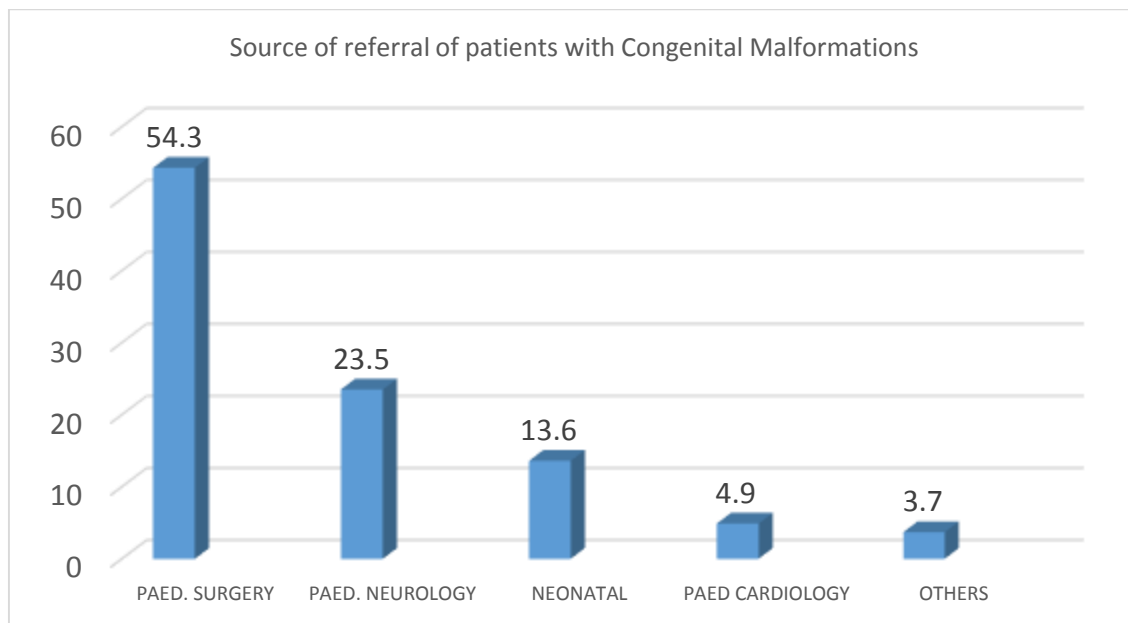


Figure 1: Showing source of referral for the patients

Of the 81 patients with CM, 32 (39.5%) were diagnosed with CHD while 49 (60.5%) did not have CHD. CHDs were found in all (100%) those with ocular abnormalities, in 76.5% of Down syndrome and in 14.3% of patients with ARM. Table 2 shows there was a high association of CM

with CHD in patients with ocular abnormalities and Down syndrome. For those with multiple CM, 50% had CHD, while CHD was completely absent in polydactyly and encephalocele.

External Congenital malformation	CHD Present N (%)	CHD Absent N (%)	p-value
Anorectal malformation	4 (14.3)	24 (85.7)	0.02
Down syndrome	13 (76.5)	4 (23.5)	0.00
Multiple CM	5 (50.0)	5 (50)	0.3
Omphalocele	1 (20.0)	4 (80.0)	0.64
Bladder extrophy	1 (33.3)	2 (66.7)	0.7
Ocular abnormalities	4 (100)	0 (0.0)	-
Polydactyly	0 (0.0)	4 (100)	-
Encephalocele	0 (0.0)	3 (100)	-
Prune-belly	1 (100)	0 (0)	-
Sacroccygeal teratoma	1 (50)	1 (50)	-
Multiple herniae	1 (50)	1 (50)	-
Others	1 (50)	1 (50)	-
Total	32 (39.5)	49 (60.5)	

NA- not applicable

Table 2: Frequency of occurrence CHD in different CM

Most frequent CHD was atrioventricular septal defect in 9 (28.1%) followed by ventricular septal defect in 8 (25.0%) and patent arterial duct in 4 patients (12.5%). AVSD occurred predominantly in Down syndrome

while PDA occurred predominantly in those with ocular abnormalities. Majority had acyanotic CHD (87.5%) while 4 had cyanotic CHD (12.5%) of which 3 had multiple CM.

External Congenital malformation	VSD	ASD	VSD+ASD	AVCD	PDA	TOF	OTHERS
ARM	2 (25.0)	2 (50.0)					
Down syndrome	3 (37.5)		2 (66.7)	7 (77.8)		1 (100)	
Multiple CM		2 (50.0)					3 (100)
Omphalocele			1 (33.3)				
Bladder extrophy	1 (12.5)						
Ocular abnormalities	1 (12.5)				3 (75)		
Prune-belly					1 (25)		
Sacroccygeal teratoma	1 (12.5)						
Multiple herniae				1 (11.1)			
Others				1 (11.1)			
Total	8 (25.0)	4 (12.5)	3 (9.4)	9 (28.1)	4 (12.5)	1 (3.1)	3 (9.4)

Table 3: Showing type of CHD seen in the different types of external CM

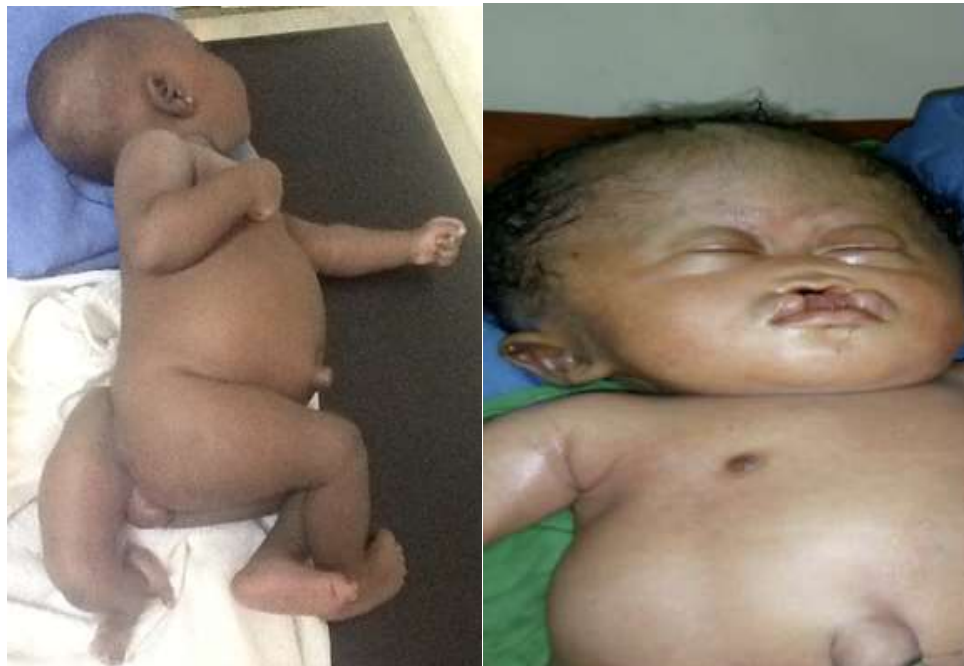

Figure 2a & 2b: Showing a child with sacrococcygeal teratoma and another with multiple facial anomalies

Majority 22 (68.8%) of those with CHD were asymptomatic while other symptoms detected were fast breathing 6 (18.8%), poor growth 3 (9.3%) and chest bulge 1 (3.1%).

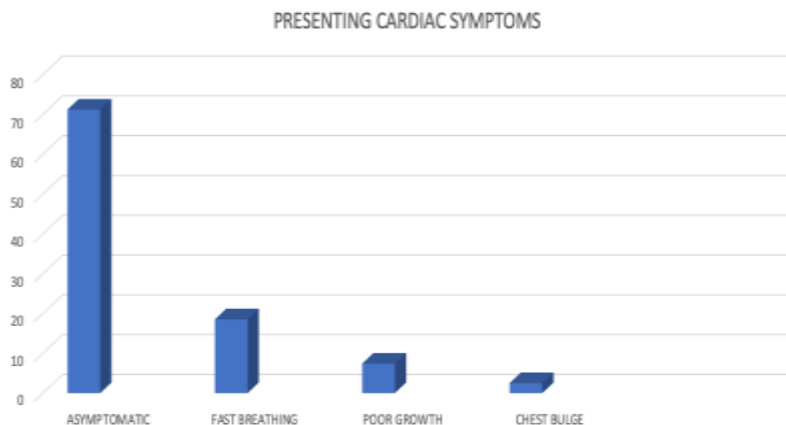


Figure 3: Showing the symptoms at presentation

The presence of cardiac murmur on auscultation was also examined for association with eventual diagnosis of CHD. Out of the total of 81 patients with CM, 24 (29.6%) had cardiac murmur. Presence of cardiac

murmur was significantly associated with CHD ($\chi^2= 18.0$; $p=0.001$; $OR=8.2$; 95% C.I=2.8 – 24.1) (Table 4).

	CHD present N (%)	CHD absent N (%)	Total
Cardiac murmur present	18 (56.6)	6 (13.7)	24 (29.6)
Cardiac murmur absent	14(43.3)	43 (86.3)	57 (70.4)
	32 (37)	49 (63)	81 (100)

($\chi^2=18.0$; $p=0.001$; $OR=8.2$; 95% C.I=2.8 – 24.1)

Table 4: Showing the relationship of presence of cardiac murmur to diagnosis of CHD

Discussion

ARM was the commonest CM presenting for echocardiography in this study and this is consistent with a report by Lawal which was an overview of studies from all over Africa where ARM has been documented to be the most common structural occurring in children. [6] This is unlike the finding in a similar echocardiographic study by Oyati *et al* from Zaria, Nigeria, [7] located within the same northwestern region as the study area, where cleft lip and palate was the commonest surgical anomaly (38.3%), followed by ano-rectal malformation (26.7%). In this study, cleft lip was seen only in one child co-existing with other multiple major anomalies. The relative paucity of facial clefts among our cohort could be due to the presence of a facility in the study area which is specifically dedicated to catering for congenital and acquired facial clefts. [8] Another study by Ekure [9] showed that Down syndrome as the commonest CM presenting for echocardiography accounting for more than half (53.4%) of those presenting with CM while in this study Down syndrome was the 2nd commonest indication.

CHD was detected in 39.5% of our cases similar to 35% reported by Oyati. [7] The study by Ekure also showed a much higher figure of 73% having CHD as most of their patient cohort there had recognizable syndromes associated with CHD. [9] The commonest anomaly in our study was AVSD while in the Zaria and Lagos studies, [7,9] it was ASD and VSD respectively reflecting probably the different proportions of the anomalies.

The incidence of CHD in ARM, the commonest CM in this study appeared low (14.3%) compared to other reports like that of Kamal and Azhar [10] who reported the occurrence of CHD in 24.6% patients and Hashemizadeh [10] from Turkey reported 23.7% incidence of CHD among cases of ARM. Two studies from Iran revealed similar higher incidence rate of CHD of 30% and 50.4% in newborns with ARM. [11,12] Half of the patients with ARM in this study had ASD which has also been reported as the most prevalent CHD in those with ARM in other studies as they usually have less of complex CHD. [11,12] This is of import as opined by Nasr *et al* who examined records to ascertain if routine echocardiography is necessary for all neonates with some CM or if appropriate patients who are not at risk could be selected without preoperative echocardiography. [13]

The commonest CHD in those with DS was AVSD which is seen associated with this anomaly in several reports. [14-16] Also, all those with ocular anomalies had CHD which was mainly PDA which could be due to genetic causes. [17-18] Two of the ocular anomalies were cataracts which is associated with Congenital rubella syndrome of which the

cardiac component is PDA. A study in Italy has reported significant association between ocular anomalies and CHD. [19]

Although, majority of the patients seen were asymptomatic, those who had detectable cardiac murmurs eventually turned out positive for CHD. However, some did not also have any murmur and were diagnosed with complex defects. Some authors have opined for routine screening for all those with CM due to observations of increased morbidity and mortality with combined malformations, [20,21] while others suggest that in emergency conditions, pre-operative echo may not be absolute if not available especially in a CM not commonly associated with CHD. [4]

Conclusion:

Congenital malformations, particularly Down syndrome and ocular abnormalities, are commonly associated with CHDs. ARM has a relatively low incidence of CHD, which were not complex defects. Cardiac murmurs were suggestive of CHD in children with congenital malformations. However, due to significant number who were asymptomatic that were still diagnosed with CHD, it is importance that all children with CM should be screened for CHD.

References

1. Jones, KL. "From introduction," in Smith's Recognizable Pattern of Human Malformations, pp. 1–9, WB Saunders, Philadelphia, Pa, USA, 4th edition, 1988.
2. Nacher M, Lambert V, Favre A, Carles G, Elenga N. High mortality due to congenital malformations in children aged <1 year in French Guiana. *BMC Pediatrics* 2018;18(1):393.
3. Thiene G, Frescura C. Anatomical and pathophysiological classification of congenital heart disease. *Cardiovasc Pathol* 2010;19(5):259-274.
4. Short SS, Pierce JR, Burke RV, Papillon S, Frykman PK, Nguyen N. Is routine preoperative screening echocardiogram indicated in all children with congenital duodenal obstruction? *Pediatr Surg Int* 2014;30(6):609-614.
5. CDC. Birth defect surveillance toolkit. <https://www.cdc.gov/ncbddd/birthdefects/surveillancemanual/chapters/chapter-1/chapter1-4.html> (accessed 31/12/18).
6. Lawal TA. Overview of Anorectal Malformations in Africa. *Front Surg* 2019;6:7.
7. Oyati A, Danbauchi S, Ameh E, Mshelbwala P, Anumah M, Ogunrinde O, et al. Echocardiographic findings in

- children with surgically correctable non-cardiac congenital anomalies. *Ann Trop Paediatr* 2009;29:41-44.
8. Cousin GCS, Hamlin GW. Treatment at the Noma Children Hospital, Sokoto, Nigeria: report of Team 40. *Br J Oral Maxillofac Surg* 2009;47(7):e68.
 9. Ekure E, Animasahun B, Bastos M, Ezeaka C. Congenital Heart Diseases associated with Identified Syndromes and Other Extra-Cardiac Congenital Malformations in Children in Lagos. *West Afr J Med* 2009;28:33-37.
 10. Kamal JS, Azhar AS. Congenital cardiac anomalies and imperforate anus: A hospital's experience. *J Cardiovas Dis Res* 2013;4(1):34-36.
 11. Hashemizadeh H, Boroumand, Hiraifar M. Investigating the Prevalence of Congenital Heart Disease in Imperforate Anus Infants Referred To Pediatric Surgery Department of Dr. Sheikh Hospital in Mashhad Iran. *IJOGI* 2012;15:21-27.
 12. Abadi S, Abadi N, Mashrabi O, Homa F. Congenital Heart Anomalies in Babies with Imperforate Anus and its Mortality. *Res J Biol Sci* 2008;3:922-24.
 13. Nasr A, McNamara PJ, Mertens L, Levin D, James A, Holtby H, et al. Is routine preoperative 2-dimensional echocardiography necessary for infants with esophageal atresia, omphalocele, or anorectal malformations? *J Pediatr Surg* 2010;45(5):876-879.
 14. Ashraf M, Malla M, Javed C, Mohd IM, Mymoona A, Ayaz R, et al. Consanguinity and pattern of congenital heart defects in Down syndrome in Kashmir, India. *AJSIR* 2010;1(3):573-577.
 15. Vilas Boas L, Albernaz EP, Costa RG. Prevalence of congenital heart defects in patients with Down syndrome in the municipality of Pelotas, Brazil. *J Pediatr (Rio J)* 2009;85(5):403-407.
 16. Sadoh W, Ewenitie E-U, Isah I. Profile of clinical features, congenital heart disease and other comorbidities in children with Down syndrome in a tertiary care centre in Nigeria. *Sri Lanka J Child Health* 2018;47:50.
 17. Gelb B. Char Syndrome. 2003 Aug 15 [Updated 2020 May 21]. In: Adam MP, Ardinger HH, Pagon RA, et al., editors. *GeneReviews®* [Internet]. Seattle (WA): University of Washington, Seattle; 1993-2021. Available from: <https://www.ncbi.nlm.nih.gov/pmc/articles/PMC2706822/>
 18. Oliveira PHA, Souza BS, Pacheco EN, Menegazzo MS, Corrêa IS, Zen PRG, et al. Genetic Syndromes Associated with Congenital Cardiac Defects and Ophthalmologic Changes - Systematization for Diagnosis in the Clinical Practice. *J Arquivos Brasileiros de Cardiologia*. 2018;110:84-90.
 19. Morreale-Bubella R, Piccione M. Correlation between Ophthalmic Disorders and Congenital Cardiac Disease in Children with Down Syndrome. *Int J Ophthal Res* 2017; 3(2): 231-233
 20. Rosa RCM, Rosa RFM, Zen PRG, Paskulin GA. Cardiopatias congênitas e malformações extracardíacas *J Revista Paulista de Pediatria*. 2013;31:243-251.
 21. Wojtalik M, Mrówczyński W, Henschke J, Wronecki K, Siwińska A, Piaszczyński M. Congenital heart defect with associated malformations in children. *J Pediatr Surg* 2005;40:1675-1680.



This work is licensed under Creative Commons Attribution 4.0 License

To Submit Your Article Click Here: [Submit Manuscript](#)

DOI: [10.31579/2641-0419/143](https://doi.org/10.31579/2641-0419/143)

Ready to submit your research? Choose Auctores and benefit from:

- ❖ fast, convenient online submission
- ❖ rigorous peer review by experienced research in your field
- ❖ rapid publication on acceptance
- ❖ authors retain copyrights
- ❖ unique DOI for all articles
- ❖ immediate, unrestricted online access

At Auctores, research is always in progress.

Learn more www.auctoresonline.org/journals/clinical-cardiology-and-cardiovascular-interventions