

Nasopharyngeal Carcinoma in Children: Experience of Pierre & Marie Curie Center

K.Ezziane^{1*}, M Bouallag², N. Habchi², M.Saoudi¹ and K.Bouzid¹

¹Pediatric oncology, Pierre & Marie Curie Center, Algiers, Algeria.

²Department of neurosurgery Mustapha Pacha hospital, Algiers, Algeria

*Corresponding Author: K.Ezziane, Pediatric oncology, Pierre & Marie Curie Center, Algiers, Algeria, E-mail: ezzianekarim@yahoo.fr

Received Date: May 26, 2020; Accepted Date: June 30, 2020; Published Date: July 23, 2020.

Citation: K.Ezziane. Nasopharyngeal Carcinoma in Children: Experience of Pierre & Marie Curie Center .J.Clinical Onco Res and Rep.1 (1). Doi: 10.31579/2693-4787/005

Copyright: © 2020 K.Ezziane, This is an open-access article distributed under the terms of the Creative Commons Attribution License, which permits unrestricted use, distribution, and reproduction in any medium, provided the original author and source are credited.

Abstract:

A retrospective study was undertaken on 50 patients in pediatric age group with diagnosis of nasopharyngeal carcinoma (UCNT) in children, treated from 2008 to 2013 on our oncologic center. For all the patients, the diagnosis was made after surgery. All patients received adjuvant chemotherapy. The combined modality of chemotherapy and radiotherapy results is satisfactory for loco regional control and survival and acceptable for toxicity in patients with nasopharyngeal carcinoma in pediatric age group.

Keywords: nasopharyngeal; carcinoma in pediatric age; chemotherapy; radiation

Introduction:

Nasopharyngeal carcinoma in children represent 5% of all children's solid tumors. [1] Its geographical distribution is particular, the Maghreb being a zone of average endemic where the child constitutes the second peak of frequency. [4] Its etiology is multifactorial and its treatment rests based on chemotherapy and radiotherapy. [1] [2]

The purpose of our study is to evaluate the diseases characteristics and outcome of the patients with nasopharyngeal carcinoma in pediatric age in our institute.

Material & Methods:

Retrospective study was undertaken on 50 patients in pediatric age group with diagnosis of nasopharyngeal carcinoma, treated from 2008 to 2013 at our oncologic center. For all the patients, the diagnosis was made after clinical examination imagery and biopsy.

Treatment:

Patients were treated with combined chemotherapy and radiotherapy; all them were received adjuvant chemotherapy including 3 courses of a regimen included:

5 fluorouracil, cisplatinum followed by concomitant radio-chemotherapy. The median dose of radiotherapy was 60 gray.

Results:

The median age was 13 years (3 months to 16 years) (figure 1). Male/female ratio was: 1.9 (figure 2). The patient consult 3 to 8 months after onset (figure 3). The revealing signs are otologica l (49%) cervical

nodes (43%) neurological injury (8%). Histological type was UCNT undifferentiated carcinoma of nasopharyngeal type. All patients were classified T3 or T4.

The evaluation was done after the Clinical examination, nasofibroscoy and nasopharynx CT scan.

Partial response were 55% complete response 45%. After median follow-up of 48 months, overall survival and disease free survival was 60% and 54%.

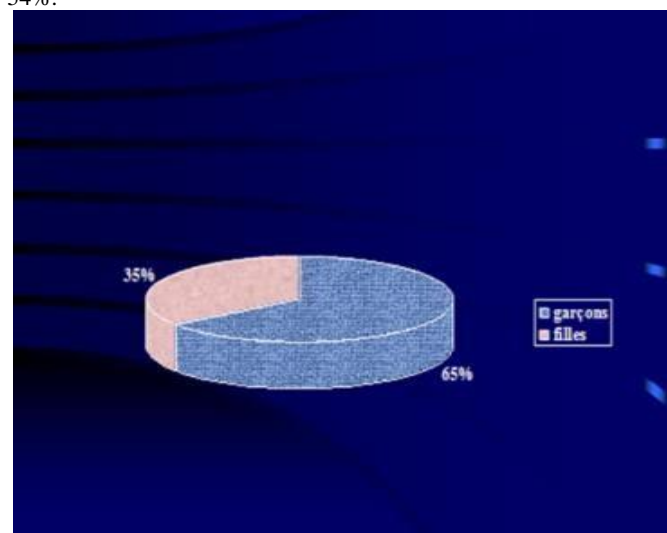


Figure 1 : Sex repartition of patients

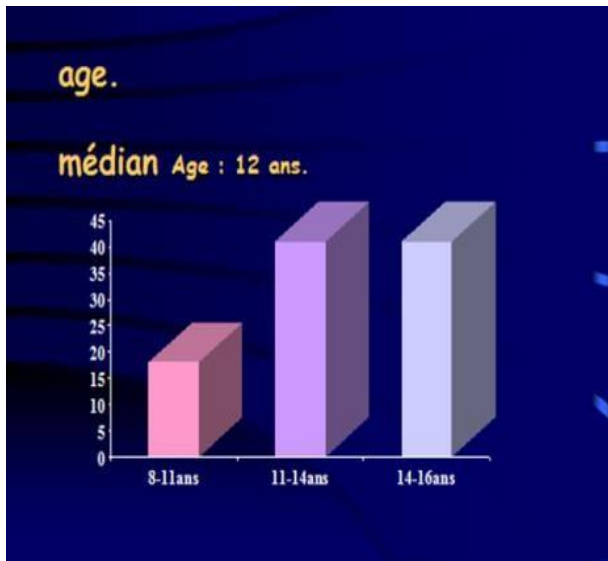


Figure 2 : Age repartition of patients

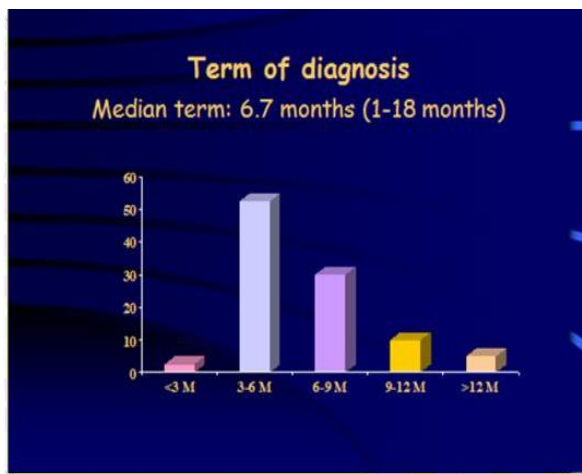


Figure 3 : Term of diagnosis of disease

Discussion:

The much contrasted geographical distribution of the nasopharyngeal cancer (NPC) represents one of the characteristics of this disease. A high incidence of NPC has been noted among Maghrebins, South-east Asians and Indians. Algeria is a part of the great Maghreb, the incidence of this

cancer is high. [5][6] NPC is related to the Epstein Barr virus (EBV), genetic, dietary and/or environmental factors [3]. Dietary and environmental risk factors potentiate each other to cause the disease.

We noted a statistically significant relation between NPC, home-curing in brine, preservation of rancid butter and lack of potable water. [4] Agricultural practices, livestock production, cooking food in earthenware, contact with toxic substances, with household smoke and proximity to animals increase the risk of contracting the disease, but not in a significant manner. [1][2] The cancer was locally advanced in the majority of cases. The delay to the diagnosis in Morocco strike the prognosis of this cancer.

Many drugs are currently under investigation. (taxoides, gemcitabine), targeted therapy, immunotherapy. Studies have been carried out and published. Currently new therapies are being tested: EBV, EGFR, VEGF in adult patients and children. Studies are also being done to limit the toxicity of treatments. [7]

Conclusion:

UCNT is frequent in Algeria, the combined modalities of chemotherapy and radiotherapy results are satisfactory for loco regional control and survival and acceptable for toxicity in patients with nasopharyngeal carcinoma in pediatric age group. Many advances have been made in understanding pathogenesis, mainly the relationship with the EBV virus; the development of new therapeutics (discovery of new antimetabolic drugs, targeted therapy, immunotherapy and anti-EBV vaccination) are necessary for metastatic and refractory forms.

References:

1. Treatment of Advanced NPC in Children SJCRH NPC-1 Study Douglass et al. Proc ASCO 1996
2. Neoadjuvant CT + Chemoradiation Rischin et al J ClinOncol 2002
3. CT and MR features of nasopharyngeal carcinoma in children and young adults. Yabuuchi H, Fukuya T, Murayama S, Sakai S, Okamura J, Fukuda T, Tomita K, Ro T, Masuda K, ClinRadiol 2002 Mar;57(3):205-10
4. Case-control study (Laouamri S Rev EpidemiolSantePublique. 2001).
5. Phase II Docetaxel and Cisplatin in locally advanced NPC in Adults, K Bouzid and all international study: (OR 90%, CR 44%, PR 46%).ASCO 2005
6. Phase II Gemcitabine and Cisplatin in locally advanced NPC in Adults. K bouzid and all: (OR 87%, CR 47%, PR 40%).ICACT 2004.
7. Phase III Study of Amifostine as Radioprotectant in Head and Neck Carcinoma. Brizel et al. J Clin Oncol 2000