

Budesonide Induced Hyperosmolar Hyperglycemic State following Transjugular Intrahepatic Portosystemic Shunt (TIPS)

Thejus T Jayakrishnan MD*; Vladimir Limonnik DO; Deep Shah MD, Prerna Mewawalla MD

Division of Hematology/ Medical Oncology, Department of Medicine, Allegheny General Hospital; Pittsburgh, PA., USA

*Corresponding Author: Thejus Jayakrishnan MD, Division of Hematology Oncology, Department of Medicine, 320 E North Avenue, Pittsburgh, 15212, Phone (412) 359 4971.

Received date: February 14, 2020; Accepted date: May 22, 2020; Published date: May 30, 2020.

Citation: Thejus T Jayakrishnan, Vladimir Limonnik, Deep Shah, Prerna Mewawalla. (2020) Budesonide Induced Hyperosmolar Hyperglycemic State following Transjugular Intrahepatic Portosystemic Shunt (TIPS). International Journal of Clinical Case Reports and Reviews. 2(3); DOI:10.31579/2690-4861/012.

Copyright:©2020 Thejus T Jayakrishnan, This is an open-access article distributed under the terms of the Creative Commons Attribution License, which permits unrestricted use, distribution, and reproduction in any medium, provided the original author and source are credited.

Summary

A 62 years old female with history of Combined Variable Immunodeficiency (CVID) complicated by colitis (managed by 9mg Budesonide by mouth daily) and refractory ascites secondary to non-cirrhotic portal hypertension (status post Transjugular Intrahepatic Portosystemic Shunt- TIPS 3 weeks prior) presented to the hospital with Hyperosmolar Hyperglycemic State (HHS). Her initial insulin requirements were high but improved after discontinuation of Budesonide. She was able to be transitioned to a sliding scale and discharged on Metformin. When taken orally, Budesonide is subject to high first-pass metabolism resulting in minimal systemic effects. Development of HHS and dramatic insulin requirements within 3 weeks of TIPS with drastic improvement following the discontinuation of Budesonide leads us to postulate that this was bypassed leading to steroid induced diabetes. This case beckons us to be mindful of procedures that alter drug metabolism and make necessary adjustments to prevent complications.

Keywords: combined variable immunodeficiency; intrahepatic portosystemic shunt; metformin

Background

Budesonide is a corticosteroid with a high degree of topical activity and low systemic bioavailability. This is a result of its high affinity for the glucocorticoid receptor and a high first-pass metabolism in the liver. [1] Owing to these attributes, oral Budesonide is a preferred therapy in patients with immune mediated bowel disease. [2-7] Drugs that impair the first-pass metabolism of Budesonide or cause alterations in its delivery to the liver for metabolism may result in manifestation of systemic steroid side effects. We present a case of steroid induced diabetes in a patient on Budesonide as a result hepatic circulation bypass and decreased drug metabolism following transjugular intrahepatic portosystemic shunt (TIPS). As far as we know, this is the first case report of the rare drug side effect surfaced by the procedure.

Case Presentation

A 62 year-old female with past history of Combined Variable Immunodeficiency (CVID) complicated by colitis and pneumonitis, non-cirrhotic portal hypertension with refractory ascites status post Transjugular Intrahepatic Portosystemic Shunting (TIPS) presented to the hospital with a 7-10 days history of confusion, unsteady gait, polyuria, and polydipsia. Patient had previously undergone liver biopsy showing nodular regenerative hyperplasia and increased portosystemic gradient consistent with non-cirrhotic portal hypertension. Her medication list included Budesonide (9mg po once daily) for her colitis. Patient had no history of diabetes and had three non-fasting blood glucose measurements

in the three preceding months prior to presentation of 83, 95, and 166mg/dl. She had a TIPS procedure performed three weeks prior to presentation for refractory ascites associated with her portal hypertension.

Work up revealed ammonia of 88mcmol/L (her baseline), positive influenza test, and Hyperosmolar Hyperglycemic State (HHS). The HbA1c was found to be 7.7%. She was admitted to the hospital and started on intravenous fluids, insulin infusion and Oseltamivir for the influenza. Her initial insulin requirements were very high, at roughly 200U/day for the first 48 hours of her stay. She took all her regular medications including Budesonide on Day 1 prior to admission. She was given 1 dose (9mg) of Budesonide on day 2 of her stay which promptly elevated her blood sugar to 362mg/dl and necessitated increasing her insulin needs. Budesonide was discontinued on day 3 of the hospitalization. On day 4, her insulin requirements dramatically decreased to only 20U/day. On the fifth day, she was discontinued from the drip and placed on sliding scale insulin, needing roughly 12U/day. Of note, her AM cortisol was 10.5mcg/L - within normal limits.

Outcome And Follow-Up

Figure 1 demonstrates the daily insulin requirements of the patient. Patient remained hemodynamically stable with no signs of steroid withdrawal. She was discharged on 500mg of metformin twice a day in a stable condition.

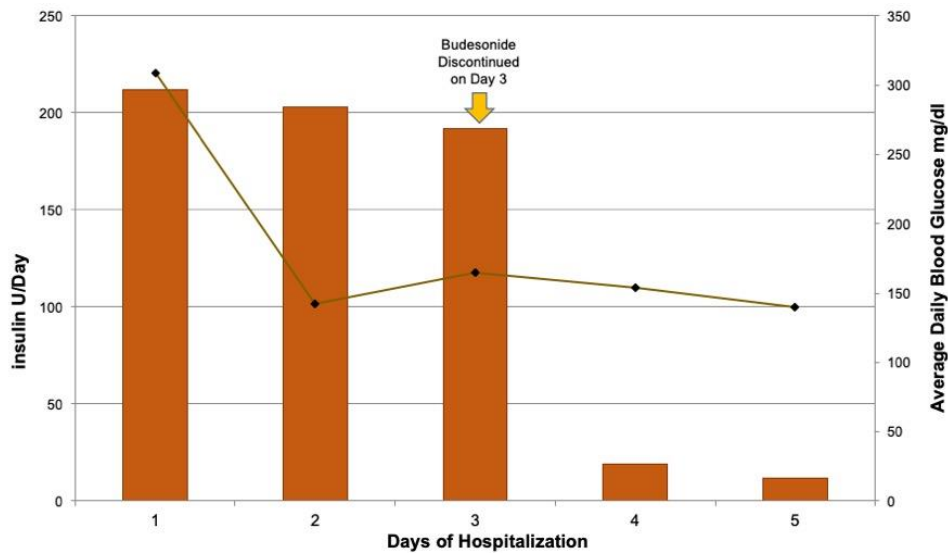


Figure 1: Graphical Representation of the Daily Mean Glucose Levels and Insulin Requirement for Glycemic Control During the Hospital Stay. Note the Drastic Improvement after Budesonide Cessation on Day 3

Discussion

Budesonide is a nonhalogenated glucocorticoid (16 α , 17-butyliendioxo-11 β , 21-dihydroxy-1,4-pregnadien-3,20-dione) with a high degree of topical anti-inflammatory activity. Improved safety and tolerability has been demonstrated with Budesonide owing to its extensive biotransformation by cytochrome P450 (CYP) 3A into pharmacologically inactive metabolites (first-pass metabolism) and a resultant systemic bioavailability of only 10–15% compared to other corticosteroid formulations.[1,8,9] Initially introduced for the treatment of asthma and rhinitis, its indications have since broadened to conditions where local anti-inflammatory action is needed.[8] Oral Budesonide is most commonly used in inflammatory bowel diseases, especially Crohns disease.[2-7] Efficacy of Budesonide in inducing disease remission has been demonstrated in large well designed clinical trials in patients with active mild to moderate Crohns disease. The dose of 9mg that was used in our patient has been shown to be more effective with less systemic side effects compared 2g twice daily of oral mesalamine and similar in efficacy to recommended dosage of prednisolone (40mg daily tapered after two weeks).[1] Other inflammatory gastrointestinal conditions where Budesonide has been used include pouchitis after ileal pouch anal anastomosis following surgery for ulcerative colitis, eosinophilic esophagitis, protein losing enteropathy, primary biliary cirrhosis and lymphocytic colitis.[10-14] Utility of Budesonide has also been explored for prophylaxis for Gastrointestinal Graft Versus Host Disease (GI-GVHD) after hematopoietic stem cell transplant (HSCT).[15-16] Currently, oral Budesonide is available as controlled release formulation for targeted drug delivery to inflamed intestinal regions.[8] Studies are

ongoing to optimize the local delivery of the drug to distal targets in the GI tracts.[8,17] Although it has a high first-pass metabolism, prolonged use of Budesonide may result in mild suppression of adrenal glucocorticoid generation but no hemodynamically or endocrinologically significant side effect has been described in the usual clinical circumstances.[2,18,19,20] In contrast, typical systemic steroid side effects such as iatrogenic Cushing's syndrome has been described in circumstances where the metabolism of Budesonide was slowed by CYP450 inhibiting drugs such as Ritonavir, Fluvoxamine and Azoles.[21,22] For instance, in a group of post-HSCT patients with GI-GVHD who were also on CYP 450 inhibitor azoles, Budesonide administration was associated with suppression of morning plasma cortisol, significant plasma levels of Budesonide and a rapid (within 3 weeks) onset of iatrogenic Cushing's syndrome.[23] The authors also suggested increased absorption through an inflamed gut wall that led towards these effects. They postulated that 9 mg of oral Budesonide exerted a pharmacodynamic effect equivalent to 40 mg of oral prednisone. [23] Naturally, one may therefore question the use of Budesonide in patients with liver dysfunction such as the patient in the present case. Surprisingly, it is a drug approved for use in autoimmune hepatitis as a first-line agent in the initial stages. [24] As cirrhosis develops, there could be upto a 13 fold increase in systemic drug concentration and subsequent manifestations of side effects [25]. The patient in the present case had non-cirrhotic portal hypertension and likely somewhat preserved metabolism of Budesonide that prevented any significant systemic effects until the TIPS procedure. Our hypothesis is that TIPS provided a bypass conduit around the liver thereby allowing the drug concentration of Budesonide to reach very high systemic levels as demonstrated in Figure 2.

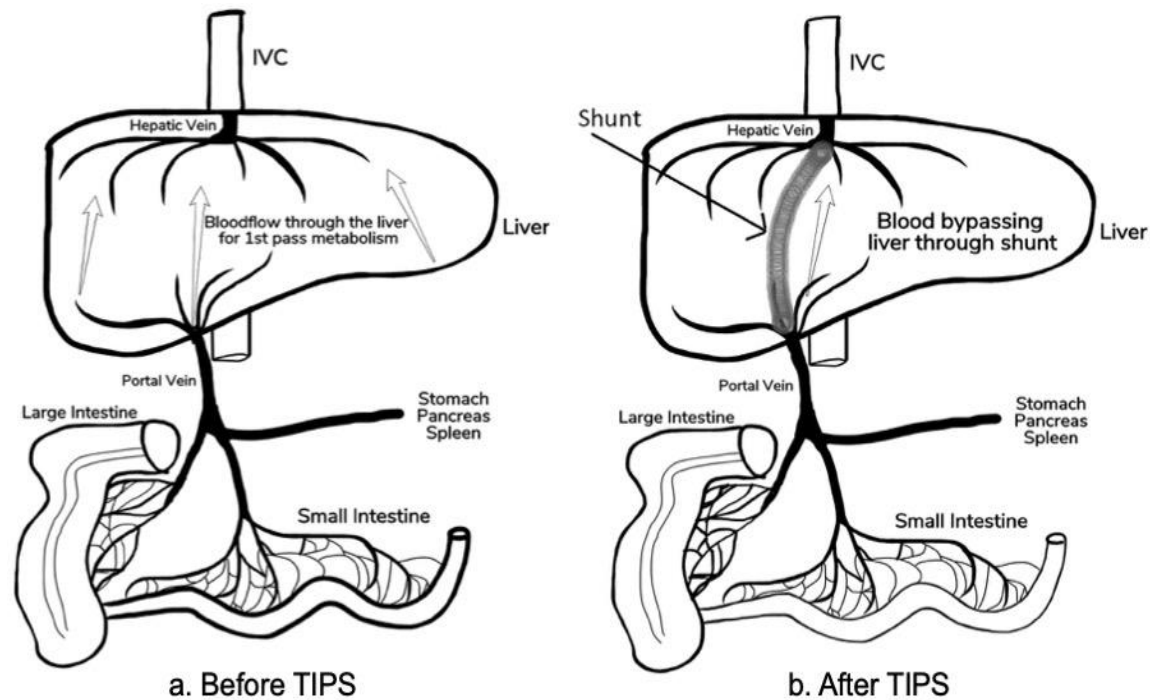


Figure 2: Diagram Demonstrating the Bypass of Hepatic First Pass Metabolism of Budesonide After TIPS Procedure Allowing High Systemic Concentration to Cause Side Effects

Although peripheral Budesonide levels were not checked, we suspect this caused the steroid induced diabetes in the patient. Within 24 hours of discontinuing the Budesonide, there was a precipitous drop in insulin requirement as evidenced in Figure 1. This presents a strong argument that Budesonide is causal to this and could be easily proven by measuring Budesonide level in the patient's serum while on the medication. Transjugular Intrahepatic Portosystemic Shunt is a procedure developed to treat complications of portal hypertension in appropriately selected candidates. In patients such as that presented in this report, TIPS has been shown to decrease the need for repeat large volume paracentesis. [26] The complications that have been reported relates to the procedure directly or stent dysfunction.[26] To the best of our knowledge, this is the first case report describing the rare side effect of this drug thought to be caused by the bypassing conduit of the TIPS procedure. It is assumed that the inflamed GI tract in the setting of colitis also led to increased absorption.

Learning Points

- Budesonide is a highly potent glucocorticoid (15 times effect of prednisolone) and is a preferred steroid for treatment of immune mediated disorders of gastrointestinal and respiratory tracts.
- While one may think that Budesonide is not absorbed when taken orally, this is not true. It is absorbed, but then rapidly metabolized in the liver leading towards minimal systemic glucocorticoid effects.
- Development of Type 2 Diabetes Mellitus, Hyperosmolar Hyperglycemic State, and dramatic insulin requirements within three weeks of TIPS leads us to postulate that the first-pass metabolism of Budesonide was bypassed following TIPS leading

to steroid induced diabetes. This is supported by the very abrupt and significant drop in insulin requirements upon cessation of Budesonide.

- This case beckons us once again to be mindful of major procedures that alter drug metabolism and carefully review their medications to make necessary adjustments to prevent harm to patients.

References

1. McKeage K, Goa KL. (2002) Budesonide (Entocort EC Capsules): a review of its therapeutic use in the management of active Crohn's disease in adults. *Drugs*.62 (15):2263–2282.
2. Svoboda RP, Patel DH, Olden KW. (2008) Oral formulations of budesonide: a novel treatment for inflammatory bowel disease. *Drugs Today*. 44(11):857–863.
3. Lichtenstein GR, Bengtsson B, Hapten-White L, Rutgeerts P. (2009) Oral budesonide for maintenance of remission of Crohn's disease: a pooled safety analysis. *Aliment Pharmacol Ther*. 29(6):643–653.
4. Campieri M, Ferguson A, Doe W, Persson T, Nilsson L, the G. (1997) Oral budesonide is as effective as oral prednisolone in active Crohn's disease. *Gut*. 41(2):209–214.
5. Gross V, Andus T, Caesar I, Bischoff SC, Lochs H, Tromm A, et al. (1996) Oral pH-modified release budesonide versus 6-methylprednisolone in active Crohn's disease. German/Austrian Budesonide Study Group. *Eur J Gastroenterol Hepatol*. Sep;8(9):905–909.
6. Greenberg GR, Feagan BG, Martin F, Sutherland LR, Thomson AB, Williams CN, et al. (1996) Oral budesonide as maintenance treatment for Crohn's disease: a placebo-controlled, dose-

- ranging study. Canadian Inflammatory Bowel Disease Study Group. *Gastroenterology*. 110(1):45–51.
7. Andus T, Gross V, Caesar I, Schulz HJ, Lochs H, Strohm WD, et al. (2003) Replacement of conventional glucocorticoids by oral pH-modified release budesonide in active and inactive Crohn's disease: results of an open, prospective, multicenter trial. *Dig Dis Sci*.48 (2):373–378.
 8. Brunner M, Ziegler S, Di Stefano AFD, Dehghanyar P, Kletter K, Tschurlovits M, et al. (2006) Gastrointestinal transit, release and plasma pharmacokinetics of a new oral budesonide formulation. *Br J Clin Pharmacol*. 61(1):31–38.
 9. Edsbäcker S, Andersson T. (2004) Pharmacokinetics of budesonide (Entocort EC) capsules for Crohn's disease. *Clin Pharmacokinet*. 43(12):803–821.
 10. Gionchetti P, Rizzello F, Poggioli G, Pierangeli F, Laureti S, Morselli C, et al. (2007) Oral budesonide in the treatment of chronic refractory pouchitis. *Aliment Pharmacol Ther*. 15;25(10):1231–1236.
 11. Dellon ES, Katzka DA, Collins MH, Gupta SK, Lan L, Williams J, et al. (2019) Safety and Efficacy of Budesonide Oral Suspension Maintenance Therapy in Patients With Eosinophilic Esophagitis. *Clin Gastroenterol Hepatol*. 17(4):666–673
 12. Reed CC, Fan C, Koutlas N, Stefanadis Z, Eluri S, Shaheen NJ, et al. (2018) Compounded Oral Viscous Budesonide is Effective and Provides a Durable Response in Eosinophilic Esophagitis. *HSOA J Gastroenterol Hepatol Res*. 7(1):2509–2515.
 13. Leuschner M, Maier KP, Schlichting J, Strahl S, Herrmann G, Dahm HH, et al. (1999) Oral budesonide and ursodeoxycholic acid for treatment of primary biliary cirrhosis: results of a prospective double-blind trial. *Gastroenterology*. 117(4):918–925.
 14. Van Gossum A, Schmit A, Peny MO. (1998) Oral budesonide for lymphocytic colitis. *Am J Gastroenterol*. 93(2):270.
 15. Schmelz R, Bornhäuser M, Schetelig J, Kiani A, Platzbecker U, Schwanebeck U, et al. (2014) Randomised, double-blind, placebo-controlled trial of oral budesonide for prophylaxis of acute intestinal graft-versus-host disease after allogeneic stem cell transplantation (PROGAST). *BMC Gastroenterol*. 26; 194:197.
 16. Elad S, Or R, Garfunkel AA, Shapira MY. (2003) Budesonide: a novel treatment for oral chronic graft versus host disease. *Oral Surg Oral Med Oral Pathol Oral Radiol Endod*. 95(3):308–311.
 17. Krishnamachari Y, Madan P, Lin S. (2007) Development of pH- and time-dependent oral microparticles to optimize budesonide delivery to ileum and colon. *Int J Pharm*. 29;338(1–2):238–247.
 18. Miehke S, Acosta MB, Bouma G, Carpio D, Magro F, Moreels T, et al. (2018) Oral budesonide in gastrointestinal and liver disease: A practical guide for the clinician. *J Gastroenterol Hepatol*.
 19. Yokoyama T, Ohta A, Motoya S, Takazoe M, Yajima T, Date M, et al. (2018) Efficacy and Safety of Oral Budesonide in Patients with Active Crohn's Disease in Japan: A Multicenter, Double-Blind, Randomized, Parallel-Group Phase 3 Study. *Inflamm Intest Dis*. 2(3):154–162.
 20. Harel S, Hursh BE, Chan ES, Avinashi V, Panagiotopoulos C. (2015) Adrenal Suppression in Children Treated With Oral Viscous Budesonide for Eosinophilic Esophagitis. *J Pediatr Gastroenterol Nutr*. 61(2):190–193.
 21. Yeoh SW. (2016) Iatrogenic Cushing Syndrome from Interaction between Ritonavir and Oral Budesonide during Direct Acting Antiviral Hepatitis C Therapy. *J Clin Exp Hepatol*. 6(3):246–249.
 22. Martin CS, Blaga C, Lambrescu IM, Fierbințeanu-Braticevici C, Fica S. (2015) Iatrogenic Cushing's syndrome related to the interaction between oral budesonide with fluvoxamine: a case report. *J Clin Pharm Ther*. 40(5):612–614.
 23. El Fakih R, Obi GA, Scholoff A, Carrum G, Kamble RT. (2012) Systemic effects of oral budesonide in hematopoietic transplant: implications of drug interaction with azoles. *Bone Marrow Transplant*.47 (10):1370–1371.
 24. Manns MP, Jaeckel E, Taubert R. (2018) Budesonide in Autoimmune Hepatitis: The Right Drug at the Right Time for the Right Patient. *Clin Gastroenterol Hepatol*.16 (2):186–189.
 25. Geier A, Gartung C, Dietrich CG, Wasmuth HE, Reinartz P, Matern S. (2003) Side effects of budesonide in liver cirrhosis due to chronic autoimmune hepatitis: influence of hepatic metabolism versus portosystemic shunts on a patient complicated with HCC. *World J Gastroenterol*.9 (12):2681–2685.
 26. Boyer TD, Haskal ZJ. (2010) the role of transjugular intrahepatic portosystemic shunt (TIPS) in the management of portal hypertension: Update 2009. *Hepatology*.51 (1):306–306.



This work is licensed under Creative Commons Attribution 4.0 License

To Submit Your Article Click Here: [Submit Manuscript](#)

DOI: [10.31579/2690-4861/012](https://doi.org/10.31579/2690-4861/012)

Ready to submit your research? Choose Auctores and benefit from:

- ❖ fast, convenient online submission
- ❖ rigorous peer review by experienced research in your field
- ❖ rapid publication on acceptance
- ❖ authors retain copyrights
- ❖ unique DOI for all articles
- ❖ immediate, unrestricted online access

At Auctores, research is always in progress.

Learn more www.auctoresonline.org/journals/international-journal-of-clinical-case-reports-and-reviews