

## Angiomatous meningioma: A rare case report

**Dr Srikanth Umakanthan MD, IFCAP<sup>1\*</sup>, Dr Wayne Mohammed MRCP<sup>2</sup>**

<sup>1</sup>Lecturer/Consultant Pathologist, Department of Paraclinical Sciences, Faculty of Medical Sciences, the University of the West Indies, Trinidad.

<sup>2</sup>Senior Lecturer/Consultant Pathologist, Department of Paraclinical Sciences, Faculty of Medical Sciences, the University of the West Indies, Trinidad.

**\*Corresponding Author:** Srikanth Umakanthan, Lecturer/Consultant Pathologist, Department of Paraclinical Sciences, Faculty of Medical Sciences, The University of the West Indies, Trinidad.

**Received date:** January 20, 2020; **Accepted date:** February 07, 2020; **Published date:** February 21, 2020.

**Citation:** Srikanth Umakanthan, Wayne Mohammed. (2020) Angiomatous meningioma: A rare case report. International Journal of Clinical Case Reports and Reviews. 2(2); DOI:10.31579/2690-4861/008.

**Copyright:** © 2020 Srikanth Umakanthan, This is an open-access article distributed under the terms of the Creative Commons Attribution License, which permits unrestricted use, distribution, and reproduction in any medium, provided the original author and source are credited.

### Introduction

Meningiomas are the most common intracranial neoplasms [1]. They arise from the meningiothelial cells of the arachnoid villi and present with headache and dizziness as most common symptoms [2]. WHO has classified meningiomas into grade 1 to 3 based on cellularity, nucleocytoplasmic ratio, mitosis and necrosis. Angiomatous meningioma is a rare subtype of WHO grade 1 meningioma which histological show meningiothelial cells with high vascular component in the tumor tissue. This subtype requires immunohistochemical evaluation to differentiate from hemangioblastomas and hemangiopericytomas [3]. This case report is of a 64-year-old male diagnosed histologically as angiomatous meningioma describing his clinical, radiologic and histopathologic features.

### Case report

A 64-year-old male presented with history of disorientation and left sided headaches for approximately 6 weeks. His general physical examination and systemic examination was uneventful. Laboratory analysis revealed no abnormality. Radiology report showed findings of left large intra-axial frontal mass with multiple cystic densities and suggested a differential diagnosis of Glioblastoma multiforme and lymphoma. The patient underwent tumoral excision and the tissue was fixed in 10% formalin solution and sent to histopathology department. Gross examination showed five fragments of tan and haemorrhagic, firm tissue with the largest tissue measuring 4.6x3.7x2.0 cms and smallest measuring 0.9x0.8x0.5cms. On cut section it showed multiple cystic areas with spongy consistency. The tissue was subjected to routine Histological processing and then the paraffin blocks were cut with thickness of 4µ and stained with haematoxylin and eosin (H&E).

Microscopic examination showed a tumor composed of meningiothelial cells and numerous vascular spaces (Figure 1).

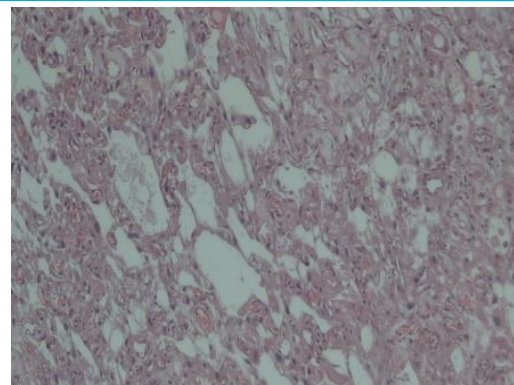


Figure 1: Tumor composed of meningiothelial cells and vascular spaces (4X, H&E stain)

The meningiothelial areas were composed of spindle and oval cells with eosinophilic cytoplasm, round to oval nuclei and hyaline globules within the spaces (Figure 2).

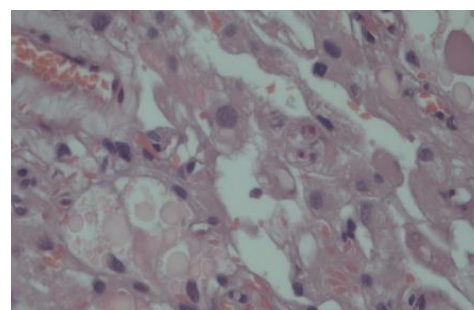


Figure 2: The meningiothelial areas were composed of spindle and oval cells with eosinophilic cytoplasm, round to oval nuclei and hyaline globules within the spaces (40X, H&E stain)

No mitotic activity or endothelial proliferation were seen. Immunohistochemistry revealed EMA positive (Figure 3) and negative for Pan-keratin and PR. These findings were of WHO grade 1-Angiomatous meningioma.

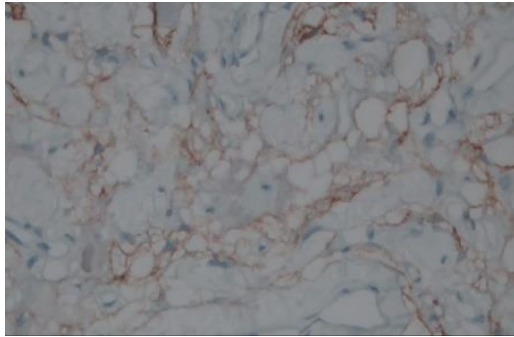


Figure 3: Tumor cells exhibiting positive immunoreactivity to EMA (40X)

## Discussion

Meningiomas constitute 20% of all intracranial neoplasms. Almost 90% of meningiomas are benign.<sup>3</sup> The WHO classify grade I meningiomas as the most frequent subtype. Atypical meningiomas (WHO grade II) and anaplastic meningiomas (WHO grade III) are infrequent, aggressive and have a significantly higher recurrence rate following therapy [4]. Angiomatous meningiomas are meningiomas with vascular component exceeding 50% of the tumor area. This subtype constitutes only 2.1% of all meningiomas [5]. This subtype of meningioma have similar clinical features as of benign meningiomas. The mean age of onset been 51.8 years old and occurrence higher in males. Anatomically, angiomatous meningioma is located most commonly over cerebral convexity and are dural based lesions [6]. Headache and dizziness are the most common presenting symptoms as in our case followed by temporary loss of consciousness, epilepsy, nausea and vomiting. Headaches are not a specific symptom of meningioma, hence imaging modalities are important for evaluating such patients. MRI and CT are most frequently used imaging modalities. Typical meningiomas show a characteristic dural tail and mottling indicating high vascularity of the tumor [7, 8]. Angiography can be done to exclude other vascular conditions such as aneurysm and other cerebrovascular diseases [9]. Radiologically, meningiomas show no additional characteristic features for its subtyping however, angiomatous meningiomas show perilesional edema. This is attributed to increased capillary permeability and VEGF secretion by the hyper vascular tumor [10].

Due to the limitations in only imaging studies, subtyping of meningiomas mainly relies on its histopathologic features including immunohistochemistry and electron microscopy [11]. Meningiomas with high vascularity should be evaluated for angiomatous meningioma, hemangioblastoma and hemangiopericytomas [12]. Martin et al. classified angiomatous meningiomas based on diameter of vascular channels into two subtypes, namely macrovascular with >50% of vessels having larger than 30µm in diameter and microvascular subtype in which >50% of vessels were smaller than 30µm in diameter [13]. Microvascular subtype of angiomatous meningiomas and hemangioblastomas are difficult to differentiate hence needing IHC and EM for confirmatory diagnosis. Angiomatous meningiomas are immunoreactive to EMA, vimentin, S100 and PR. In our case EMA was positive [14]. Treatment

wise total excision of the tumor remains the choice as followed in our case [2].

## Conclusion

Angiomatous meningiomas are rare variant of WHO grade I meningiomas with few distinct clinical, radiological, histopathological and immunohistochemical features. A complete evaluation and multidisciplinary approach is required to distinguish this subtype of meningiomas from other vascular lesions in the CNS.

## References

1. Ibebuike K, Ouma J, Gopal R. (2013) Meningiomas among intracranial neoplasms in Johannesburg, South Africa: prevalence, clinical observations and review of the literature. *African Health Sciences* 13(1): 118 – 121.
2. Zhiguo Liu, Chuanwei Wang, Hongwei Wang, Yunyan Wang, Jian Yi Li, Yuguang Liu. (2013) Clinical characteristics and treatment of angiomatous meningiomas: a report of 27 cases. *Int J Clin Exp Pathol*;6(4):695-702.
3. Juyoung Hwang, Doo-Sik Kong, Ho Jun Seol, Do-Hyun Nam, Jung-Il Lee, Jung Won Choi. (2016) Clinical and radiologic characteristics of angiomatous meningioma. *Brain Tumor Res Treat* 4(2):94-99.
4. Kleihues P, Cavenee WK. 2000 World Health Organization classification of tumors. Pathology and genetics of tumors of the nervous system. Lyon: IARC Press. p.175-193.
5. Hasselblatt M, Nolte KW, Paulus W. (2004) Angiomatous meningioma: a clinicopathologic study of 38 cases. *Am J Surg Pathol*.28:390–393.
6. Daniel Lyndon, Joseph A. Lansley, Jane Evanson and Anant S. Krishnan. (2019) Dural masses: meningiomas and their mimics. *Insights into Imaging*10:11.
7. Kitamura Y, Akiyama T, Sasaki H, Hayashi Y, Yoshida K. (2013) Optic nerve seeding of atypical meningiomas presenting with subacute visual loss: 2 case reports with genetic characterization. *J Neurosurg*.119:494–498.
8. Rao S, Rajkumar A, Kuruville S. (2008) Angiomatous meningioma: A diagnostic dilemma. *Indian J Pathol Microbiol*.51:53-55.
9. Tahir MZ, Shamim MS, Chishti KN. (2009) Recurrent atypical meningioma seeding to surgical scar. *Neurol India*.57:222–224.
10. Whittle IR, Smith C, Navoo P, Collie D. (2004) Meningiomas. *Lancet*.363:1535–1543.
11. Dietzmann K, von BP, Warich-Kirches M, Kirches E, Synowitz HJ, Firsching R. (1997) Immunohistochemical detection of vascular growth factors in angiomatous and atypical meningiomas, as well as hemangiopericytomas. *Pathol Res Pract*.193:503–510.
12. Martin H, Kay WN, Werner P. (2004) Angiomatous meningioma - A clinicopathologic study of 38 cases. *Am J Surg Pathol*;28:390-393.
13. Tamiya T, Ono Y, Matsumoto K, Ohmoto T. (2001) Peritumoral brain edema in intracranial meningiomas: effects of radiological and histological factors. *Neurosurgery*.49:1046-1051.
14. Stacey E. (2004) Mills Sternberg's Diagnostic Surgical Pathology, 4 th ed. Lippincott William and Wilkins. p. 460-481.