

The Dramatic Reversal of Acute Pulmonary Embolism-Induced Corrected Qt-Interval Prolongation with Bisoprolol; a Case Report

Yasser Mohammed Hassanain Elsayed

Critical Care Unit, Fraskour Central Hospital, Damietta Health Affairs, *Egyptian Ministry of Health (MOH)*, Damietta, Egypt

Corresponding Author: Yasser Mohammed Hassanain Elsayed, Critical Care Unit, Fraskour Central Hospital, Damietta Health Affairs, Egyptian Ministry of Health (MOH), Damietta, Egypt

Received Date: February 13, 2020; **Accepted Date:** February 15, 2020; **Published Date:** March 11, 2020.

Citation: Hassanain Elsayed Y M. (2020) The Dramatic Reversal Of Acute Pulmonary Embolism-Induced Corrected Qt-Interval Prolongation with Bisoprolol; A Case Report. *Journal of Clinical Case Reports and Studies*, 1(1): [10.31579/ 2690-8808/004](https://doi.org/10.31579/2690-8808/004)

Copyright: © 2020. Yasser Mohammed Hassanain Elsayed. This is an open-access article distributed under the terms of the Creative Commons Attribution License, which permits unrestricted use, distribution, and reproduction in any medium, provided the original author and source are credited.

Abstract

Rationale: Acute pulmonary embolism is one of the most serious cardiovascular conditions. QT-interval prolongation represents a hallmark for *torsades de pointes* or polymorphic ventricular tachycardia and sudden cardiac death. So, identifying the QT-interval prolongation inducer considered very important.

Patient concerns: A 55-year-old housewife woman presented with a thrombophilic acute pulmonary embolism-induced marked electrocardiographic QT-interval prolongation.

Diagnosis: Acute pulmonary embolism-induced QT-interval prolongation.

Interventions: Electrocardiography, computed tomography pulmonary angiogram, and echocardiography.

Lessons: Bisoprolol may be helping in the reversal QT-interval prolongation. QT-interval prolongation that is a hallmark for *torsades de pointes*, and serious ventricular tachyarrhythmias with subsequent sudden cardiac death. Acute pulmonary embolism-induced QT-interval prolongation should be put among the acquired causes of the long QT syndrome.

Outcomes: Dramatic response for both electrocardiographic and clinical signs of acute pulmonary embolism-induced QT-interval prolongation post-bisoprolol. Why don't we use bisoprolol in the management of acute pulmonary embolism-induced electrocardiographic marked QT-interval prolongation?

Keywords: Dramatic reversal of acute pulmonary embolism; Induced corrected QT-interval prolongation; Bisoprolol

Introduction

Pulmonary embolism and deep venous thrombosis are the two most important manifestations of venous thromboembolism (VTE), which is the third most common and frequent life-threatening cardiovascular disease [1,4] with an overall annual incidence of 100–200 per 100 000 inhabitants [4]. According to the Centers for Disease Control and Prevention (CDC), the annual incidence of VTE is one or two per 1,000 persons, and the overall mortality rate is between 60,000 and 100,000 annually [2]. One-third of patients with VTE will have a recurrence within 10 years [2]. Approximately one-third of patients with VTE present with pulmonary embolism (PE), and two-third present with *deep vein thrombosis* (DVT) [1]. VTE is provoked in the presence of a temporary or reversible risk factor (such as surgery, trauma, and immobilization, pregnancy, and oral contraceptive use or hormone replacement therapy) within the last 6 weeks to 3 months before diagnosis, and 'unprovoked' in the absence thereof. PE may also occur in the absence of any known risk factor [4]. VTE may be lethal in the acute phase or lead to chronic disease and disability, but it is also often preventable [4]. PE is a common and potentially life-threatening condition associated with considerable morbidity and mortality [3]. An estimated 10 percent of symptomatic PE causes death within one hour of onset [3]. The constellation of symptoms and signs of PE are suggestive but do not have the necessary specificity

or sensitivity to rule in or out the diagnosis. When the diagnosis is entertained, clinical stability and pre-test probability will dictate the diagnostic approach [6]. All patients with possible PE should have clinical probability assessed and documented [5]. An alternative clinical explanation should always be considered at presentation and sought when PE is excluded [5]. Blood d-dimer assay should only be considered following the assessment of clinical probability [5]. The d-dimer assay should not be performed in those with a high clinical probability of PE. A negative d-dimer test reliably excludes PE in patients with low or intermediate clinical probability; such patients do not require imaging for VTE [5]. Computed tomography pulmonary angiogram (CTPA) is now the recommended initial lung imaging modality for non-massive PE. Patients with a good quality negative CTPA do not require further investigation or treatment for PE [5]. CTPA or echocardiography will reliably diagnose clinically massive PE [5]. The electrocardiograph (ECG) is often abnormal in PE [7]. Almost 33% of patients have normal ECG [7]. Lack of specificity and sensitivity of ECG signs is key in the diagnosis of PE [7]. The most common ECG findings in PE are sinus tachycardia, complete or incomplete right bundle branch block, anteroseptal T-wave inversion/ST-elevation or depression, low QRS-complex voltage, S1Q3T3 pattern, and right axis deviation [7]. Anticoagulation is the mainstay of VTE treatment [1]. Inpatient treatment

of VTE begins with parenteral agents, preferably low-molecular-weight heparin [1]. The presence of persistent—as opposed to major, temporary—risk factors may affect the decision on the duration of anticoagulation therapy after the first episode of PE [4]. Hemodynamically unstable patients with low bleeding risk may benefit from thrombolytic therapy [1]. Thrombolysis is the first-line treatment for massive PE [5].

The QT-interval is an electrocardiographic phase; it is measured in milliseconds (ms) from the beginning of the QRS-complex until the end of the T-wave [8]. The QT-interval represents the ventricular depolarization followed by the ventricular repolarization. QT-prolongation is used as a marker for a prolongation of the ventricular repolarization time [8]. A QTc-interval higher than 450 ms in adult males and higher than 470 ms in adult females is defined as prolonged QTc [8]. Because the QT-interval varies with the heart rate (HR), the corrected QT-interval (QTc-interval) should be used. Various correction formulas are available for this correction. The Bazett formula is the easiest correction and most used in clinical practice [8]. While the degree of QT prolongation is recognized as an imperfect biomarker for proarrhythmic risk, in general, there is a qualitative relationship between QT prolongation and the risk of torsade de Pointes (TdP) [9]. A prolonged QTc-interval and delay in cardiac repolarization can lead to ventricular arrhythmias (TdP) and sudden cardiac death [8, 10]. QTc value above 500 ms or an increase of 60 ms (20% from baseline) is strongly associated with arrhythmias and TdP [10]. For risk of sudden cardiac death, "borderline QTc" in males is 431–450 ms; and, in females, 451–470 ms. An "abnormal" QTc in males is a QTc above 450 ms; and, in females, above 470 ms [11]. All patients with long QT syndrome (LQTS) should avoid drugs that prolong the QT interval or that reduce their serum potassium or magnesium levels [12]. Beta-blockers are drugs of choice for patients with LQTS [13]. The efficacy in preventing cardiac events in approximately 70% of patients with LQTS, whereas cardiac events continue to occur despite beta-blocker therapy in the remaining 30% [14]. The protective effect of beta-blockers is related to their adrenergic blockade, which diminishes the risk of cardiac arrhythmias and reduces the QT interval in some patients [14].

Bisoprolol is a synthetic β_1 -selective (cardioselective) adrenoceptor blocking agent without significant membrane stabilizing activity or intrinsic sympathomimetic activity [15]. Bisoprolol is used to treat hypertension, arrhythmias, ischemic heart diseases, myocardial infarction, and compensated congestive heart failure [16]. The most prominent effect of bisoprolol is the negative chronotropic effect, resulting in a reduction in resting and exercise heart rate [15].

Electrophysiology studies have demonstrated that bisoprolol significantly decreases heart rate, increases sinus node recovery time, prolongs AV node refractory periods, and with rapid atrial stimulation, prolongs AV nodal conduction [15]. The absolute bioavailability after a 10 mg dose is greater than 80%. Binding to serum proteins is approximately 30%. Peak plasma concentrations occur within 2 - 4 hours of dosing with 5 to 20 mg, and mean peak values range from 16 ng/mL at 5 mg to 70 ng/mL at 20 mg. Bisoprolol is eliminated equally by renal and non-renal pathways. Bisoprolol is contraindicated in patients with cardiogenic shock, Acute or decompensated heart failure, second or third-degree A-V block, right ventricular failure secondary to pulmonary hypertension, and sinus bradycardia [15, 16]. The most frequently reported adverse reactions were: arthralgia (2.7%), dizziness (3.5%),

headache (10.9%), insomnia (2.5%), diarrhea (3.5%), nausea (2.2%), coughing (2.5%), pharyngitis (2.2%), rhinitis (4.0%), sinusitis (2.2%), URT infection (5.0%), fatigue (8.2%), and peripheral edema (3%) [15].

Case presentation

A 55-year-old housewife Egyptian woman complaint of sudden transient loss of consciousness with acute central chest pain, and positional dizziness. The patient had a history of recurrent of two right, one left lower limb DVT episodes, and one attack of PE. Currently, the patient was admitted to the critical care unit. Otherwise recurrent VTE and hypertension on captopril/ hydrochlorothiazide (25/12.5mg oral tablet, once daily), the patient denied any history of other cardiac, thyroid, or other relevant diseases. Upon examination, the patient appeared irritable, sweaty, pale, and tachypneic. His vital signs were as follows: blood pressure of 180/100 mmHg, pulse rate of 85/bpm; and regular, the temperature of 36.5°C, respiratory rate of 23/min and, oxygen saturation (pulse oxymetry) of 94%. Other examination data were unremarkable. Blood pressure was initially controlled with captopril (25mg oral tablet, once daily) until blood pressure: 140/140 mmHg reached then was continued twice daily. Oxygen inhalation (5L/min), heparin sulfate (5000 unit, IVB), enoxaparin (80 mg, SC twice daily) warfarin was given. The initial workup was: ECG that showed normal sinus rhythm (Figure 1-A). Later serial ECG tracings showed QT/QTc prolongations (Figure 1-B, C). The patient received bisoprolol (5mg oral tablet, once daily). The last ECG tracings one day after introducing bisoprolol were showing the reversal of QT/QTc prolongation (Figure 1-D). The investigations done were: troponin test, electrolyte levels, complete blood count, thyroid studies, random blood sugar, and echocardiography with no detectable abnormal results. D-dimer was very high (4246 ng/mL). Serial INR follow up had happened until achieved 2.75. CTPA showed partially thrombosed left main pulmonary, bilateral lobar, segmental, and sub-segmental branches indicating PE (Figure 2). Complete recovery was achieved and the patient was discharged *within 8 days from admission* with no problem. The patient continued on oral warfarin for life (5 mg, once-daily tablet) with follow up with INR. Bisoprolol (5mg oral tablet, once daily) with captopril (25 mg oral tablet, once daily) was added with discharge therapy. Planning for future *thrombophilia* investigation studies was recommended.

Discussion

• Overview:

- In the current case, there was acute pulmonary embolism-induced marked electrocardiographic QT/ corrected QT-interval prolongation.
- Normal sinus rhythm in initial ECG tracings did not rule out the acute PE.
- Recurrent DVTs and PE indicate thrombophilia.
- B-blocker bisoprolol was added for the treatment of acute PE-induced QT/QTc prolongation.
- Very high d-dimer (4246 ng/mL) not indicated specificity but indicate a poor prognosis.
- Enoxaparin injection transiently postponed until blood pressure control.
- Warfarin was added for life due to recurrent thromboembolism with serial INR follow up.

- Hydrochlorothiazide and diuretics not preferable with thrombophilia due to volume depletion and hemoconcentration.

- I can't **compare** the current case with similar conditions. There are no similar or known cases with the same management for near comparison.

- **Study question here;** how did QT/corrected QT-interval prolongation finally reversed after oral bisoprolol?

- **The primary objective** for my case study was induced marked electrocardiographic QT/ corrected QT-interval prolongation by acute pulmonary embolism.

- **The secondary objective** for my case study was the appearance of clearing the clinical impact of bisoprolol on electrocardiographic QT/ corrected QT-interval prolongation.

- **Limitations of the study:**

- There are no known limitations in the study. But, contraindications of b-blockers are possible limitations.

- **Recommendations**

- It is recommended to widening the research in clearing the effect of bisoprolol on QT/corrected QT-interval prolongation. Also, it is recommended to extend the research on the impact of other b-blockers on QT/corrected QT-interval prolongation.

- **Conclusions**

- Acute PE induced-QT/QTc prolongation should be included among the acquired causes of the LQTS.

- B-blocker should be added for prophylaxis and treatment acute PE-induced QT/QTc prolongation to avoid TdP *and* serious ventricular tachyarrhythmias with subsequent sudden cardiac death. This need further larger studies will need for confirmation.

- Prolonged QT/QTc is considered a novel predictor for evaluating outcomes in acute PE.

- Warfarin should be added for life in recurrent thromboembolism with serial INR follow up.

- Planning for future *thrombophilia* investigation studies was recommended.

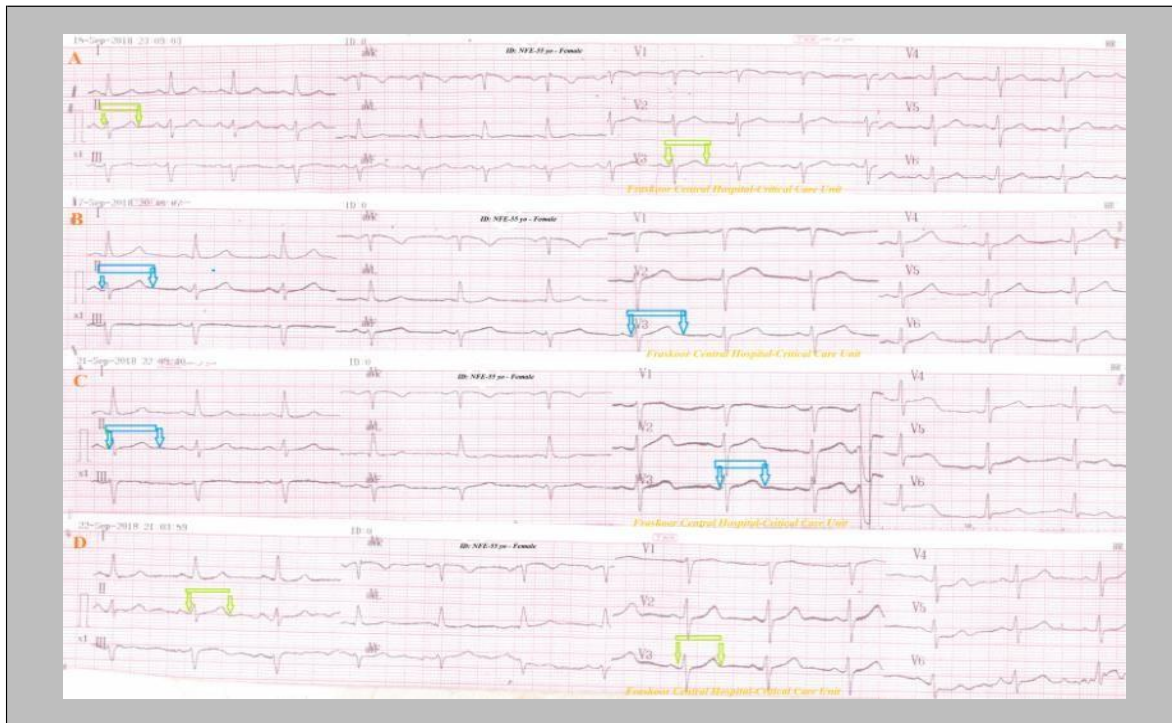


Figure 1: Serial ECG tracings showing; **A. tracing;** Showing NSR with (VR:85,QT:381 ms,QTc:453 ms):(green arrows) **B. tracing;**(VR:61 bpm,QT:480 ms,QTc:487 ms) **C. tracing;** (VR:67 bpm,QT:473 ms, QTc:502 ms) :(blue arrows) **D. tracing;** (VR:66, bpm QT:442 ms,QTc:464 ms) :(green arrows).

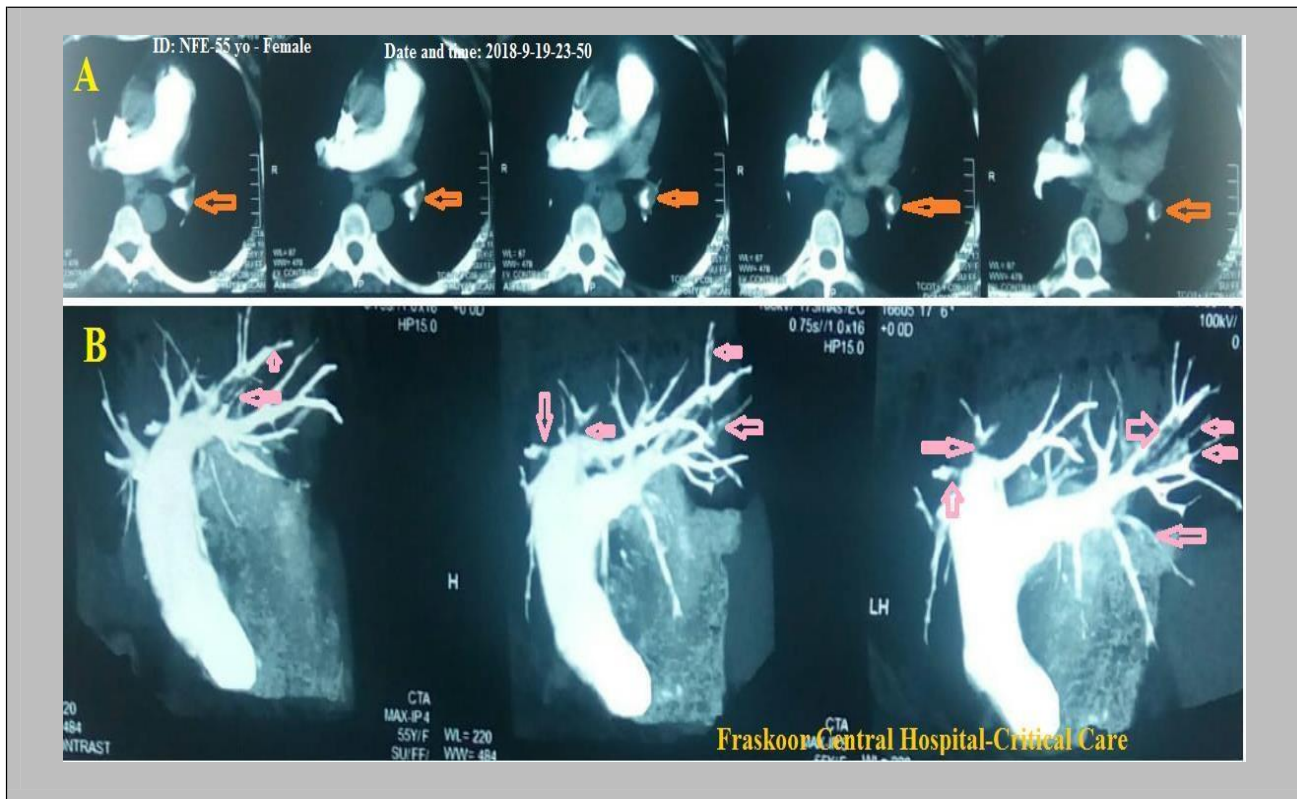


Figure 2: CTPA; a: showing partially thrombosed left main pulmonary (orange arrows). b: showing thrombosed segmental, and sub-segmental branches (rose arrows).

Conflicts of interest: There are no conflicts of interest.

Acknowledgment

I wish to thank Dr. Ameer Mekki; M.sc. for technical support and critical care unit nurses who make extra ECG copy for helping me.

Abbreviations

CDC: Centers for Disease Control and Prevention

CTPA: computed tomography pulmonary angiogram

DVT: Deep vein thrombosis

ECG: Electrocardiography

HR: heart rate

INR: International normalized ratio

IVB: Intravenous bolus

LQTS: Long QT syndrome

PE: Pulmonary embolism

TdP: Torsade de Pointes

VTE: venous thromboembolism

References

1. Wilbur J, Shian B. (2017). Deep Venous Thrombosis and Pulmonary Embolism: Current Therapy. *Am Fam Physician*, 95(5):295-302. PMID: 28290648.
2. Centers for Disease Control and Prevention. Venous thromboembolism (blood clots). Data and statistics. June 22, 2015.
3. Ritesh Agarwal, Subhash Varma. (2009). Acute pulmonary embolism. *Eastern J Med*. 14(2): 57-68.
4. Stavros V. Konstantinides, Adam Torbicki, Giancarlo Agnelli, et al. (2014) ESC Guidelines on the diagnosis and management of acute pulmonary embolism The Task Force for the Diagnosis and Management of Acute Pulmonary Embolism of the European Society of Cardiology (ESC). *EHJ*, 35, 3033–3080.
5. British Thoracic Society Standards of Care Committee Pulmonary Embolism Guideline Development Group. BTS guidelines for the management of suspected acute pulmonary embolism. *Thorax*. 2003 June; 58(6):470–484.
6. hrombosis Canada. Pulmonary embolism: Diagnosis and management. *Thrombosis Canada...* 2013; 1-9
7. Mehmet Mustafa Cana, Esra Can. Burak Turan, Cihangir Kaymaz. (2010). Letter to the Editor. Atipic electrocardiographic manifestation of pulmonary embolism. *Resuscitation*, 81:1738–1739.
8. Eline Vandael Veerle Foulon. (2017). Drug-induced QTc-prolongation: risk management in a community pharmacy. *J Malta College Pharm Pract*, 23:7-12.
9. Giorgi MA, Bolaños R, Gonzalez CD, Di Girolamo G. (2010). QT interval prolongation: Preclinical and clinical testing

- arrhythmogenesis in drugs and regulatory implications. *Curr Drug Saf*, 5:54–7. PMID: 20210719
10. Antonio Ventriglio, Alessandro Gentile, Eleonora Stella, and Antonello Bellomo. (2015). metabolic issues in patients affected by schizophrenia: clinical characteristics and medical management. *Front Neurosis*, 9: 297.
 11. Medscape CRM News. QTc Prolongation and Risk of Sudden Cardiac Death: Is the Debate Over?. *Medscape*, 2006.
 12. Heemskerk CPM, Pereboom M, van Stralen K, et al. (2018). Risk factors for QTc interval prolongation. *Eur J Clin Pharmacol*, 74(2):183-91.
 13. Duncan G, Firth K, George V, et al. (2017). Drug-mediated shortening of action potentials in LQTS2 human induced pluripotent stem cell-derived cardiomyocytes. *Stem Cells Dev*, 1. 26(23):1695-705.
 14. Ali A Sovari. (2017). Long QT Syndrome Treatment & Management. *Medscape* Available online: <https://emedicine.medscape.com/article/157826-treatment#showall> Accessed on
 15. Bisoprolol Fumarate. APO-BISOPROLOL, PRODUCT MONOGRAPH, 2004.
 16. 2015 BNF 70. Bisoprolol fumarate. Blood pressure conditions. *BNF70*.September 2015–March 2016; 142.



This work is licensed under Creative Commons Attribution 4.0 License

To Submit Your Article Click Here: [Submit Manuscript](#)

DOI: [10.31579/CCRS.2020/004](https://doi.org/10.31579/CCRS.2020/004)

Ready to submit your research? Choose Auctores and benefit from:

- ❖ fast, convenient online submission
- ❖ rigorous peer review by experienced research in your field
- ❖ rapid publication on acceptance
- ❖ authors retain copyrights
- ❖ unique DOI for all articles
- ❖ immediate, unrestricted online access

At Auctores, research is always in progress.

Learn more www.auctoresonline.org/journals/clinical-case-reports-and-studies