

Case Report: The Importance of Dermoscopy in Umbilical Tumor

Patrícia Amaral Couto MD^{1*} and Luciana Mendes dos Santos MD¹

Department of Dermatology¹, University Hospital Getúlio Vargas, Federal University of Amazonas, Amazonas, Brasil.

***Corresponding author:** Patrícia Amaral Couto, MD. Serviço de Dermatologia, Hospital Universitário Getúlio Vargas, Avenida Apurina, 4 - Praça 14 de Janeiro, Manaus - AM, 69020-210, Tel: +55 92 981820744, Brasil.

Received date: December 16, 2019; **Accepted date:** March 09, 2020; **Published date:** March 16, 2020.

Citation: Patrícia A Couto, Luciana M D Santos.(2020) The Importance of Dermoscopy In Umbilical Tumor. International Journal of Clinical Case Reports and Reviews. 2(2); DOI:10.31579/2690-4861/006

Copyright: ©2020 Patrícia Amaral Couto, This is an open-access article distributed under the terms of the Creative Commons Attribution License, which permits unrestricted use, distribution, and reproduction in any medium, provided the original author and source are credited.

Abstract

The pelvic endometriosis is considered a relatively common, benign, estrogen-dependent disease associated with complaints of pelvic pain and infertility, affecting 6% to 10% of women of reproductive age. The etiopathogenesis of the disease is based on some theories and hypotheses. Classical theories include the hypothesis of migratory pathogenesis by retrograde menstrual flow, the theory of celomic metaplasia, the theory of embryonic rest or even iatrogenic deposition during abdominal surgical procedures [1].

Key words : cutaneous endometrioma, primary endometriosis umbilical, dermoscopy

Introduction

The pelvic endometriosis is considered a relatively common, benign, estrogen-dependent disease associated with complaints of pelvic pain and infertility, affecting 6% to 10% of women of reproductive age. The etiopathogenesis of the disease is based on some theories and hypotheses. Classical theories include the hypothesis of migratory pathogenesis by retrograde menstrual flow, the theory of celomic metaplasia, the theory of embryonic rest or even iatrogenic deposition during abdominal surgical procedures [1].

This disease can affect various organs such as the skin, navel, subcutaneous tissue, pelvic peritoneum, fallopian tubes, ovaries, urinary tract, bladder, heart, kidney, lung, liver, pancreas, muscles, brain, and others, which currently characterize it as a multisystem disease. Endometriotic lesions are more frequent in the peritoneum and pelvic organs, especially in the ovaries, followed by the rectovaginal septum. It is less frequent in extrapelvic regions, such as the gastrointestinal and urinary tract, extremities, subcutaneous tissue and abdominal wall [1].

Cutaneous endometriosis is a rare disease, but it is the most common extrapelvic location. It is classified as to its origin, in primary forms, spontaneous, rare and unrelated to previous abdominal surgeries; and secondary, which evolve with endometrioma after surgical procedures such as hysterectomies, cesarean sections, laparotomies, episiotomy, and videolaparoscopic surgeries. Secondary forms, which are the most common, are represented by cases arising from previous surgical scars of hysterectomies, cesarean sections, laparotomies and episiotomy. Spontaneous umbilical endometriosis is a very rare disease with few reports in the literature [1].

Umbilical endometriosis is a rare entity, first case reporting in 1886, and about 100 cases were reported in medical literature. The estimated incidence is 0.5% and 1% of all patients with extragenital endometriosis, and this percentage includes both secondary and primary form. Secondary form is most common after laprotomy and laparoscopy, which has been

proposed for pathogenesis. Primary is not associated with iatrogenic and unknown pathophysiology [2, 3].

Case Report

We have an unusual case of primary, spontaneous umbilical endometriosis. Clinical presentation was a 40-years old woman came to our service complaining about a 4 year slowly growing lesion in the umbilical area. It was a painless 2cm x2 cm shiny blackish-brown nodule. No episodes of spontaneous bleeding in her menstrual cycle or other gynecologic symptoms. She had a cesarean surgery 12 years ago, no complications during surgery. The patient denied any previous videolaparoscopic surgery or other abdominal procedures around the belly button.

In the case presented, the diagnostic hypotheses were melanotic melanoma, Sister Maria José's node, cutaneous metastasis, and umbilical endometrioma. In the clinical suspicion of endometrioma, detailed lesion dermoscopy was performed, skin biopsy and imaging exams: USG, MRI [3]. The request was made from the gynecology consultation of our hospital to rule out the possibility of intrabdominal focus and follow-up for infertility investigation.

Dermoscopic appearance in polarized light dermoscopy showed polypoid projections in white color, grayish area around these structures, some central black dots and mild erythema on the periphery of the lesion [4, 5]. Curiously, there is presence of some condensation in the glass of the dermatoscopic appliance due to glandular tissue analysis.

Histological sections reveal cystic shaped skin fragments, delineated by a single layer of cylindrical cells, presence of hemosiderin, inflammatory cells and fibrosis. Immunohistochemistry analysis, there was strogen receptors in cylindrical cell nucleus and C10 crowned in summary cells [6]. Imaging exams were within normal range, without any change. The diagnosis of primary umbilical endometriosis was established with these consistent finds.

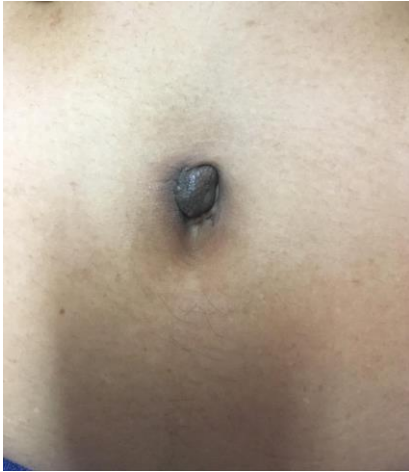

Fig 1:Blackish-brown umbilical nodule with light brown area around.

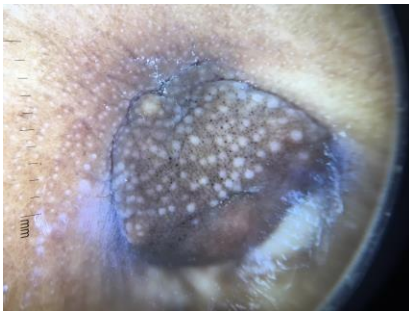


Fig 2:Dermoscopy show some polypoid projections in white color, a grayish-brown in central area and reddish-brown color in the periphery. Note the evaporation on the glass showing the glandular pattern of the lesion.

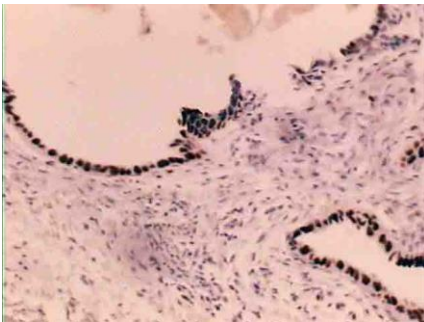


Fig:3:Immunohistochemistry reveals estrogen receptor expression by epithelial cells and CD10 in stromal cells.

Conclusion

During the bibliographic review in cases that have already been published the umbilical endometrioma dermoscopy no single pattern or pathognomonic signal was observed in dermoscopy of cutaneous endometrioma. There are variations in the lesion evolution time, menstrual cycle period, patient phototype and implantation site. However, the dermoscopic analysis by an experienced dermatologist is important to rule out malignant diseases such as melanoma and Sister Mary Joseph's nodule. The early diagnosis is of great importance to correct treatment and subsequent to avoid patient infertility, remembering the importance of the multidisciplinary team for the care of these patients.

Reference

1. Latcher, J. W. (1953). Endometriosis of the umbilicus. *American Journal of Obstetrics and Gynecology*, 66(1), 161–168.
2. Calagna G, Perino A, Chianetta D, Vinti D, Triolo MM, Rimi C, et al. (2015) Primary umbilical endometrioma: analyzing the pathogenesis of endometriosis from an unusual localization. *Taiwanese Journal of Obstetrics and Gynecology*.;54(3):306-12.
3. Renuka M, Preeti S. (2016) *International Journal of Reproduction, Contraception, Obstetrics and Gynecology* Jul;5(7):2453-2456
4. Boesgaard-Kjer, D., Boesgaard-Kjer, D., & Kjer, J. J. (2017). Primary umbilical endometriosis (PUE). *European Journal of Obstetrics & Gynecology and Reproductive Biology*, 209, 44–45.
5. Jaime TJ, Ormiga P, Leal F, Nogueira OM, Rodrigues N, Anais Bras Dermatolog. 2013 Umbilical endometriosis: report of a case and its dermoscopic features. *Jan-Feb;88(1):121-124*.
6. Tognetti L, Cinotti E, Tonini G, et al. (2018) New findings in non-invasive imaging of cutaneous endometriosis: Dermoscopy, high-frequency ultrasound and reflectance confocal microscopy. *Skin Res Technol*.00:1–4.
7. Mechsner S, Bartley J, Infanger M, Loddenkemper, C Herbel, J Ebert AD. (2009) Clinical management and immunohistochemical analysis of umbilical endometriosis. *Arch Gynecol Obstet*. Aug; 280(2):235-42.