

Bladder and Urothelial Carcinoma by Response of Serum Tumor Markers

Prashant Verma*, Laxmisamhitha Bontha

Memorial Hospital in Indira Nagar, Lucknow.

*Corresponding Author : Prashant Verma, Memorial Hospital in Indira Nagar, Lucknow., Email: pverma@umaryland.edu

Received date: June 30,2017; Accepted date : August 20,2017; Published date: September 04,2017.

Citation for this Article: Prashant Verma. Bladder and Urothelial Carcinoma by Response of Serum Tumor Markers., J Cancer Research and Cellular Therapeutics, Doi: [10.31579/2640-1053/015](https://doi.org/10.31579/2640-1053/015)

Copyright : © 2017 Prashant Verma. This is an open-access article distributed under the terms of The Creative Commons Attribution License, which permits unrestricted use, distribution, and reproduction in any medium, provided the original author and source are credited.

Abstract

Tumor markers such as beta Human Chorionic Gonadotropin (bHCG) and Carboxyhydrate Antigen 19-9 (CA19-9) have long been associated with bladder cancer and although their expression is associated with poorer oncological outcomes, they have little role in the routine clinical management of this disease. Recent advances in engineered antibody technology have lead to renewed interest in these markers as potential targets for new therapeutics. Here we report the case of a patient with locally advanced bladder cancer and the response of serum bHCG and CA19-9 to endoscopic resection and then radical cystectomy and serves to highlight how these tumor markers might be used to measure treatment effect.

Keywords

Urothelial Carcinoma; Cystectomy; Tumor Markers; CA19-9; bHCG

Introduction

The use of serum tumor markers such as beta human chorionic gonadotropin (bHCG) and carboxyhydrate antigen 19-9 (CA19-9) in the routine evaluation for bladder cancer remains undefined despite their association with aggressive disease characteristics [1,2]. With the emergence of antibody-based therapy for solid malignancies in the form of monoclonal antibodies and antibody-drug conjugates [3], there has been renewed interest in these little used biomarkers as they may constitute tumor specific targets at which chemotherapeutic payloads can be directed, or allow for specialized imaging techniques through engineered antibodies.

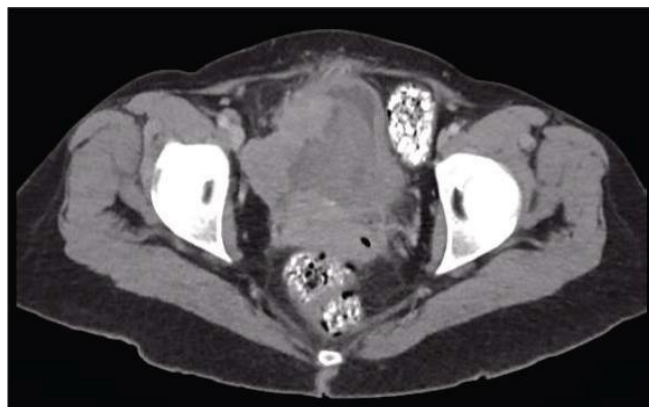Pre-clinical data suggests that both CA19-9 and bHCG might be targeted with such new therapeutics in bladder cancer, and whilst studies have previously focused on their utility as prognostic or screening biomarkers, their response to therapy in bladder cancer is not well known. In their report, Malkhasyan and colleagues describe a case of metastatic bladder urothelial carcinoma and the dramatic response of serum bHCG to systemic chemotherapy [4]. In a similar report but in the context of surgical excision, we present a case of locally advanced urothelial carcinoma of the bladder and the response of both serum bHCG and CA19-9 to endoscopic resection followed by radical cystectomy.

Case Study

A 51 year old female was referred to our service with a pelvic mass. She had originally presented to her general practitioner and subsequently our emergency department with several months of hematuria and symptomatic anemia requiring blood transfusion. She had a past history of hypertension and irregular menstruation, with no significant occupation exposure or history of tobacco smoking. There was no family history of malignancy.

After blood transfusion with three units of packed red blood cells, her hemoglobin level improved from 40g/L to 67g/L. Imaging with pelvic ultrasound and computed tomography (CT) with contrast revealed a 4.6 × 4.8 cm mass arising from the bladder (Figure 1) which extended to the right vesico-ureteric junction as well as marked hydronephrosis and hydroureter .

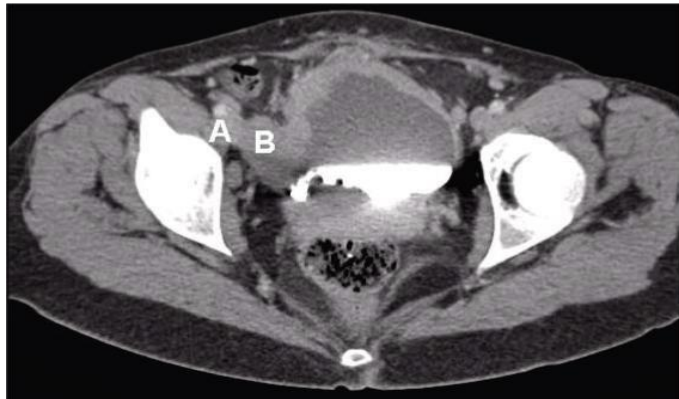
Other staging investigations including CT chest and whole body bone scintigraphy showed no evidence of distant metastasis. No staging positron emission tomography (PET) scan was ordered at this time. Due to an uncertain initial diagnosis and the prospect of gynecological malignancy, tumor markers to evaluate a pelvic mass had already been ordered and revealed a CA19-9 of 53 kU/L (Reference range 0-35 kU/L), and bHCG of 5 U/L (Reference range 0-2 U/L). Other markers including alpha fetoprotein (AFP) (3.8 ug/L; Reference range 0-10 ug/L) were within normal range.



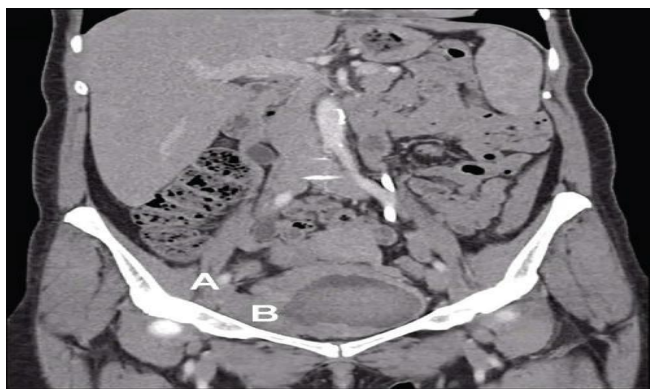
CT scan axial view of right sided bladder mass prior to TURBT.

At cystoscopy an extensive solid and papillary tumor that encompassed the entirety of the right lateral wall and extended to the dome was encountered and the patient proceeded to transurethral resection of bladder tumor (TURBT). The tumor was incompletely resected and follow-up CT scans showed the extent of residual tumor as well as the proximity to the iliac artery and vein (Figure 2A and 2B). It also showed ongoing right sided hydronephrosis and hydroureter, which was unchanged from the previous CT scan. Histopathological examination of the tumor chips demonstrated high grade muscle invasive urothelial carcinoma with squamous cell differentiation.

Approximately $8 \times 5 \times 1$ cm of the tumor was resected during the TURBT. Tumor markers remained elevated following TURBT (CA19-9: 53 kU/L, BHCG: 7 U/L).



Post TURBT CT scan axial view. (A - Right external iliac artery; B - Right external iliac vein)



Post TURBT CT scan coronal view. (A - Right external iliac artery; B - Right external iliac vein)

The patient continued to be symptomatic with transfusion dependent haematuria. Her case was presented as the urology multi-disciplinary team meeting (consisting of urologists, oncologists, radiologists and pathologists) for further management. Due to the ongoing hydronephrosis and bleeding, it was felt she was not a suitable candidate for neoadjuvant chemotherapy, instead being more suitable to proceed directly to an anterior pelvic extenteration. This was discussed with that patient, and she agreed to the operation.

She proceeded to anterior pelvic extenteration with radical cystectomy, hysterectomy, bilateral pelvic lymphadenopathy and ileal conduit formation. During her operation, she was confirmed to have T4 disease with spread to the pelvic wall. Unfortunately, her tumor was incompletely excised with tissue remaining adherent to the pelvic wall and right sided iliac vessels.

Pathology of the tumor confirmed urothelial carcinoma with moderate squamous cell differentiation and metastases to 3 out of 9 regional lymph nodes on the left side (Figure 3). Immunostaining for bHCG was positive (Figure 4), but we were unable to stain for CA19-9 for technical reasons. Her post-cystectomy tumor markers normalized with respect to our standard reference ranges a week later (CA19-9: 11 kU/L and BHCG: 2 U/L). No other preoperative cause was found to explain the increase in the tumor markers. The patient recovered well following her cystectomy, and was referred onwards for adjuvant chemotherapy with a course of methotrexate, vinblastine, doxorubicin and cisplatin.

Methodology

Quantitative analysis of serum bHCG was performed using the Immulite hCG assay on an Immulite 1000 instrument according to manufacturer's instructions (Siemens Healthcare GmbH, Germany).

Measurement of serum CA 19-9 was performed using a Unicel DxH 800 Coulter Cellular Analysis System according to manufacturer's instructions (Beckman Coulter, CA, USA).

Immunohistochemical staining was performed using a Roche Ventana XT Ultra automated stainer (Roche Ventana) according to manufacturer instructions. Briefly, relevant histology slides were deparaffinized and antigen retrieval performed for 16 minutes in CC1 solution. The sections were then incubated with anti bHCG antibody (1:8000, Dako cat no. A0231, 28 minutes at 37°C), followed by the detection step with DAB (Roche Ventana Optiview DAB kit, cat no 760-700). Counterstaining was performed with haematoxylin and bluing reagent (Roche Ventana, cat no. 760-2021, 760-2037).

Discussion

The CT scan was performed with a Siemen 64 slice CT scanner. Iohexol (Omnipaque 350) solution was used for contrast. Following a pre-contrast scan, 40ml of intravenous Omnipaque 350 solution was injected and a ten minutes delay phase captured. A further 50ml of Omnipaque 350 solution was injected and the scan repeated to capture an arterial phase.

We have presented a case of locally advanced bladder urothelial carcinoma where serum CA19-9 and bHCG were both elevated pre-operatively, remained elevated in response to TURBT (in the case of bHCG, elevated slightly), yet resolved to within normal reference ranges following radical surgical excision, albeit with residual tumor remaining. Similar findings have been previously reported in a case post cystectomy of a tumor expressing carcinoembryonic antigen (CEA) and CA19-9 [5]. Serum levels of CEA and CA 19-9 reduced post operatively. Both CA19-9 and bHCG have previously been shown to correlate with more aggressive disease and poorer outcomes in bladder cancer.

CA19-9 is a carbohydrate antigen related to the Lewis A blood group antigen with a role in E-selectin mediated metastasis in cancer and is best known for its association with pancreatic cancer [6]. Although immunohistologically positive in only up to 30% of bladder cancers [1], elevation of serum levels prior to cystectomy appear to confer a worse five year survival [2,7]. Although a fall in serum CA19-9 levels has been demonstrated in the context of chemotherapy [8], there has not been a documented improvement in survival for bladder cancer as has been similarly shown in pancreatic cancer [9]. Nevertheless, the location of the CA19-9 glycoprotein on the outermost layer of the cell membrane allows ease of antibody targeting, and Girgis and colleagues have demonstrated in a preclinical study the ability to target CA19-9 with radiolabelled anti CA19-9 antibodies to produce antigen-specific microPET images. This in turn promises to translate to therapeutic payloads targeted via engineered antibodies against CA19-9 and new systemic agents for bladder cancer [10].

In contrast, therapies towards bHCG already exist and the secretion of this gonadotropin itself has been associated with bladder cancer since 1904 with an abundance of literature to this effect [4]. Approximately 35% of bladder cancer cases involve ectopic bHCG production and elevated levels of urinary, serum, or immunohistochemical bHCG have all been correlated to higher tumor grade, stage, metastatic potential, worse prognosis, and poor response to radiotherapy possibly through inhibited apoptosis [11-14]. Furthermore, Douglas and colleagues reported a dramatic reduction in five year recurrence free survival from 75% to 26% for patients with elevated serum bHCG following cystectomy [2]. Efforts towards the development of effective contraception through bHCG vaccines has in turn lead to a potentially new therapy against bHCG secreting bladder cancer, particularly if specific immunogenicity can be improved [15]. Preclinical studies suggest that bHCG targeting antibodies can be used for targeted cancer therapy [16], and indeed a Phase II trial for a vaccine against bHCG-secreting bladder cancer is already underway [17].

Urachal carcinomas are usually locally advanced at presentation with a high risk of distant metastases. However, long-term survival following radical resection occurs in a significant fraction of patients (16 of 35 in our series), supporting an attempt at margin-negative, en bloc resection if at all possible.



Chemotherapy appropriate for enteric type adenocarcinoma can induce objective responses but meaningful improvement in survival is not yet demonstrated

References

1. Peter Jian, Guilherme Godoy, Gilad E. Amiel, Seth P. Lerner. 1604 Evaluation of preoperative serum Ca19-9 as predictor of adverse pathologic features and clinical outcome in patients with urothelial carcinoma of the bladder undergoing radical cystectomy and extended lymph node dissection. *The Journal of Urology*. 2011;185(4):643-644. DOI:dx.doi.org/10.1016/j.juro.2011.02.2709.
2. Douglas J, Drake T, Sommerlad M, Crabb S. Serum B-HCG predicts recurrence post radical cystectomy. *The Journal of Urology*. 2013;189:586.
3. Scott AM, Wolchok JD, Old LJ. Antibody therapy of cancer. *Nat Rev Cancer*. 2012;12(4):278-87. doi: 10.1038/nrc3236.
4. Malkhasyan K, Deshpande HA, Adeniran AJ, Colberg JW, Petrylak DP. The use of serum hCG as a marker of tumor progression and of the response of metastatic urothelial cancer to systemic chemotherapy. *Oncology (Williston Park)*. 2013;27(10):1028, 1030.
5. Iwaki H, Omatsu S, Konishi T, Moritani S. [Adenocarcinoma of the bladder producing carcinoembryonic antigen and carbohydrate antigen 19-9: report of a case]. *Hinyokika Kyo*. 1997;43(5):355-8.
6. Taga M, Hoshino H, Low S, Imamura Y, Ito H, Yokoyama O, et al. A potential role for 6-sulfo sialyl Lewis X in metastasis of bladder urothelial carcinoma. *Urol Oncol*. 2015;33(11):496.e1-9. doi: 10.1016/j.urolonc.2015.05.026.
7. Ahmadi H, Djaladat H, Cai J, Miranda G, Daneshmand S. Precystectomy serum levels of carbohydrate antigen 19-9, carbohydrate antigen 125, and carcinoembryonic antigen: prognostic value in invasive urothelial carcinoma of the bladder. *Urol Oncol*. 2014;32(5):648-56. doi: 10.1016/j.urolonc.2014.01.019.
8. Cook AM, Huddart RA, Jay G, Norman A, Dearnaley DP, Horwich A. The utility of tumour markers in assessing the response to chemotherapy in advanced bladder cancer. *Br J Cancer*. 2000;82(12):1952-7.
9. Ballehaninna UK, Chamberlain RS. The clinical utility of serum CA 19-9 in the diagnosis, prognosis and management of pancreatic adenocarcinoma: An evidence based appraisal. *J Gastrointest Oncol*. 2012;3(2):105-19. doi: 10.3978/j.issn.2078-6891.2011.021.
10. Girgis MD, Federman N, Rochefort MM, McCabe KE, Wu AM, Nagy JO, et al. An engineered anti-CA19-9 cys-diabody for positron emission tomography imaging of pancreatic cancer and targeting of polymerized liposomal nanoparticles. *J Surg Res*. 2013;185(1):45-55. doi: 10.1016/j.jss.2013.05.095.
11. Moutzouris G, Yannopoulos D, Barbatis C, Zaharof A, Theodorou C. Is beta-human chorionic gonadotrophin production by transitional cell carcinoma of the bladder a marker of aggressive disease and resistance to radiotherapy? *Br J Urol*. 1993;72(6):907-9.
12. Pattari SK, Dey P. Urine: beyond cytology for detection of malignancy. *Diagn Cytopathol*. 2002;27(3):139-42. doi:10.1002/dc.10135.
13. Venyo AK, Herring D, Greenwood H, Maloney DJ. The expression of beta human chorionic gonadotrophin (β -HCG) in human urothelial carcinoma. *Pan Afr Med J*. 2010;7:20.
14. Butler SA, Ikram MS, Mathieu S, Iles RK. The increase in bladder carcinoma cell population induced by the free beta subunit of human chorionic gonadotrophin is a result of an anti-apoptosis effect and not cell proliferation. *Br J Cancer*. 2000;82(9):1553-6. doi:10.1054/bjoc.2000.1177.
15. Delves PJ, Iles RK, Roitt IM, Lund T. Designing a new generation of anti-hCG vaccines for cancer therapy. *Mol Mol Cell Endocrinol*. 2007;260-262:276-81. doi:10.1016/j.mce.2006.02.018.
16. Gillott DJ, Iles RK, Chard T. The effects of beta-human chorionic gonadotrophin on the in vitro growth of bladder cancer cell lines. *Br J Cancer*. 1996;73(3):323-6.
17. Morse MA, Bradley DA, Keler T, Laliberte RJ, Green JA, Davis TA, et al. CDX-1307: a novel vaccine under study as treatment for muscle-invasive bladder cancer. *Expert Rev Vaccines*. 2011;10(6):733-42. doi: 10.1586/erv.11.20.

9.