

## Case Report

## Open Access

### Brown Semen: Think of Necrotizing Pancreatitis!

Mohammad S Walid

Heart of Georgia Women's Center, Warner Robins, GA, USA

**Corresponding Author :** Mohammad S Walid, Heart of Georgia Women's Center, Warner Robins, GA, USA, **E-mail:** [mvalid@gmail.com](mailto:mvalid@gmail.com)

**Received date:** June 13, 2018; **Accepted date :** August 13, 2018; **Published date:** August 17, 2018.

**Citation this Article:** Mohammad S Walid, Brown Semen: Think of Necrotizing Pancreatitis. J Obstetrics Gynecology and Reproductive Sciences, **Doi:** 10.31579/2578-8965/010

**Copyright :** © 2018 Mohammad S Walid . This is an open-access article distributed under the terms of the Creative Commons Attribution License, which permits unrestricted use, distribution, and reproduction in any medium, provided the original author and source are credited.

#### Introduction

Pancreatitis is a common medical problem frequently encountered by hospitalists among alcohol abuse patients. It usually presents with abdominal pain with nausea with or without diarrhea. In severe cases, pancreatitis may be complicated by necrotizing process.

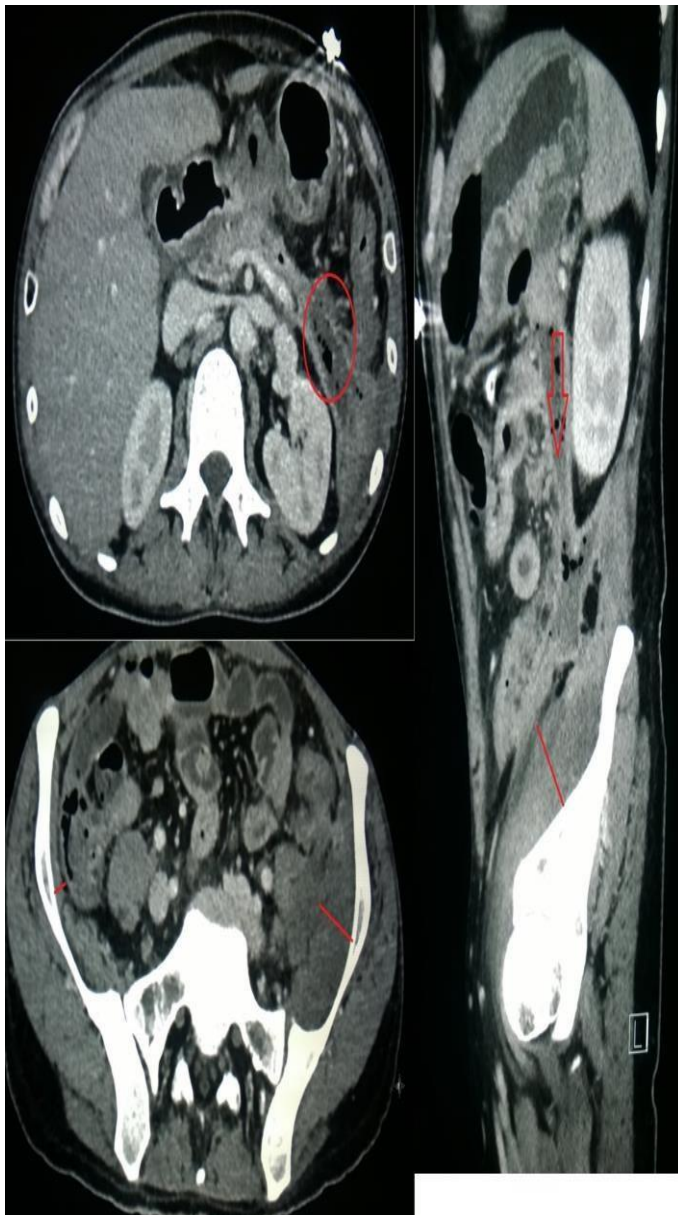
Cullen's sign of pancreatitis is superficial edema and bruising in the subcutaneous fatty tissue around the umbilicus. The sign takes 24–48 hours to appear and can predict increased mortality. In more severe cases, it may be accompanied by Grey Turner's sign (bruising of the flank) indicative of pancreatic necrosis with retroperitoneal or intraabdominal bleeding. Our case have an interesting presentation from which we can learn a new sign.

#### Case Report

This is a 31 yo man of thin body habitus who presented to ED with complaints of abdominal pain, back pain and left hip pain. The patient has been complaining of pain "for a long time." Denies fever, chest pain, or shortness of breath. He has h/o alcohol abuse and chronic

pancreatitis and recently spent 3 weeks at a bigger hospital in a nearby town then moved back to Fond du Lac. Patient also smokes. Walks with a cane. During interview he reported brown semen. Denies change in urine color or urinary discomfort. Last HIV test 2 years ago. Patient said he is heterosexual, lives with parents, unemployed, smokes >1 pack a day, drinks vodka, and denies illicit drugs. His home meds are mirtazapine, sertraline, lorazepam, oxycodone and potassium supplement. On arrival, vitals showed accelerated heart rate 143 bpm and normal other parameters: blood pressure 111/78, temperature 98.6 F, and respiratory rate 20 bpm. On physical exam, lungs clear to auscultation, no abdominal tenderness, and no scrotal swelling but there is limitation in ROM of left hip. CT abdomen and pelvis showed necrotizing pancreatitis with extension from the pancreatic tail inferiorly along the Gerota's fascia contacting the left psoas and iliacus muscles (see pictures). EKG is sinus tachycardia. Labs show increased white count and ketones as well as decreased hemoglobin, potassium, and albumin. Lipase mildly elevated. Bacteriological studies showed he was MRSA carrier and was positive for C. Diff. in stool.

	On Admission		On Admission	6 days ago		On Admission	6 days ago
Clarity UR	Clear	<input type="checkbox"/> WBC	H 12.5 10 <sup>3</sup> /L	H 17.5 10 <sup>3</sup> /L	<input type="checkbox"/> Sodium	137 mEq/L	135 mEq/L
Color UR	Yellow	<input type="checkbox"/> RBC	L 3.34 10 <sup>6</sup> /u	L 2.66 10 <sup>6</sup> /u	<input type="checkbox"/> Potassium	3.6 mEq/L	L 3.3 mEq/L
Glucose UR	Negative mg/d	<input type="checkbox"/> Hgb	L 9.9 g/dL	L 8.4 g/dL	<input type="checkbox"/> Chloride	L 99 mEq/L	L 98 mEq/L
Bilirubin UR	Negative mg/d	<input type="checkbox"/> Hct	L 30.9 %	L 25.2 %	<input type="checkbox"/> CO2	28 mEq/L	25 mEq/L
Ketone UR	A 15 mg/dL	<input type="checkbox"/> MCV	93 fL	95 fL	<input type="checkbox"/> AGAP	14	15
<input type="checkbox"/> Specific Gravity UR	1.012	<input type="checkbox"/> MCH	29.7 pg	31.5 pg	<input type="checkbox"/> Glucose Level	H 124 mg/dL	H 108 mg/dL
pH UR	6.5	<input type="checkbox"/> MCHC	32.1 g/dL	33.2 g/dL	<input type="checkbox"/> BUN	L 5 mg/dL	L 4 mg/dL
Protein UR	Negative mg/d	<input type="checkbox"/> RDW	15.5 %	14.6 %	<input type="checkbox"/> Creatinine	L 0.39 mg/dL	L 0.46 mg/dL
Urobilinogen UR	0.2 mg/dL	<input type="checkbox"/> PLT	H 823 10 <sup>3</sup> /uL	H 734 10 <sup>3</sup> /uL	<input type="checkbox"/> BUN/CREAT Ratio	* See Commer	* See Commer
Nitrite UR	Negative	<input type="checkbox"/> MPV	L 6.0 fL	L 6.3 fL	<input type="checkbox"/> Calcium	L 8.4 mg/dL	L 8.5 mg/dL
Blood UR	Negative	<input type="checkbox"/> Neutro	57.4 %	H 75.9 %	<input type="checkbox"/> Alkaline Phosphatase	H 236 units/L	H 157 units/L
Leukocyte Esterase UR	Negative	<input type="checkbox"/> Lymph	30.0 %	L 15.3 %	<input type="checkbox"/> ALT (SGPT)	29 units/L	18 units/L
<b>UA MICROSCOPIC</b>		<input type="checkbox"/> Mono	10.8 %	8.0 %	<input type="checkbox"/> AST (SGOT)	H 63 units/L	37 units/L
WBC UR	0-4 /hpf	<input type="checkbox"/> Eosin	0.9 %	0.6 %	<input type="checkbox"/> Bilirubin Total	0.5 mg/dL	0.4 mg/dL
RBC UR	0-2 /hpf	<input type="checkbox"/> Baso	0.9 %	0.2 %	<input type="checkbox"/> Protein Total	6.9 g/dL	6.3 g/dL
Bacteria UR	Not Noted /hpf	<input type="checkbox"/> Neutro#	7.2 10 <sup>3</sup> /uL	H 13.3 10 <sup>3</sup> /uL	<input type="checkbox"/> Albumin	L 2.2 g/dL	L 2.1 g/dL
Hyaline Casts UR	0-5 /hpf	<input type="checkbox"/> Lymph#	3.8 10 <sup>3</sup> /uL	2.7 10 <sup>3</sup> /uL	<input type="checkbox"/> Globulin	H 4.7 g/dL	H 4.2 g/dL
Squamous Cells UR	0-5 /hpf	<input type="checkbox"/> Mono#	H 1.4 10 <sup>3</sup> /uL	H 1.4 10 <sup>3</sup> /uL	<input type="checkbox"/> Alb/Glob Ratio	L 0.5	L 0.5
		<input type="checkbox"/> Eosin#	0.1 10 <sup>3</sup> /uL	0.1 10 <sup>3</sup> /uL	<input type="checkbox"/> Lipase Level	H 51 units/L	H 42 units/L
		<input type="checkbox"/> Baso#	0.1 10 <sup>3</sup> /uL	0.0 10 <sup>3</sup> /uL	<input type="checkbox"/> Lactate Plasma Venous	H 2.7 mmol/L	
					<input type="checkbox"/> Procalcitonin	* 0.31 ng/mL	

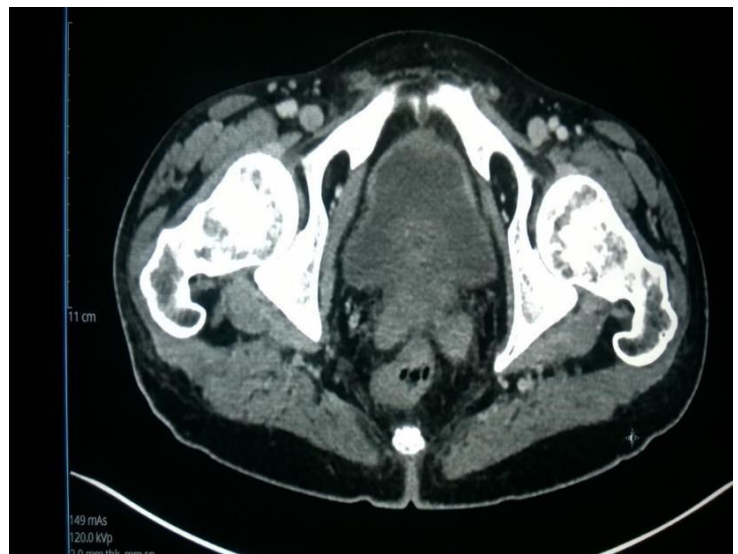


**Figure 1:** Compare the thickness of iliac muscles on both sides.

### CT abdomen & pelvis with IV contrast

#### Pancreas

There is moderate inflammatory changes surrounding the pancreas. There is ill-defined hypoattenuation within the pancreatic head and uncinate process may indicate areas of pancreatic necrosis. There are peripancreatic fluid collections some containing air which raises concern of superimposed infection. There is a very small focus of air and fluid just below the medial aspect the left hemidiaphragm near the medial and superior splenic pole which measures 14 x 7 mm which extends inferiorly is a thin fluid collection towards the pancreatic tail. This very small collection is separate from the largest collection. This largest collection extends from the pancreatic tail where the fluid and air loculation measures approximately 2.7 x 3.2 cm axially and 3.2 cm craniocaudally. This is contiguous with a fluid collection extending inferiorly immediately anterior to Gerota's fascia which measures 1.8 x 4.5 cm axially at its largest margin and extends approximately 13 cm craniocaudally. This fluid collection and associated surrounding inflammation extends onto the left psoas muscle and left iliacus muscles which are enlarged consistent with myositis. There is no definite intramuscular fluid collection at this time.



**Figure:2** The seminal vesicles looked normal.

This young man was admitted as inpatient to the MedSurg Floor for the following reasons:

- Possible acute on chronic necrotizing pancreatitis
- Possible sepsis
- Possible STD with gonococcal left hip arthritis
- MRSA carrier
- Hypokalemia
- Anemia of chronic disease
- Hypoalbuminemia
- Smoker
- Asthenia

The patient was treated with nothing by mouth, IV fluids, IV PPI, IV fluids and IV antibiotics. The surgeon evaluated the patient and thought the patient might have a smoldering process from the recent acute pancreatitis for which he was treated 3 weeks in hospital. HIV and tests for STDs came negative.

**Comment:** Disease is an aberration of physiological process. Each patient may have his/her own presentation of disease based on age, gender, race, genetics, and comorbidities. Our case presents a new sign, the sign of brown semen and left hip pain. I suggest to call it the Valid's sign. This sign would be helpful in paying attention to the possible diagnosis of necrotizing pancreatitis on a background of alcohol abuse. The sign points to a pancreatitis-induced fluid accumulation spreading inferiorly from the tail of the pancreas down to the pelvis floor. The brown semen is a manifestation of reactive inflammatory process by vicinity affecting the seminal vesicle, probably on the left side, the same side of left hip pain coinciding with the side of the tail of the pancreas from which the pancreatic juice accumulated and spread down. There is no mention in the literature of brown semen as a sign of smoldering necrotizing pancreatitis. I am calling on researchers to do an epidemiological study, prospective or retrospective, to measure the predictive value of this sign for the above diagnosis.

#### Abbreviations

ED: Emergency Department  
 H/O: History Of  
 HIV: Human immunodeficiency virus  
 ROM: Range of motion  
 CT: Computed tomography  
 EKG: Electrocardiography  
 MRSA: Methicillin-resistant staphylococcus aureus  
 C. Diff.: Clostridium Difficile  
 STDs: Sexually transmitted diseases  
 IV: Intravenous  
 PPI: Proton pump inhibitor