

Pituitary Adenoma in the Elderly

Atroune L^{1*}, Bennaleg S¹, Habchi N¹, Bouaita K² and Djafer M¹

¹Mustapha Bacha Hospital, Department of Neurosurgery, Algiers, Algeria

²Cherchell Hospital, Department of Neurosurgery, Tipaza, Algeria

*Corresponding Author: Atroune L, Mustapha Bacha Hospital, Department of Neurosurgery, Algiers, Algeria

Received date: February 26, 2021; Accepted date: March 03, 2021; Published date: March 10, 2021

Citation: Atroune L., Bennaleg S., Habchi N., Bouaita K., and Djafer M., (2021) Pituitary Adenoma in the Elderly. *J. Neuroscience and Neurological Surgery*. 8(5); DOI:10.31579/2578-8868/168

Copyright: © 2021 Atroune L, This is an open-access article distributed under the terms of The Creative Commons Attribution License, which permits unrestricted use, distribution, and reproduction in any medium, provided the original author and source are credited

Abstract:

Given advances and wide availability of neuroimaging coupled with longer life span, higher numbers of elderly patients with pituitary adenomas are being seen who are potential surgical or medical therapy candidates.

Our study concerns 07 cases of Pituitary adenoma in patients aged more than 70 years old, collected in Mustapha Pasha's neurosurgery department in Algiers for a period of 18 years (from 2000 to 2018). Pituitary adenoma is not considered a disease of advanced age; its incidence is rated around 3–4%. The average age of patients was 72 years old, slightly more common in females and represents 60% of the cases. The average duration of symptoms before diagnosis is 2 and half years. The clinical signs were dominated by visual deterioration, and in a lesser degree a hypopituitarism.

Neuro-imaging (CT scan/ MRI) are the key exams. MRI is important especially in the development of surgical planning. Collected radiological data reported the presence of macro adenoma with supra sellar extension in the majority of our cases;

The surgical approach was transnasal- Transsphenoidal in all patients. The evolution was satisfactory for the majority of patients. However, complications were noted. We deplore the death of a patient presented with meningitis. Patients over age 70 with pituitary tumors and indications for surgery should be considered surgical candidates for transsphenoidal surgery given the low risks of this procedure.

Key words: transnasal- trans; sphenoidal; elderly; hypopituitarism

Introduction

Pituitary adenomas (PAs) are common benign intra-cranial neoplasms, with an estimated prevalence of 16.7% in the general population. [3,4]. Non functioning PAs (NFPAs) are a type of PA without clinical evidence of excess hormone secretion, and, due to their silent nature, patients present with symptoms related to mass effect, such as visual disturbances. [5].

Life expectancy has increased over the past century; causing a shift in the demographic distribution in developed countries toward older age groups. [6]. Also, skull base surgery in geriatric patients has been becoming increasingly common, particularly with the emergent use of the endoscopic trans-sphenoidal (TNS) approach [7].

Elderly patients account for up to 14% of all patients diagnosed with pituitary tumors, with most lesions being NFPAs. [8,9].

While several studies have shown the relative safety of transsphenoidal surgery for elderly patients with symptomatic pituitary adenomas, the

complication rates reported in the literature with progressive age remain significant and cautionary [10,11,12].

According to the latest guidelines, TNS is recommended in elderly patients with NFPAs associated with visual disturbances [13,14], whereas the indication for surgery in individuals without evidence of visual impairment is still a matter of debate, given the slow growth of PAs and the increase in age-related anesthetic and surgical risk [13,15,16,17].

The treatment of choice mainly depends on the local extension of the tumor, clinical presentation, tumor size and configuration, and overall patient health [18, 19, 9, 20, 21]. But no consensus guidelines are available in elderly patients who often present with a greater number of medical comorbidities and less physiological reserve, predisposing them to an increased rate of surgical complications. In order to critically review our experience with the treatment of pituitary adenomas in the elderly, we have retrospectively analyzed the surgical treatment, outcome of 07 patients with pituitary tumors, who were more than 70 years of age at the time of surgery.

Patients and methods

The study included 07 patients older than 70 years, who were diagnosed and treated or pituitary adenomas between the year 2000 and 2018.

In all patients complete hormonal screening was obtained and the visual acuity and visual fields were examined pre- and postoperatively. Immunocytochemical studies with polyclonal anti-GH, anti-PRL, anti-FSH, anti-LH, anti-TSH and anti-ACTH antibodies were performed. The anesthesiological risks were staged according to the American Society of Anesthesiologists (ASA) scale. Surgical indications were the presence of neurological signs or symptoms related to the tumor mass at presentation, a rapid growth of the lesion and a hormonally active pituitary adenoma. Tumor size and extension were evaluated with the Hardy classification. Neurological and endocrinological examinations were performed before and after the operation and at 6 months-intervals after surgery. Findings from patients, clinical records, radiological examinations and operative reports were recorded.

The surgical procedures were performed by a dedicated team in our Neurosurgery department. All patients underwent a transseptal transsphenoidal microscopic approach according to the modified Hardy technique. Postoperatively the patients were transferred the ICU, with special attention to heart and circulation homeostasis and fluid-electrolyte balance and Monitoring of hourly diuresis.

Follow-up included a yearly clinical examination and basal hormonal assessment of pituitary function. Neuroradiological imaging and endocrinological follow-up was performed 3 months after surgery.

Results

The study included 07 patients older than 70 years, affected by pituitary adenomas (4 non-functioning pituitary adenomas, 2 GH secreting adenomas, 1 ACTH-secreting adenoma). The average age of the patients was 72 years. 3 patients were men and 4 were women; Clinical presentation reflected tumour-related mass effect in 6 patients, with headaches present in 5 patients and visual field deficits in 6 patients. 01 patient presented sudden headache and worsening vision.

Tumor size and extension were evaluated with the Hardy classification: One case was considered an intrasellar adenoma, 05 cases an enclosed adenoma with little suprasellar extension. The rest of the cases appeared as adenomas with marked suprasellar extension.

Patients included in the study presented with a high incidence of comorbidities, cardiovascular diseases being the most frequent. Before surgery all the patients were classified following the American Society of Anaesthesiologists physical status classification system. An ASA score of 1 was assigned to 1 patient. The ASA score was 2 in 4 patients, ASA 3 in 1, and ASA 4 in 1 case.

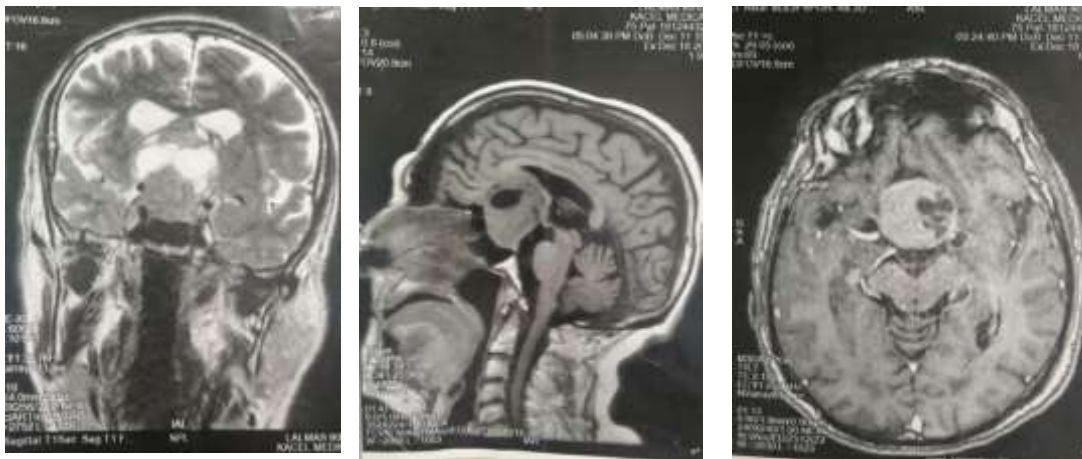


Figure 1: an MRI of 75 year old patient showing an adenoma with marked suprasellar extension

All patients underwent a transseptal-transsphenoidal microscopic approach; appropriate intraoperative and postoperative glucocorticoid supplementation was administered to all patients. Two patients complained of postoperative permanent diabetes insipidus, no postoperative CSF-leak. One patient died after surgery.

As far as the anterior pituitary function is concerned, no patient recovered a pre-existent pituitary deficit. An additional hormonal deficit was observed in 1 patient. Finally, a significant visual field improvement was demonstrated in 05 of our patients with preoperative visual deficits, while headache resolved in all patients with this disturbance.

Discussion

The most common endocrine changes of healthy aging are declines in GH and IGF-I, ovarian steroids in postmenopausal women, testosterone (T) in men and DHEA. Aging is associated with an increased frequency of

pituitary tumors, detected incidentally in 10%–25% of hypothalamic-pituitary MRIs performed in older persons. [22]

In this study, we present our experience with transsphenoidal surgery (TSS) between 2000 and 2018 in 07 patients with pituitary adenomas, aged more than 70 years at the time of surgery. From this 07 elderly patients, NFPAs represented 57, 18% of the whole serie, with GH-secreting adenomas accounting for 2 and 28, 57% and 01 adrenocorticotrophin (ACTH)- secreting adenomas, respectively. Similar figures have been reported by others, with NFPAs representing 55–84% of all cases, followed by GH- (9–27%), PRL- (4.5–10%) and adrenocorticotrophin (ACTH)- (0–6%) secreting adenomas, respectively [22, 23, 24, 25, 26]. Noteworthy is that some studies suggest that the incidence of gonadotroph adenomas, usually included in the NFGA group, tends to increase with age and to be more frequently diagnosed above 60 years, especially in men [27, 28].

There was a clear male predominance, which also was thereby probably implying that there is a later onset of symptoms in men harboring clinical non functioning macroadenomas observed in previous studies.

Given the increase in life expectancy and the expansion in use of MRI and CT imaging, it is presumed that the prevalence of diagnosed PAs in the elderly population will grow [7]. Previous studies have confirmed this trend, with a steady increase in the proportion of PA cases being in elderly patients over the past 3 decades [18, 9, 29 and 30].

The growth of PAs is generally slow in elderly and about 25% of asymptomatic macro adenomas may increase in size over 5 years of follow-up [31,32]. This can be supported by the low rates of cell proliferation commonly reported in this age group [33]. An age-related decrease in cell proliferation has been observed in NFPAs(34) and in GH-secreting tumours [14], the latter being mostly intrasellar in the elderly [23, 24, 35].

Moreover, the diagnosis of NFPAs in the elderly is frequently late, due to the low specificity of clinical symptoms and signs of pituitary diseases in this clinical setting (13,36,37,38). The most common symptom was the visual impairment, especially loss of acuity and bitemporal hemianopsia

due to suprasellar extension of adenomas. Dynamic endocrinological testings were not routinely performed, so that the incidence of subclinical pituitary insufficiency could be higher, as reported in other studies [21].

The clinical presentation of a pituitary adenoma in the elderly can be very atypical. Physiological endocrine changes due to age, frequent comorbidities, visual field impairment by senile degeneration can confuse or delay the diagnosis, which has been supported by series published in the literature [23]. Other explanations are also mentioned, including less tumor aggressiveness at this age in connection with lower GH and IGF1 levels than in young adults [24], in fact elderly subjects are more likely to have micro adenomas than young patients with this hypothesis. In addition, age-related variations in endocrine and paracrine factors, such as sex hormones, metabolic factors or tumor vascularity may be responsible for this difference [39]. It has also been reported in the literature that pituitary insufficiency is more likely in young patients [39]. A relationship between the size of the tumor and the degree of pituitary insufficiency has been suggested [25].

Presenting Symptom	No. of Patients (%)		p Value	Our study No. of Patients Age >70 Yrs
	Age ≤65 Yrs	Age >65 Yrs		
Visual deficit	213 (54.6)	101 (50.8)	0.384	6
Headache	174 (44.6)	67 (33.7)	0.013	6
Amenorrhea/irregular menses	42 (10.8)	0 (0.0)	<0.001	0
Galactorrhea	18 (4.6)	0 (0.0)	0.001	0
Libido decrease/sexual dysfunction	42 (10.8)	11 (5.5)	0.047	0
Fatigue/decreased energy	113 (29.0)	53 (26.6)	0.563	0
Weight change	50 (12.8)	18 (9.0)	0.220	1
Dizziness	50 (12.8)	29 (14.6)	0.609	1
Asymptomatic	20 (5.1)	26 (13.1)	0.001	1
Preop hypopituitarism	172 (43.5)	74 (36.1)	0.081	3

Table 1: Presenting symptoms in patients with NFPA, stratified by age [21].

Despite an increased anesthesiological risk present in most of the patients, we only lost one patient and one severe anesthesiological complication was observed (diabetes insipidus), and one with cerebrospinal fluid leak [40].

The post-operative hospitalization period for the whole series was about 15 days, similar to those reported by previous studies with an average LOS ranging from 3–18 days [41, 42].

Previous studies reporting visual symptom improvement of 71%–100% after surgery in these patient demographics, the same was observed in all of the patients, supporting evidence that curative TSS is the treatment of choice for NFPAs causing visual failure [9, 43, 44 and 45].

TSS carries known risks of pituitary stalk perturbation leading to syndrome of inappropriate antidiuretic hormone secretion (SIADH) or DI causing hyponatremia or hypernatremia, respectively (48,49). Studies evaluating clinical outcomes in elderly patients undergoing TSS have found a similar incidence of DI in this age group, with permanent DI rates as high as 5% [9, 10, 50, 51, 52, 20 and 29].

In this group, anterior pituitary function worsened in 1 of patient and two presented with hyponatremia while pre-operative hypopituitarism remained unchanged in most. no significant improvement of impaired pituitary function was observed similar to some studies have suggested that elderly adenoma patients are less likely to show gland function improvement and have higher rates of new hypopituitarism, however data is limited [53]

Recent studies addressing pituitary adenoma surgery in the elderly are summarized in Table 2. [46, 47]

In literature, it was relatively clear that postoperative DI after TSS reflects some degree of stalk injury, the mechanisms of hyponatremia after TSS are less clear but may reflect abnormal release of ADH or brain natriuretic peptide causing SIADH or cerebral salt wasting [54,55]. Hyponatremia is favoured by adrenal failure and age-related changes in vasopressin secretion. It is possible that age-related structural changes in the pituitary gland, such as increased interstitial and perivascular fibrosis, may confer the age-related protection against postoperative DI that was identified in previous studies [56, 21]. In contrast, age-related predispositions to electrolyte perturbations due to medications that elderly patients commonly take or age-related changes in the release threshold of natriuretic factors may contribute to the age related increase in hyponatremia we and previous studies has identified [47,21].

Literature review of large surgical series of elderly pituitary adenoma patients published from 2015 to 2020 highlighting resection/remission rates and complications

Author	Modality	Age cutoff	No of patients	GTR	LOS (mean)	Anterior gland decline	Persistent DI rate	Gland improvement
Resection rates, LOS and gland function								
Gondim et al. (2015)	Endoscope	> 70	55	68.7	8	12.7	3.6	0
Zhan et al. (2015)	Endoscope	> 65	158	75.9	NS	9.5	4.4	NS
Liu et al. (2015)	Microscope	> 65	69	66.7	6.98	4.3	11.6*	0
Zhao et al. (2017)	Microscope	> 65	130	66.9	NS	9.2	NS	NS
Wilson et al. (2018)	Endoscope	> 60	135	70.4	3.5	11.1	4.4	NS
Memel et al. (2019)	Mixed	> 70	115	73.9	3.78	NS	0	16.9
Azab et al. (2019)	Mixed	> 60	205	64.9	NS	NS	NS	NS
Spina et al. (2019)	**	> 65	336	58.9	10.5	12.4 hypo-gonad;2.7 hypothyroid 7.5 hypoadrenal	2.7	NS
Tardivo et al. (2019)	Endoscope	> 65	81	39.5	3.9	19.7	3.7	4.7
Jai Deep Thakur et al 2020	Endoscope	≥ 65	123	66	2(median), 2.6 (mean)	2.7	0	48.3

The retrospective nature of our study brings the usual limitations of a retrospective analysis like the missing cohort of our patients followed without surgery due to lack of an electronic medical record. In particular, some inconsistencies in the frequency of outpatient sodium checks could affect our findings about hyponatremia. Also long term tumor control of endocrine-inactive adenomas and biochemical remission in endocrine-active adenomas for some patients was not analyzed. Thus, it is likely that with longer follow-up some patients will require additional treatments such as radiosurgery, hormonal therapies and possibly repeat surgery.

TSS alone was performed in all our patients with total or subtotal resection of the adenoma. There was no regular follow-up approaching, so we weren't able to conclude the overall rate of recurrence. The rate of regrowth in NFPA is known to be mainly influenced by the quality of surgical resection [21]. Previous studies showed that pseudocapsular resection was not associated with the deterioration of the pituitary functions in elderly patients with NFPA; moreover, pseudocapsular resection might reduce the risk of postoperative hemorrhage [58]. According to recent series [21, 46], and to our data, even if obtained in a small number of patients, surgery could be safely performed in elderly.

Conclusion

In conclusion, our study indicates that TSS can be safely performed for patients older than 70 years. In the majority of cases it is able to improve the visual defects, and may represent the only therapy for patients with NFPA. The timing of surgical treatment seems to be an important determinant of postsurgical outcomes, especially when performed by a multidisciplinary team with a specific experience in pituitary diseases; we only need to keep in mind that the primary goal is the minimum mortality or relevant adjunctive morbidity.

References

1- Ostrom QT, Gittleman H, Liao P et al (2017) CBTRUS statistical report: primary brain and other central nervous system tumors diagnosed in the United States in 2010–2014. *Neuro Oncol* 19:v1–v88.

2- Melmed S (2020) Pituitary-tumor endocrinopathies. *N Engl J Med* 382:937–950.

3- 3-Eltabl MA, Eladawy Y, Hanafy A, et al. Surgical outcome of endoscopic versus microscopic trans-sphenoidal approach for pituitary adenomas. *Menoufia Med J.* 2015; 28(1): 87

4- 4-Ezzat S, Asa SL, Couldwell WT, et al. The prevalence of pituitary adenomas: a systematic review. *Cancer.* 2004;101(3): 613 – 619.

5- 5-Marazuela M, Astigarraga B, Vicente A, et al. Recovery of visual and endocrine function following transsphenoidal surgery of large nonfunctioning pituitary adenomas. *J Endocrinol Invest.* 1994; 17(9): 703 – 770

6- 6-Anderson GF, Hussey PS. Population aging: a comparison among industrialized countries. *Health Aff (Millwood).* 2000; 19(3): 191–203

7- 7-Ferrante L, Trillò G, Ramundo E, et al. Surgical treatment of pituitary tumors in the elderly: clinical outcome and long-term follow-up. *J Neurooncol.* 2002; 60(2): 185 – 191

8- 8-Turner HE, Adams CB, Wass JA. Pituitary tumours in the elderly: a 20 year experience. *Eur J Endocrinol.* 1999;140(5): 383–389.

9- 9-Gondim JA, Almeida JP, de Albuquerque LAF, et al. Endoscopic endonasal transsphenoidal surgery in elderly patients with pituitary adenomas. *J Neurosurg.* 2015;123(1): 31–38.

10- 10- Memel Z, Chesney K, Pangal DJ et al (2019) Outcomes following transsphenoidal pituitary surgery in the elderly: a retrospective single-center review. *Oper Neurosurg (Hagerstown)* 16:302–309.

11- 11- Wilson PJ, Omay SB, Kacker A et al (2017) Endonasal endoscopic pituitary surgery in the elderly. *J Neurosurg* 128:429–436.

12- 12- Karsy M, Bowers CA, Scoville J et al (2019) Evaluation of complications and costs during overlapping transsphenoidal surgery in the treatment of pituitary adenoma. *Neurosurgery* 84:1104–1111.

- 13- 13- G. Minniti, V. Esposito, M. Piccirilli, A. Fratticci, A. Santoro, M.-L. Jaffrain-Rea, Diagnosis and management of pituitary tumours in the elderly: a review based on personal experience and evidence of literature. *Eur. J. Endocrinol.*153, 723–735 (2005).
- 14- 14- T. Watanabe, H. Uehara, G. Takeishi, H. Chuman, M. Azuma, K.Yokogami et al. Characteristics of preoperative visual disturbance and visual outcome after endoscopic endonasal transsphenoidal surgery for nonfunctioning pituitary adenoma in elderly patients. *World Neurosurg.*126, e706–e712 (2019).
- 15- 15- P.U. Freda, J.N. Bruce, Risks of pituitary surgery in the elderly. *Nat. Rev. Endocrinol.*6, 606–608 (2010).
- 16- 16- B. Fraioli, F.S. Pastore, S. Signoretti, G.M.F. De Caro, R. Giuffrè, The surgical treatment of pituitary adenomas in the eighth decade. *Surg. Neurol.*51, 261–267 (1999)
- 17- 17- C. Tuleasca, Y. Ducos, H.-A. Leroy, P. Chanson, S. Knafo, M.Levivier et al. Transsphenoidal resection for pituitary adenoma in elderly versus younger patients: a systematic review and meta-analysis. *Acta Neurochir. (Wien.)*162, 1297–1308 (2020)
- 18- 18-Hong J, Ding X, Lu Y. Clinical analysis of 103 elderly patients with pituitary adenomas: transsphenoidal surgery and follow-up. *J Clin Neurosci.* 2008;15(10):1091–1095.
- 19- 19-Freda PU, Bruce JN. Surgery: risks of pituitary surgery in the elderly. *Nat Rev Endocrinol.* 2 0 1 0 ; 6 (1 1) : 6 0 6 –
- 20- 20-Marenco HA, Zymberg ST, Santos RP, Ramalho CO. Surgical treatment of non-functioning pituitary macroadenomas by the endoscopic endonasal approach in the elderly. *Arq Neuro-psiquiatr.* 2015;73(9):764–769
- 21- 21-Matheus P. Pereira, BS,1 Taemin Oh, MD,2 Rushikesh S. Joshi, BS,2 Clinical characteristics and outcomes in elderly patients undergoing transsphenoidal surgery for nonfunctioning pituitary adenoma *Neurosurg Focus* 49 (4):E19, 2020
- 22- 22-Cohen DL, Bevan JS & Adams CBT. The presentation and management of pituitary tumours in the elderly. *Age Ageing* 1989 18 247–252.
- 23- 23-Fraioli B, Pastore FS, Signoretti S, De Caro GMF & Giuffrè R. The surgical treatment of pituitary adenomas in the eighth decade. *Surgical Neurology* 1999 51 261–267.
- 24- 24-Turner HE, Adams CBT & Wass JAH. Pituitary tumours in the elderly: a 20-year experience. *European Journal of Endocrinology* 1999 140 383–389.
- 25- 25-Benbow SJ, Foy P, Jones B, Shaw D & McFarlane IA. Pituitary tumours presenting in the elderly: management and outcome. *Clinical Endocrinology (Oxford)* 1997 46 657–660.
- 26- 26-Pospiech J, Stolke D & Pospiech FR. Surgical treatment of pituitary adenomas in the elderly. *Acta Neurochirurgica Supplement (Wien)* 1996 65 35–36.
- 27- 27-Young WF Jr, Scheithauer BW, Kovacs KT, Horvath E, Davis DH & Randall RV. Gonadotroph adenoma of the pituitary gland: a clinicopathologic analysis of 100 cases. *Mayo Clinic Proceedings* 1996 71 649–656.
- 28- 28-Ho MD, Hsu CY, Ting LT & Chiang H. The clinicopathological characteristics of gonadotroph cell adenoma: a study of 118 cases. *Human Pathology* 1997 28 905–911.
- 29- 29- Sheehan JM, Douds GL, Hill K, Farace E. Transsphenoidal surgery for pituitary adenoma in elderly patients. *Acta Neurochir (Wien).* 2008;150(6):571–574
- 30- 30-Flowers A. Brain tumors in the older person. *Cancer Contr.* 2 0 0 0 ; 7 (6) : 5 2 3 – 525
- 31- 31- H. Turner, C. Adams, J. Wass. Pituitary tumours in the elderly: a 20 year experience. *Eur. J. Endocrinol.* 383–389 (1999).
- 32- 32- S. Feldkamp, A. Harms, S. Mödder, Incidentally discovered pituitary lesions: high frequency of macroadenomas and hormone-secreting adenomas—results of a prospective study: incidental pituitary lesions. *Clin. Endocrinol. (Oxf.)*51, 109–113 (1999)
- 33- 33-Jaffrain-Rea ML, Di Stefano D, Minniti G, Esposito V, Bultrini A, Ferretti E, Santoro A, Faticanti Scucchi L, Gulino A & Cantore G. A critical reappraisal of MIB-1 labelling index significance in a large series of pituitary tumours: secreting versus non-secreting adenomas. *Endocrine-Related Cancer* 2002 9 103–113.
- 34- 34-Losa M, Franzin A, Mangili F, Terreni MR, Barzaghi R, Veglia F, Mortini P & Giovanelli M. Proliferation index in non-functioning pituitary adenomas: clinical characteristics and long-term follow-up. *Neurosurgery* 2000 47 1313–1318.
- 35- 35-Minniti G, Jaffrain-Rea ML, Esposito V, Santoro A, Moroni C, Lenzi J, Tamburrano G, Cassone R & Cantore G. Surgical treatment and clinical outcome of GH-secreting adenomas in elderly patients. *Acta Neurochirurgica (Wien)* 2001 143 1205–1211.
- 36- 36- A.S. Tresoldi, G. Carosi, N. Betella, G. Del Sindaco, R. Indirli, E.Ferrante et al. Clinically nonfunctioning pituitary incidentalomas: characteristics and natural history. *Neuroendocrinology*110,595–603 (2020).
- 37- 37- P.U. Freda, A.M. Beckers, L. Katznelson, M.E. Molitch, V.M.Montori, K.D. Post et al. Pituitary incidentaloma: an endocrine society clinical practice guideline. *J. Clin. Endocrinol. Metab.*96,894–904 (2011).
- 38- 38- M. Losa, C.A. Donofrio, R. Barzaghi, P. Mortini, Presentation and surgical results of incidentally discovered nonfunctioning pituitary adenomas: evidence for a better outcome independently of other patients' characteristics. *Eur. J. Endocrinol.*169, 735–742 (2013)
- 39- 39-Kurosaki M, Ludecke DK, Flitsch J & Saeger W. Surgical treatment of clinically non-secreting pituitary adenomas in elderly patients. *Neurosurgery* 2000 47 843–849.
- 40- 40- Yunoue S., Tokimura H., Tominaga A., Fujio S., Karki P., Usui S., Kinoshita Y., Habu M., Moinuddin FM., Hirofumi Hirano & Kazunori Arita (2014) Transsphenoidal surgical treatment of pituitary adenomas in patients aged 80 years or older *Neurosurgical Review* volume 37, pages 269–277 (2014)
- 41- 41- Wilson PJ, Omay SB, Kacker A, et al. Endonasal endoscopic pituitary surgery in the elderly. *J Neurosurg.* 2018;128(2): 429–436.
- 42- 42- Grossman R, Mukherjee D, Chaichana KL, et al. Complications and death among elderly patients undergoing pituitary tumour surgery. *Clin Endocrinol (Oxf).* 2 0 1 0 ; 7 3 (3) : 3 6 1 – 3 6 8 .
- 43- 43- Kurosaki M, Lüdecke DK, Flitsch J, Saeger W. Surgical treatment of clinically nonsecreting pituitary adenomas in elderly patients. *Neurosurgery.* 2 0 0 0 ; 4 7 (4) : 8 4 3 – 8 8 8
- 44- 44- Fujimoto K, Yano S, Shinojima N, et al. Endoscopic endonasal transsphenoidal surgery for patients aged over 80 years with pituitary adenomas: surgical and follow-up results. *Surg Neurol Int.* 2 0 1 7 ; 8 (1) : 2 1
- 45- 45- Yunoue S, Tokimura H, Tominaga A, et al. Transsphenoidal surgical treatment of pituitary adenomas in patients aged 80 years or older. *Neurosurg Rev.* 2 0 1 4 ; 3 7 (2) : 2 6 9 – 2 7 7 .
- 46- 46- Jai Deep Thakur1,2,3 · Alex Corlin1 · Regin Jay Mallari1, Pituitary adenomas in older adults (≥ 65 years): 90-day

- outcomes and readmissions: a 10-year endoscopic endonasal surgical experience Pituitary
- 47- 47 -Jai Deep Thakur^{1,2,3} · Alex Corlin¹ · Regin Jay Mallari¹ et al. Pituitary adenomas in older adults (≥ 65 years): 90-day outcomes and readmissions: a 10-year endoscopic endonasal surgical experience
- 48- 48- Nemergut EC, Zuo Z, Jane JA Jr, Laws ER Jr. Predictors of diabetes insipidus after transsphenoidal surgery: a review of 881 patients. *J Neurosurg.* 2005; 103(3): 448–454
- 49- 49- Little AS, Gardner PA, Fernandez-Miranda JC, et al. Pituitary gland recovery following fully endoscopic transsphenoidal surgery for nonfunctioning pituitary adenoma: results of a prospective multicenter study. *J Neurosurg.* Published online November 15, 2019. doi:10.3171/2019.8.JNS191012
- 50- 50- Zhan R, Ma Z, Wang D, Li X. Pure endoscopic endonasal transsphenoidal approach for nonfunctioning pituitary adenomas in the elderly: surgical outcomes and complications in 158 patients. *World Neurosurg.* 2015;84(6):1572–1578.
- 51- 51- Pereira EAC, Plaha P, Chari A, et al. Transsphenoidal pituitary surgery in the elderly is safe and effective. *Br J Neurosurg.* 2014;28(5):616–621
- 52- 52- Paluzzi A, Fernandez-Miranda JC, Tonya Stefko S et al (2014) Endoscopic endonasal approach for pituitary adenomas: a series of 555 patients. *Pituitary* 17:307–319.
- 53- 53- Blair ET, Clemmer JS, Harkey HL, et al. Physiologic mechanisms of water and electrolyte disturbances after transsphenoidal pituitary surgery. *World Neurosurg.* 2017;107: 429–436
- 54- 54- Barber SM, Liebelt BD, Baskin DS. Incidence, etiology and outcomes of hyponatremia after transsphenoidal surgery: experience with 344 consecutive patients at a single tertiary center. *J Clin Med.* 2014; 3(4): 1199 – 1112
- 55- 55- Sano T, Kovacs KT, Scheithauer BW, Young WF Jr. Aging and the human pituitary gland. *Mayo Clin Proc.* 1993;68(10): 971–977.
- 56- 56- Filippatos TD, Makri A, Elisaf MS, Liamis G. Hyponatremia in the elderly: challenges and solutions. *Clin Interv Aging.* 2017; 12: 1957–1965.
- 57- 57- E. Biamonte^{1,2} N. Betella¹ D. Milani³ G. B. Impact of age on postsurgical outcomes of nonfunctioning pituitaryadenomas;
- 58- 58- Yasuyuki Kinoshita, Akira Taguchi, Atsushi Tominaga et al. Pseudocapsular resection in elderly patients with non-functioning pituitary adenoma



This work is licensed under Creative Commons Attribution 4.0 License

To Submit Your Article Click Here: [Submit Manuscript](#)

DOI:10.31579/2578-8868/168

Ready to submit your research? Choose Auctores and benefit from:

- ❖ fast, convenient online submission
- ❖ rigorous peer review by experienced research in your field
- ❖ rapid publication on acceptance
- ❖ authors retain copyrights
- ❖ unique DOI for all articles
- ❖ immediate, unrestricted online access

At Auctores, research is always in progress.

Learn more www.auctoresonline.org/journals/neuroscience-and-neurological-surgery