

## A Wolff- Parkinson- White Surprise Case

**William-Fernando Bautista-Vargas**

Electrophysiologist Head of Electrophysiology Department at St. Sophia State Hospital Manizales, Caldas Colombia South America

**Corresponding Author:** William-Fernando Bautista-Vargas, Electrophysiologist Head of Electrophysiology Department at St. Sophia State Hospital Manizales, Caldas Colombia South America **Email:** [Williambautista679@icloud.com](mailto:Williambautista679@icloud.com)

**Received date:** November 22, 2019; **Accepted date:** December 18, 2019; **Published date:** January 10, 2020.

**Citation:** William-Fernando Bautista-Vargas., (2020) A Wolff- Parkinson- White Surprise Case. Cardiology Research and Reports, 2(1): **Doi:** 10.31579/ 2692-9759/002

**Copyright:** © 2020 William-Fernando Bautista-Vargas. This is an open-access article distributed under the terms of The Creative Commons Attribution License, which permits unrestricted use, distribution, and reproduction in any medium, provided the original author and source are credited.

### Abstract

37-year-old-gentleman, who was presented in three occasional times to emergency department for a fast, precordial, and rhythmic symptomatic palpitations, in which the last episode was with a duration that lasted more than an hour with instability vitally that ended in performing emergency electrical cardioversion. All these episodes were symptomatic and last hospitalization was associated with pre syncopal and syncopal attacks.

With evidence of Wolff-Parkinson-White syndrome the patient was brought to Electrophysiology Lab to EP study and ablation.

**Key Words:** Syncope; Wolff-Parkinson-White Syndrome; catheter ablation.

### Abbreviations:

**CS:** coronary sinus

**RV:** Right ventricle

**ICE:** intra cardiac echo

**EP:** electrophysiology

**HV:** His-Ventricle

**AH:** Atrium- His

**AP:** Accessory pathway

**AF:** Atrial Fibrillation

**RR:** R wave to R wave interval

**ICU:** Intensive Coronary Unit

**ECG:** electrocardiogram

### Introduction

So often we found an ECG with Wolff- Parkinson- White pattern and some of them have an atypical delta wave morphology, and then there are

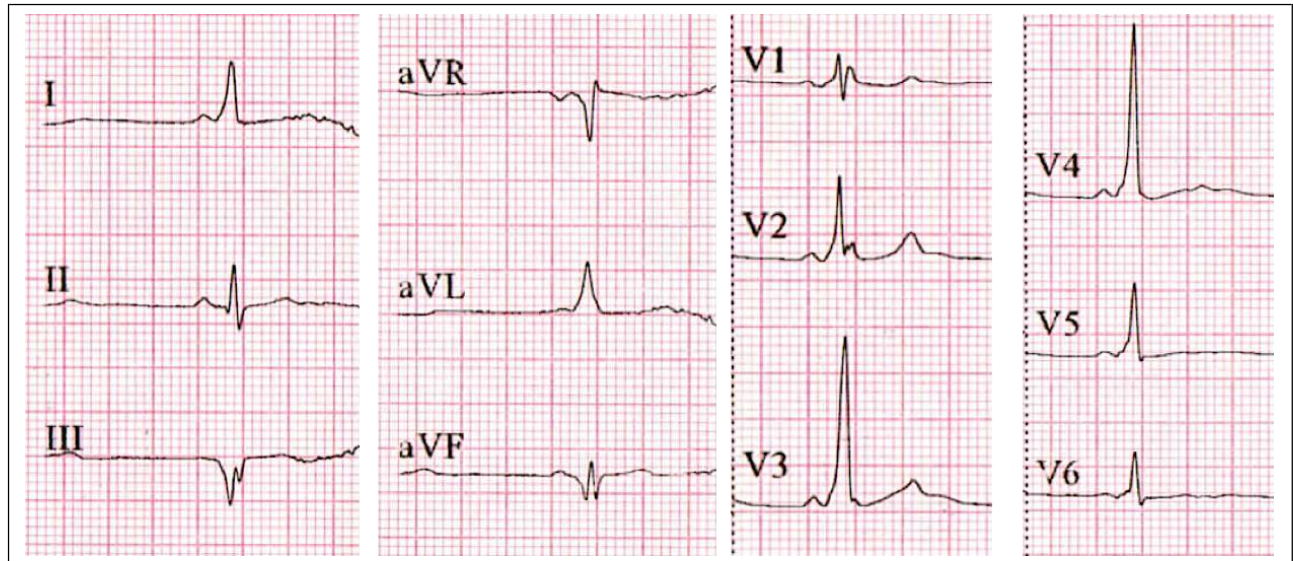
not easy to figure out the anatomical ubication of the accessory pathway, therefore even with the ECG patterns that are easily to predict where will become the accessory pathway, the real problem is: which ones of them are related with sudden cardiac death risk?. We have some probed clues of low risk: first of all the absence of atrial fibrillation on the ECG records, second the loss of preexisted conduction during the stress test, and the last but not less important the refractory period of AP during EP study specially when it is more than 300ms are signals of low cardiac risk. However the evidence is not clear when we have anatomical abnormalities related with WPW like CS aneurysm. [1]

### Materials and Methods

#### History of presentation

A 37- year-old gentleman, who is not known to have any medical illness, was presented with history of five years of precordial, fast, rapid, palpitations; some of these episodes needed to be admitted to emergency department. Last hospitalization patient had fast symptomatic palpitation with pre syncopal attack, with instability vitally that had to have an immediate successful electrical cardioversion, and admitted to ICU.

His ECG showed short PR interval with delta wave, this was positive at DI, negative at DIII, aVF and iso-biphasic DII (figure1).



**Figure 1:** ECG. Preexcitation pattern, delta wave positive at DI, V1-V6, negative DIII,aVF, aVR, iso-biphasic DII

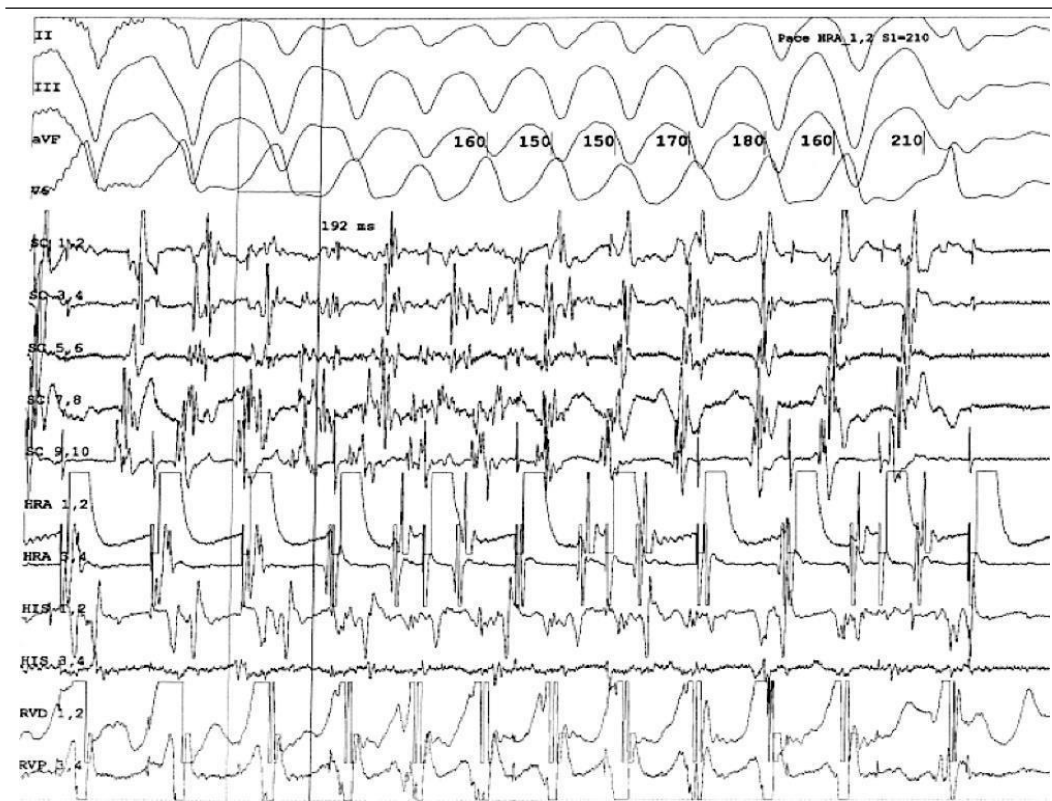
He had a normal echocardiogram with no regional motion abnormalities and normal LVEF without any structural heart disease and normal blood work.

On the next day of admission, the patient was transferred to electrophysiology lab, to perform 3D mapping and radiofrequency ablation.

**Results**

Under general anesthesia, the catheters were placed at CS, His, RV-apex, ICE and ablation catheter TactiCath™ was advanced over long sheath (SR0™), and used to do anatomical mapping.

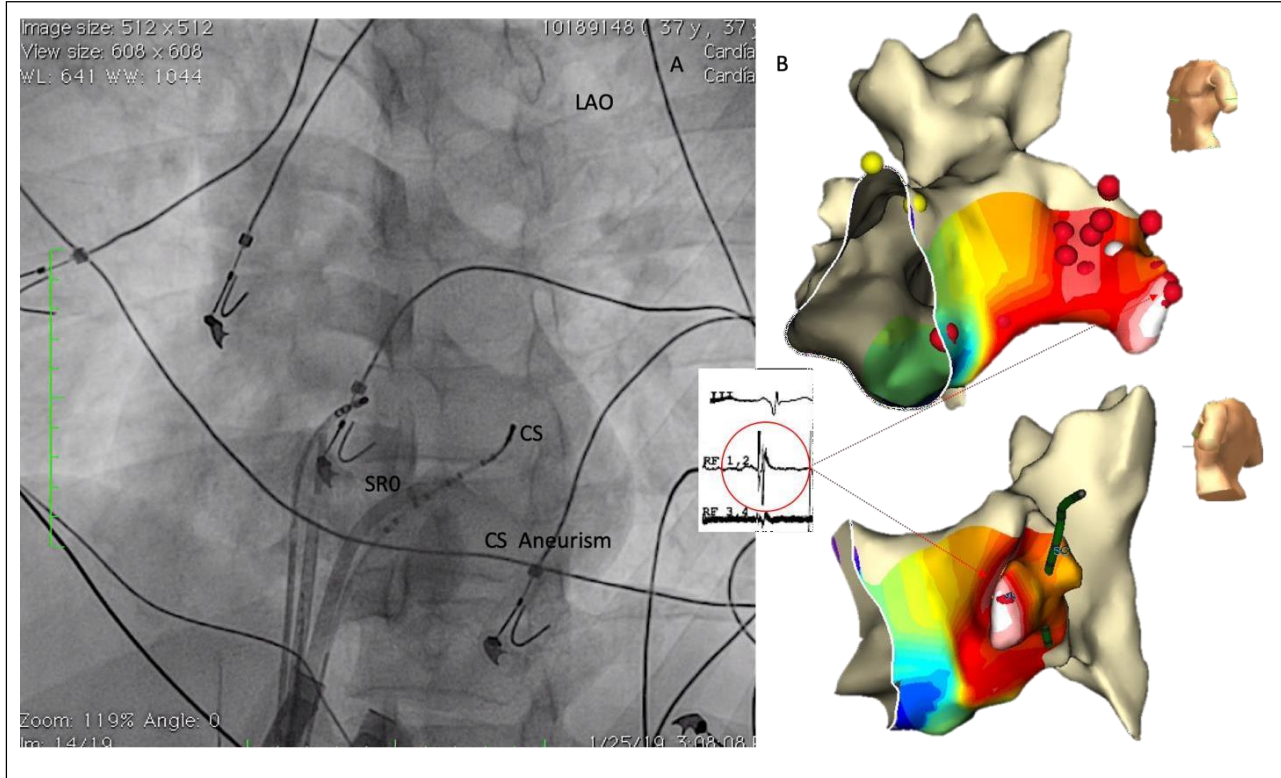
The EP study was performed, with basic intervals were: AH: 97ms, HV interval: 13ms, the antegrade refractory period of AP was less than: 600-220ms, the retrograde refractory period of AP was: 600-300ms, during AF the shortest RR was 192ms (figure2).



**Figure 2:** Rapid ventricular (192ms or 313bpm) conduction during atrial fibrillation

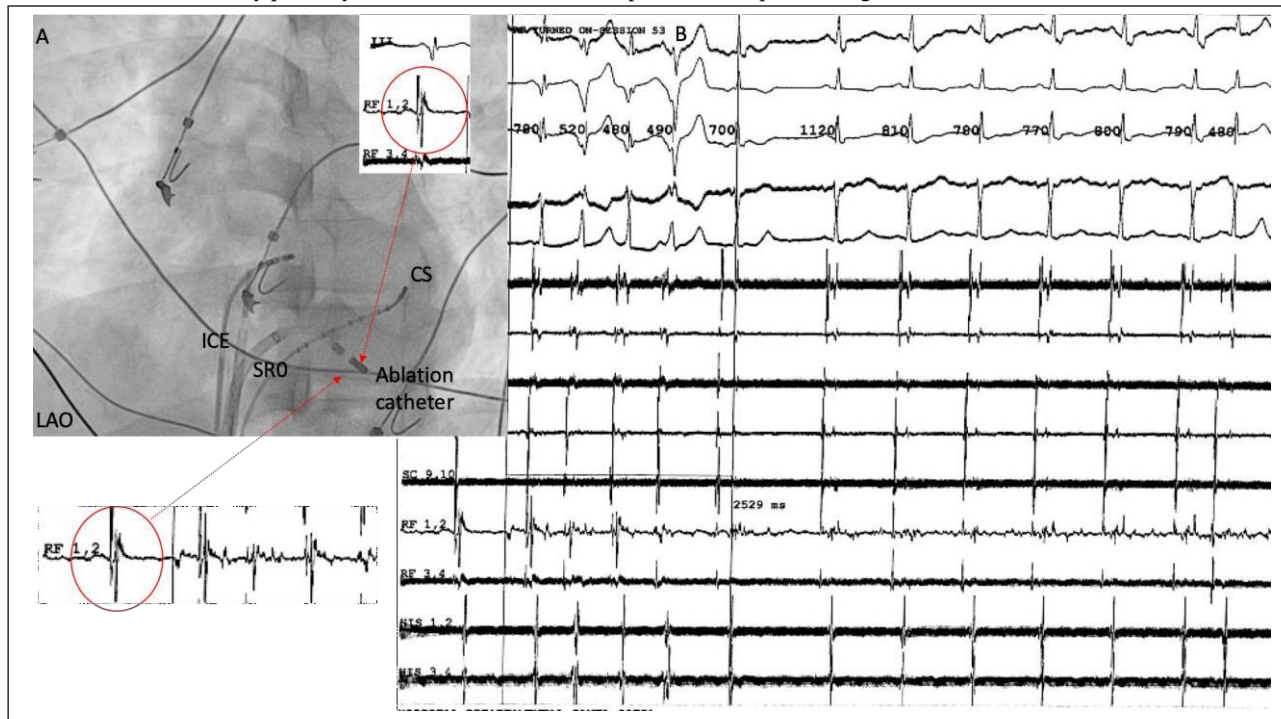


During difficult Kent potential mapping with 3d mapping system (EnSite™, St. Jude Medical™) we had discover a CS aneurism (Figure3).



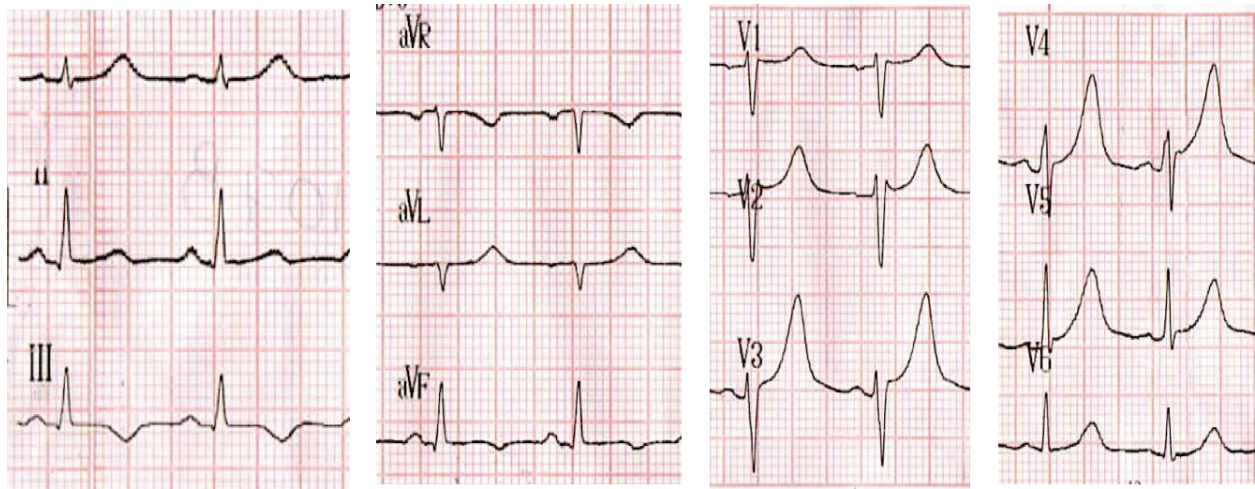
**Figure 3:** Contrast injection over SRO sheath, showing CS aneurism. B Anatomic and activation map, earliest ventricular activation during sinus rhythm was found at the apex of the aneurismal coronary sinus.

And the ablation was performed with (20 Watts and 42c up to 60 seconds) at the apical area of CS aneurism where Kent potential was mapped, with immediate elimination of accessory pathway and normalization the ECG preexcitation pattern (Figure4).



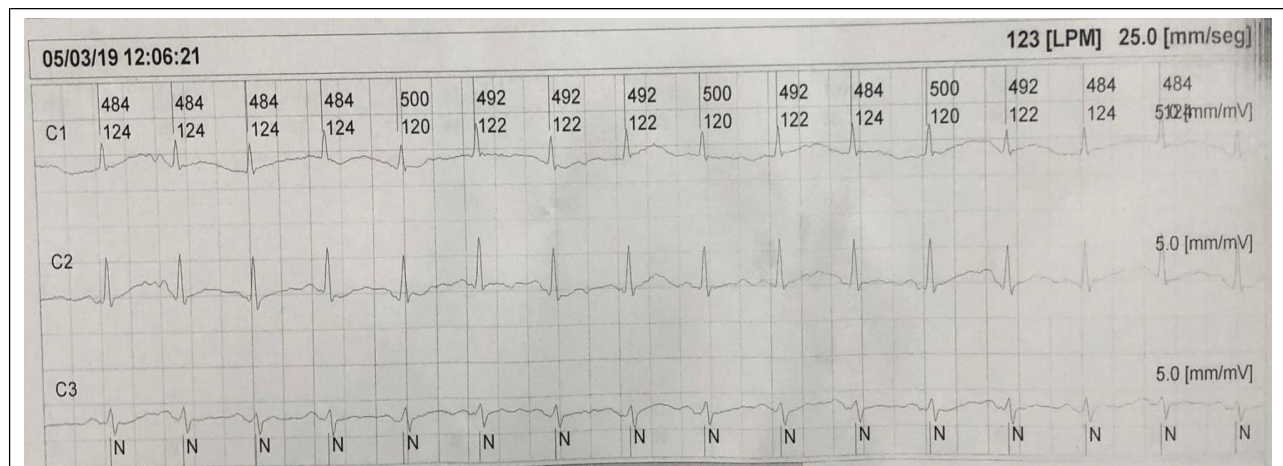
**Figure 4:** An Ablation catheter at apical part of CS aneurism. B Immediate elimination (duration 2529ms) of accessory pathway during ablation at the apical part of CS aneurism.

One day post RF. ablation an ECG showed no evidence of preexcitation pattern (Figure5).



**Figure 5:** ECG. First day post ablation, no preexcitation pattern

The patient was seen and evaluated with 24 hours Holter in the electrophysiology clinic in three month period post RF. ablation with normal ECG and preexcitation pattern (Figure6).



**Figure 6:** 24 hours Holter. Three months post ablation, showed no preexcitation pattern on the ECG.

**Discussion**

Nowadays the Wolf Parkinson White syndrome (short PR interval, delta wave and tachycardia secondary an accessory pathway conduction) are less presented than before maybe because they were successfully ablated.

Always during the EP study the electrophysiologist has the tools to evaluate the sudden cardiac death related with the abnormal accessory pathway; not only is an electric congenital anomaly but also can be present with anatomical anomalies, the ablation therapy is curative option of treatment to this pathology [2].

Wolf Parkinson White syndrome, was related with sudden cardiac death, however there is no an ECG pattern to do a right prediction, none invasive test like stress test can be useful to evaluate arrhythmia induction and refractory period over AP conduction. The EP study is the invasive strategy to allow the right evaluation of AP risk to sudden cardiac death [2, 3]

The presence of atrial fibrillation is used to evaluate rapid conduction over AP. The shortest RR interval during AF illustrated how fast can be the conduction to the ventricle. The refractory periods were described by Dr. Josephson to evaluate sudden cardiac death risk when these are less than 300ms [4].

Therefore the accessory pathways are more common at left lateral location, the presence of AP at posteroseptal space are up to 8%; 31% of these AP could be found with CS aneurysm as a result the rapid recognition of this anomaly could be a useful information to ablation. There are other venous anomalies reported with posteroseptal AP like left superior vena cava, Ebstein disease [5, 7]

However there is a description of ECG pattern for some CS aneurysm related with posteroseptal AP(QS DIII, aVF and more negative DII ), which is not typically presented as this case. The recognition of CS aneurysm allowed to perform the mapping within the CS aneurysm, nevertheless the ablation site has been described at aneurysm neck, in this



case the Kent potential was found at the apex of aneurysm where the ablation was performed and with immediate achievement of successful elimination of the accessory pathway [8-12]

## Conclusions

Wolf Parkinson White syndrome can be a challenge pathology, the right evaluation include determination of refractory periods anterograde and retrograde, induction of tachycardia, and atrial fibrillation induction to the aim to determinate if there is a sudden cardiac death risk related.

The posteroseptal accessory pathway can be found related to Coronary Sinus aneurysm, Ebstein disease or left superior cava vein.

The rapid recognition and diagnosis of the venous cardiac anomaly is useful for ablation therapy during EP study.

## Learning objectives

The posteroseptal accessory pathways can be difficult to ablate, trickiest cases are some of them who were present with: no succeed previous procedure, no clear Kent potential during mapping. As discussed before where QS at DII reported on the ECG during posteroseptal accessory pathway is a consistent pattern to have high suspicious index of CS aneurism, nevertheless other ECG pattern like the present clinical case can be found with venous cardiac anomalies.

## References

- Bautista WF, Crozier I, Sorgente A. (2019) An Electrocardiogram That Never Grows Old. JACC Case Reports [Internet]. 1(3):405–406.
- Nishimori M, Kiuchi K, Mori S. (2018) Atypical inferoseptal accessory pathway connection associated with an aneurysm of the Coronary sinus: Insight from a three-dimensional combined image of electroanatomic mapping and computed tomography. Hear Rhythm Case Reports [Internet]. 4(9):389–392
- Cohen MI, Triedman JK, Cannon BC, Davis AM, Drago F et al. (2012) PACES/HRS Expert Consensus Statement on the Management of the Asymptomatic Young Patient with a Wolff-Parkinson-White (WPW, Ventricular Preexcitation) Electrocardiographic Pattern: Developed in partnership between the Pediatric and Congenital Electrophysi. Hear Rhythm [Internet]. 9(6):1006–1024.
- Josephson ME (2016) Josephson's Clinical Cardiac Electrophysiology. 5th ed. Goolsby Julie VA, editor. Baltimore: Wolters Kluwer; 336–436 p.
- Avari JN, Rhee EK. (2008) Markers of coronary sinus accessory pathways in pediatrics. PACE - Pacing Clin Electrophysiol. 31(8):968–973.
- Selvaraj RJ, Sarin K, Singh VR, Satheesh S. (2016) Radiofrequency ablation of posteroseptal accessory pathways associated with coronary sinus diverticula.
- S JG, S WC, Sven JGRH, Zi SH, Littmann MFI, et al. (1989) The Complex Posterior Septal Space in the Wolff-Parkinson-White Syndrome Surgical Experience with 47 Patients.
- Boulos M, Gepstein L. (2004) Electroanatomical mapping and radiofrequency ablation of an accessory pathway associated with a large aneurysm of the coronary sinus. 608–612.
- Nam MCY, Wilkins M, Harris A, Dayananda N. (2017) PT Corresponding Author : J Electrocardiol.
- Hinduja M, Mishra A, Shah R. (2015) Congenital coronary sinus aneurysm. 0(0):380016.
- Di Segni E, Siegal A, Katzenstein M. Congenital diverticulum of the heart arising from the coronary sinus. Heart. 56(4):380–384
- Ho SY, Russell G, Rowland E. (1988) Coronary venous aneurysms and accessory atrioventricular connections. Heart. 60(4):348–351.



This work is licensed under Creative Commons Attribution 4.0 License

To Submit Your Article Click Here: [Submit Article](#)

DOI: [10.31579/crr.2020/002](https://doi.org/10.31579/crr.2020/002)

### Ready to submit your research? Choose Auctores and benefit from:

- ❖ fast, convenient online submission
- ❖ rigorous peer review by experienced research in your field
- ❖ rapid publication on acceptance
- ❖ authors retain copyrights
- ❖ unique DOI for all articles
- ❖ Immediate, unrestricted online access

At Auctores, research is always in progress.

Learn more [www.auctoresonline.org/journals/cardiology-research-and-reports](http://www.auctoresonline.org/journals/cardiology-research-and-reports)