

Enterocutaneous fistula; Management challenges, Aretrospective review of 11 patients treated in our institute.

Aliya Ishaq^{1*}, Muhammad Jamshaid husain Khan², Muhammad shadab khan³, Mariya Ishaq⁴, Abida Parveen⁵, Atif Latif⁶, Nadeem Khurshaidi⁷, Rufina Soomro⁸

¹Specialist general surgery and lecturer general surgery Dubai Medical College Dubai UAE.

²Specialist internal medicine Dubai hospital, UAE.

³Assistant Professor GI department SIUT.

⁴Medical officer Sindh children services hospital.

⁵Associate professor GI department SIUT.

⁶Senior specialist general surgery Dubai Hospital UAE.

⁷Consultant general surgeon, Liaquat National Hospital Karachi Pakistan.

⁸Consultant and head of general's surgery department LiAQUAT National hospital Karcahi, Pakistan.

*Corresponding Author: Aliya Ishaq, Specialist general surgery and lecturer general surgery Dubai Medical College Dubai UAE.

Received date: June 04, 2021; Accepted date: June 11, 2021; Published date: June 16, 2021

Citation: A Ishaq, MJH Khan, Muhammad s khan, M Ishaq, A Parveen, et al. (2021) Enterocutaneous fistula; Management challenges, Aretrospective review of 11 patients treated in our institute. *Journal of Clinical and Laboratory Research*. 3(1); DOI:10.31579/2768-0487/031

Copyright: ©2021 Aliya Ishaq. This is an open-access article distributed under the terms of the Creative Commons Attribution License, which permits unrestricted use, distribution, and reproduction in any medium, provided the original author and source are credited.

Abstract:

Enterocutaneous fistula is a local pathology and systemic disorder.

Objectives: To analyze postoperative outcomes, morbidity, and mortality in patients treated for enterocutaneous fistula in our institute for past 18 months.

Design, settings and patients: Reterospective review of records of patients presented to Liaquat national university hospital Karachi, Pakistan between Jan 2010 to June 2011 with diagnosis of EC fistula.

Results: A total of eleven patients presented with diagnosis of enterocutaneous fistula in our institute in specified duration. Mean age at presentation was 33 years with amle to female ratio of 3:1. 72.7 % had high output fistula and 27.2 % had low output fistula. Small bowel was involved in 72.7%, large bowel in 18.18% and 9.0% had both small and large bowel fistula. 45.45% patients had single fistula while 54.55 had multiple fistula. Total length of stay varied between 22-150 days .6/11 (54.54%) had nosocomial infection, 3/11(27.27%) had bed sores. 2/11(18.18%) had TPN related complications. Spontaneous closure occurred in 8/11(72.77) patients and definitive surgical closure was performed in one patient. Mortality rate was 18.8 %.

Conclusion: Enterocutaneous fistula is a devastating outcome for both surgeons and patients, sytemetic timely multidisciplinary approach can save lives.

Key words: enterocutaneous fistula; enteroatmospheric fistula; spontaneous closure; mortality; timeline

Introduction:

An enterocutaneous fistula (ECF) is an abnormal connection between the gastrointestinal tract and the skin or atmosphere (enteroatmospheric fistula [1] [EAF]). Estimated 75-85% are iatrogenic, occur after an abdominal surgery.

There are several ways in which ECF has been classified, including by output, etiology, and source [1, 2, 3]. Most often, a high-output ECF is characterized as one with >500 mL/24 hours, low output <200 mL/24 hours, and a moderate output fistula between 200 and 500 mL/24 hours [1].

Historical reported mortality rates as high as 10-30%. Sepsis is the leading cause of death. Other factor include high output and comorbidity. Recent reported series show a declining mortality (6-33 or less) with improving supportive care, especially nutrition [3].

There is consensus among authorities that the management of a patient with EC fistula should proceed in an ordered sequence [3].

- I. **Stabilize** the patient by fluid resuscitation and control of sepsis.
- II. **Induce** physical rebuilding and immunity with nutritional supplementation and wound management.

III. Restore intestinal continuity.

Stabilization	S N A P	Fluid Resuscitation & Sepsis Elimination
		Nutritional Supplementation & Wound Management
Induction		Anatomy Delineation
Restoration		Plan for definitive management

Treatment phases [4]

Phase	Time Course	Primary goals
1. Recognition and stabilization	24-48 hours	Correct fluid and electrolyte imbalances Drainage of intra-abdominal abscesses Control of sepsis Control of fistula drainage Ensure adequate skin care Aggressive nutritional support
2. Investigation	after 7-10 days	Determine anatomy and fistula characteristics
3. Decision	up to 4-6 weeks	Determine likelihood of spontaneous closure Plan course of therapy
4. Definitive therapy	after 4-6 weeks or if closure is unlikely	Closure of fistula Reestablish gastrointestinal continuity Secure closure of abdomen
5. Healing	5-10 days after closure onward	Ensure adequate nutritional support Transit to oral intake

Management:

Management can be divided in to three phases

Acute phase:

- Presentation usually happens 5 to 7 days after initial surgery
 - Fever, ileus, wound infection and drainage of feculent material
- This may be coupled with repair or resection of the fistula and bowel anastomosis if peritoneal reaction secondary to contamination is minimal as long as it is within the window period.

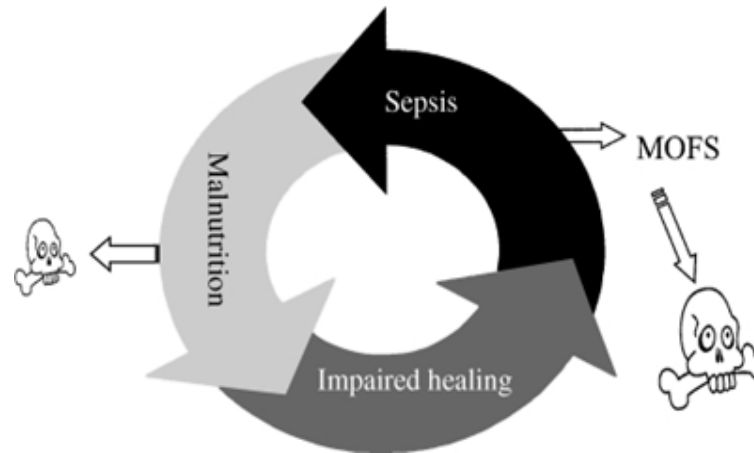
Window period:

- We define window period as the time within 7 to 12 days from the most recent laparotomy

- Within this “window period” severity of adhesions are usually milder and repeat laparotomy with the intent of diverting and or repairing the fistula is justified since caring for a well matured stoma is much easier than ECF.

Subacute phase:

- The multidisciplinary approach under the leadership of surgeon
- Enterostomal therapy nurse
- Parenteral nutrition team
- Physical and occupational therapist are important
- Continued reassurance and availability from the physician will help in this situation.
- Mortality was **12 %** compared to **55 %** in patient group receiving optimal nutrition as opposed to a group nourished suboptimally.



Repair and reconstructive phase:

- Operations to correct an ECF need to be performed under optimal conditions.
- Spontaneous closure rate varies between 60% - 80%.

Objective:

- we have noticed an increase in cases of enterocutaneous fistula in our unit ,referred to our unit from all over the country as well as from abroad for a duration between Jan 2010 to June 2011 with diagnosis of EC fistula
- This reterospetive study was conducted to look for presentation, management challenges and outcomes of patients treated in our hospital.

Materials and methods:

- It is a reperospetive observational study of 11 patients presented to our unit in last 18 months with enterocutaneous fistula.
- The study was conducted to look for management challenges and outcomes of patients with entero cutaneous fistula patients treated in our hospital.
- Records of all patients were retrospectively reviewed from the case files of patients and updates were also taken form concerned surgeons directly involved in management, patients were also contacted whenever needed.

Inclusion criteria:

All patients who presented to hospital with enterocutaneous fistula for previous 2 years were included in study. They were all primarily treated in peripheral hospitals.

Management:

We adopted the three phase approach as described above for management of all patients with ECF (entero cutaneous fistula)

In the first phase (the acute phase) recognition and stabilization of ec fistula was done. The goal of this phase was to correct fluid and electrolyte imbalances, malnutrition, sepsis,abscess formation and wound infection. These problems were addressed within first 24-48 hrs of admission.

- All patients were admitted in high dependency unit.
- Fluids given for maintenance, replacement of loss and correction electrolytes.
- Series of steps initiated to control sepsis including

- Institution of broad spectrum Antibiotics
- Exploration for drainage of intra-abdominal collections.
- Exposing the leaking loop with dynamic wound management.
- CT scan performed and other injuries and foci of sepsis excluded.

- Two patients operated in window period (both had laparotomy 4-5 days prior to admission, CT Scan showed contrast leakage from small bowel and intra-abdominal collection)
 - Somatostatin analogue given to all patients for 14 to 28 days.
 - TPN was given to all patient by a CVP or PICC line for 3 to 6 weeks.
 - Strict I/O charting, chest and limb physiotherapy done daily.

DVT prophylaxis.

The next phase was phase of anatomical delieniation.

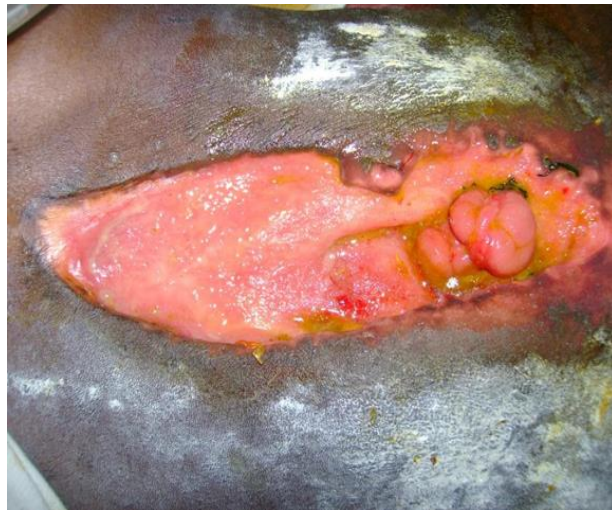- Gastrograffin used for mapping of fistula.
- Fistulas were characterized as low output if output was less than 500 ml and hight output if it was more than 500 ml.
- Entral and refeeding was also given in two patient after making control fistula.
- One had fistula at 1st part of duodenum (post pef duo repair).

Other had multiple fistulae in both small and large gut (post gun shot, multiple laparotomies.

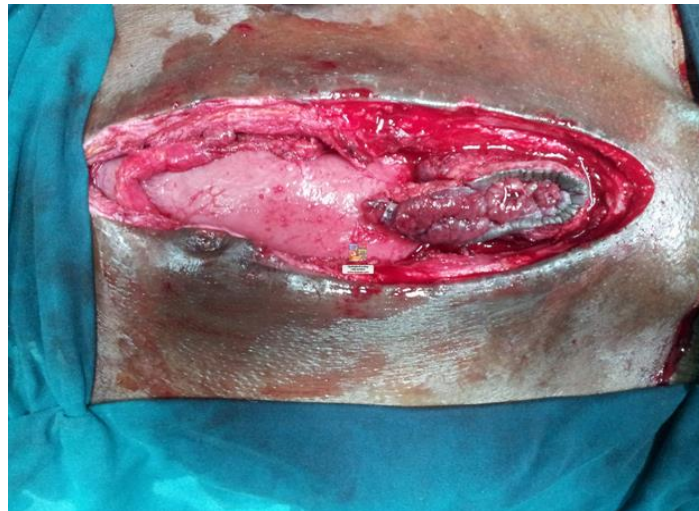Different ways used for enteral feeding. For all low output and distal fistulas enteral feeding was started immediately after delineation and predigested dietary supplements were uses. In two patients with high output proximal fistula fistuloclysis was tried that is fistula contents taken from proximal limb through a feeding tube and reinserted distally using a Foley catheter and balloon inflated with 15 ml of water, It was very difficult and messy and was not totally successful requiring loss as well as multiple time cleaning because of leakage but was continued.

One patient feeding jejunostomy was made during initial surgery while controlling the sepsis and was used for enteral feeding.

Different types of dressings and drains were used to prevent skin complications related to fistula



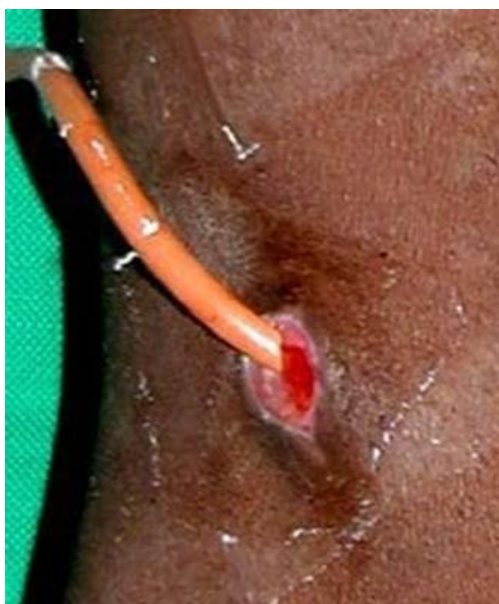Low output distal small bowel fistula.



Controlled fistula made after surgical intervention.



Magnesium sulphate paste used to prevent and treat excoriation of skin.



Fistuloclysis using Foley Catheter for refeeding in distal fistula.

Dressings used:

- Suction and irrigation dressing
- Vacuum dressing
- Simple dressing
- Application of stoma bag at site of single wound

In the final phase, definitive operation was done including fistula resection and resection anastomosis and biological mesh was used to

reconstruct abdominal wall (one patient)

Results:

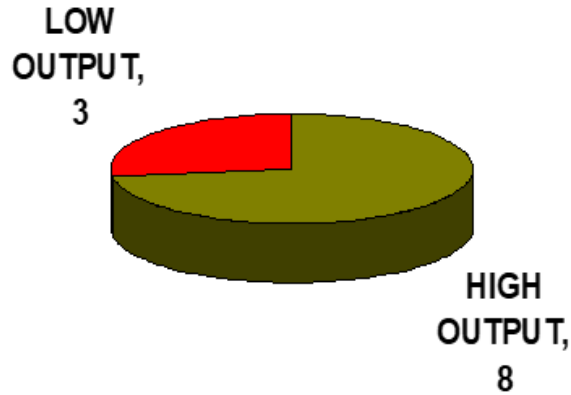
- Total no of patients managed: 11 in last 18month.
- Mean age at presentation: 33 yrs (Range: 15 - 45)
- Male to female ratio: 3:1

Type of fistula:

AGE/SEX	TYPE	NUMBER	LOCATION	CAUSE
45/MALE	HIGH OUTPUT	SINGLE	LARGE BOWEL	POST GUNSHOT ANASTOMOTIC LEAKAGE
25/MALE	HIGH OUTPUT	MULTIPLE	SMALL BOWEL	POST GUNSHOT ANASTOMOTIC LEAKAGE AND PREVIOUS MULTIPLE SUGERIES
25/MALE	HIGH OUTPUT	MULTIPLE	SMALL BOWEL	POST GUNSHOT ANASTOMOTIC LEAKAGE
22/MALE	HIGH OUTPUT	MULTIPLE	SMALL BOWEL	POST GUNSHOT ANASTOMOTIC LEAKAGE
30/MALE	HIGH OUTPUT	SINGLE	DUODENUM	POST PEF DUO REPAIR
38/FEMALE	HIGH OUTPUT	MULTIPLE	LARGE AND SMALL BOWEL	PREVIOUS MULTIPLE SUGERIES AND ANASTOMOTIC LEAKAGE
45/FEMALE	LOW OUTPUT	SINGLE	LARGE BOWEL	POST GUNSHOT ANASTOMOTIC LEAKAGE
35/FEMALE	HIGH OUTPUT	MULTIPLE	SMALL BOWEL	POST C-SECTION
38/MALE	HIGH OUTPUT	MULTIPLE	SMALL BOWEL	POST GUNSHOT ANASTOMOTIC LEAKAGE
15 /MALE	LOW OUTPUT	SINGLE	SMALL BOWEL	POST GUNSHOT ANASTOMOTIC LEAKAGE AND PREVIOUS MULTIPLE SUGERIES
40/MALE	LOW OUTPUT	SINGLE	SMALL BOWEL	POST GUNSHOT ANASTOMOTIC LEAKAGE AND PREVIOUS MULTIPLE SUGERIES

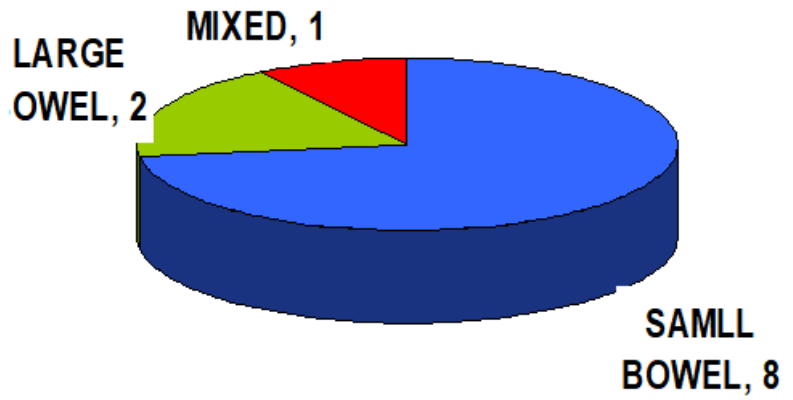
- High output: 72.7%

- Low output: 27.2%



Location of fistula:

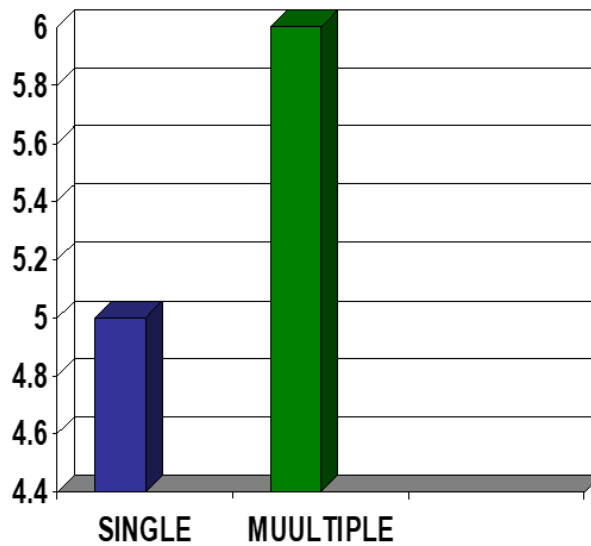
- Small bowel: 72.7%
- Large bowel: 18.18%



- Small and Large bowel: 9.0%

No of fistulae:

- Single: 45.45%
- Multiple : 54.54%



- Except for 3 patient all presented with sepsis and were nutritionally depleted.
- **Morbidity:**
 - Recurrence: 1 out of 2 in surgically treated patient
 - Readmissions: 1
 - Length of hospital stay: 22 – 150 days.
 - Nosocomial infections: 6
 - Bed sore: 3
 - TPN related complications: 2
 - Line sepsis: 2
 - CVP Line: Out of 6, 2 had sepsis
 - PICC Line: Out of 5 none had sepsis
 - Mortality: 2 (18.18%)
 - Cause of mortality include multiple proximal high output fistulae and severe sepsis.
- Spontaneous closure: 8 out of 11(72.7%) in 20 days to 3 months period.
- Defenitive procedure after sub-acute phase: 1 out of 11 after 6 months of conservative treatment.
- Patients died in sub-acute phase: 2 out of 11

Discussion:

The enterocutaneous fistula (ECF) is a devastating complication for both surgeons and patients alike. Prior to the advent of sophisticated critical care support and parenteral nutrition, the development of an ECF nearly equated to a death sentence. In the current era, the mortality rate has been reduced to 5 to 20% [5, 6]. However, the development and management of an ECF remains a chronic, debilitating condition [5].

We used the standard approach described by Schecter et al [6] for the management of EC fistula that is divided in 3 phases, first phase includes recognition and stabilization, so patients after being diagnosed with having EC fistula were admitted in high dependency unit and correction of electrolytes and fluid balances were done along with control of fistula and sepsis source control. Patients with severe sepsis underwent ct scan abdomen with contrast in initial phase and those having intrabdominal collection and sepsis were taken to operation theater and drainage of abscess with controlled fistula formation was done as well as feeding jejunostomy was made in 2 cases, specialized vacuum dressings with laparostomy and vicryl mesh placement in presence of controlled fistula was performed in 2 patients. Broad spectrum antibiotics were started as per pus culture and blood transfusion was started when indicated. Parenteral nutrition was started in almost all patients and few of them with low output fistula were started on enteral feeding as well. Daily electrolytes and weight measurements were taken and strict in put out put charting was done along with chest and body physio and DVT prophylaxis

The provision of total parenteral nutrition has been associated with an increased rate of spontaneous closure of fistulas in several series [9, 10, 11]. Parenteral nutrition has long been recognized to be an integral part of the management of enterocutaneous fistulas [9, 10]. We started TPN in all patients after insertion of PICC line /central line in acute phase. We don't have enough number of patients to determine that correlation.

After 7 to 10 days, the patient has generally stabilized, and the fistula has matured to the point of supporting intubation of thin catheters in all orifices. At this point, the patient should undergo fluoroscopic fistulography with water-soluble contrast under the direct supervision of a senior radiologist and the senior surgeon responsible for the patient's care. The information gained by such a study includes (1) the source of the fistula; (2) the nature (length, course, and relationships) of the fistula tract; (3) the absence or presence of bowel continuity (end vs. side fistula); (4) the absence or presence of distal obstruction; (5) the nature of the bowel adjacent to the fistula (inflammation, stricture); and (6) the absence

or presence of an abscess cavity in communication with the fistula. The fistulogram provides information not obtainable through any other study, and early films can be particularly useful in defining anatomy and relationships. As previously discussed, water-soluble contrast may also be injected into abscesses at the time of drainage as a type of early fistulogram [9]. In our study. After the phase of stabilization and defining fistula output fistulogram was done to delineate the site of fistula and bowel anatomy and then same management with dressings, TPN, enteral feeding, different dressings, wound and skin care using zinc oxide was continued including fistuloclysis and patients were observed for a period of 3- 6 months.

We did not have a large enough sample to determine which factors determine good outcomes for enterocutaneous fistulas. However, several studies from other centers have looked at this. Using multiple logistic regression analysis, Visschers et al [15]. Found that intact abdominal walls and administration of parenteral nutrition were independent predictors of spontaneous closure of enterocutaneous fistulas. In our study Spontaneous closure was achieved in 3 months in 72.7 % cases without need for surgery and surgical intervention was done in 1 patient after completing 6 months of conservative treatment with mature fistula and repeat imaging using ct scan and fistulogram was done prior to surgery and excision of fistula followed by reconstruction and diversion ileostomy and abdominal wall reconstruction was done. 2 of our patients died in sub-acute phase because of high output fistula and severe sepsis. Our mortality rate is 18.8% which is comparable to most institutes specialized in management of ECF.

Conclusion:

Enterocutaneous fistula is a local pathology and systemic disorder with major impact on patient's psychology, finance emotions and wellbeing. Given that most are iatrogenic, the most effective means of treatment is prevention with sound surgical judgment and meticulous technique. However, when faced with the development of an ECF, early recognition with systemic orderly approach by a multidisciplinary team specialized in treatment of these challenging patients can save lives.

References:

1. Qin-qing Tang et al. (2020) Nutritional Management of Patients with Enterocutaneous Fistulas: Practice and Progression. Review article Front.

2. Gribovskaja-Rupp I, Melton GB. (2016) Enterocutaneous Fistula: Proven Strategies and Updates. *Clin Colon Rectal Surg.* 29(2):130-137.
3. Y-JOUR, Evenson, Fisher, Josef, current management of enterocutaneous fistula. *Journal of gastrointestinal surgery : official journal of the Society for Surgery of the Alimentary Tract.*
4. Amabra Dodiya-Manuel, Promise N. Wichendu. (2018) Current concepts in the management of enterocutaneous fistula.
5. Irving M, White R, Tresadern J. (1985) Three years' experience with an intestinal failure unit. *Ann R Coll Surg Engl.* 67(1):2-5.
6. Draus JM, Jr, Huss SA, Harty NJ, Cheadle WG, Larson GM. (2006) Enterocutaneous fistula: are treatments improving? *Surgery.* 140(4):570-576. discussion 576-578.
7. Visschers RG, Olde Damink SW, Bekkum M van, Winkens B, Soeters PB, Gemert WG van. (2008) Health-related quality of life in patients treated for enterocutaneous fistula. *Br J Surg.* 95(10):1280-1286.
8. Schechter WP, Hirshberg A, Chang DS, Harris HW, Napolitano LM, Wexner SD, et al. (2009) Enteric fistulas: principles of management. *J Am Coll Surg.* 209:484-491.
9. Soeters PB, Ebeid AM, Fischer JE. (1979) Review of 404 patients with gastrointestinal fistulas: Impact of parenteral nutrition. *Ann Surg.* 190:189-202.
10. Hill GL, Bouchier RG, Witney GB. (1988) Surgical and metabolic management of patients with external fistulas of the small intestine associated with Crohn's disease. *World J Surg.* 12:191-197.
11. Rose D, Yarborough MF, Canizaro PC, Lowry SF. (1986) One hundred and fourteen fistulas of the gastrointestinal tract treated with total parenteral nutrition. *Surg Gynecol Obstet.* 163:345-350.
12. MacFadyen BV Jr, Dudrick SJ, Ruberg RL. (1973) Management of gastrointestinal fistulas with parenteral hyperalimentation. *Surgery.* 74:100-105.
13. Rose D, Yarborough MF, Canizaro PC, Lowry SF. (1986) One hundred and fourteen fistulas of the gastrointestinal tract treated with total parenteral nutrition. *Surg Gynecol Obstet.* 163:345-350.
14. Aguirre A, Fischer JE, Welch CE. (1974) The role of surgery and hyperalimentation in therapy of gastrointestinal-cutaneous fistulae. *Ann Surg.* 180:393-401.
15. Visschers RG, Olde Damink SW, Winkens B, Soeters PB, van Gemert WG. (2008) Treatment strategies in 135 consecutive patients with enterocutaneous fistula. *World J Surg.* 32:445-453.