

Myxedema on the Bilateral Upper Eyelids of a Diagnostic Clue of Hypothyroidism

Anthony Daniel

Department of Dermatology, Mycotic Diseases Branch, USA.

*Corresponding Author : Anthony Daniel, Department of Dermatology, Mycotic Diseases Branch, USA. E-mail: a.daniel@gmail.com

Received date: February 06, 2018; Accepted date: February 26, 2018; Published date: March 05, 2018

Citation : Anthony Daniel, Myxedema on the Bilateral Upper Eyelids of a Diagnostic Clue of Hypothyroidism. J .Dermatology and Dermatitis. Doi:10.31579/2578-8949/023

Copyright : ©2018 Anthony Daniel. This is an open-access article distributed under the terms of The Creative Commons Attribution License, which permits unrestricted use, distribution, and reproduction in any medium, provided the original author and source are credited.

Letter

Localized myxedema may be observed in hypo/hyperthyroidism [1]. However, the affected sites are usually pretibial area and the lesion on the eye lid is rare. We report a case of myxedema on the bilateral upper eyelids, which was a diagnostic clue of hypothyroidism associated with Hashimoto disease.

A 42-year-old Japanese woman presented with upper eyelid swelling of 2 months duration (Figure 1a). She did not complain muscle weakness or myalgia. She showed no dry coarse skin, tremors of the hands, thick tongue, or loss of hair. Histopathology of the skin biopsy revealed swelling of the collagen bundles with splitted individual fibers accompanied with pale material (Figure 1b), which was stained with blue with colloidal iron (Figure 1c). Laboratory investigation revealed decreased free T4 (0.88 ng/ml (1-1.8)), decreased free T3 (1.12 pg/ml (2.73-4.5)), and increased TSH (10.34 IU/ml (0.27-4.29)). Anti-thyroid, anti-microsome, anti-thyroglobulin and anti-thyroid peroxidase antibodies were positive. Total cholesterol (286 mg/dl) and triglyceride (342 mg/dl) were elevated. Other laboratory findings including anti-nuclear antibody, aldolase, creatine kinase, and angiotensin-converting enzyme showed normal results. Echo examination disclosed slight but diffuse swelling of thyroid gland. Chest X-rays showed no abnormality and no malignant disease was detected in CT. The patient was diagnosed as localized myxedema with hypothyroidism due to Hashimoto disease. After three months of thyroid hormone replacement therapy, the skin lesions gradually improved accompanied with euthyroidic state. We got the informed consent form the patient.

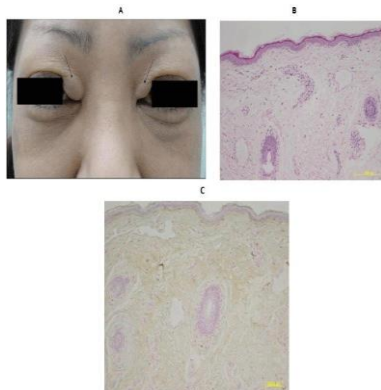


Figure 1: Patient's clinical and histopathological findings. (a): Edema of bilateral upper eyelids. The arrows show the edema lesions. (b): H-E staining showed swelling of the collagen bundles with splitted individual fibers. (c): Colloidal iron stain disclosed the presence of mucin.

Localized myxedema tends to be observed in hyperthyroidism on the anteriolateral aspect of lower legs as pretibial myxedema. In hypothyroidism, generalized myxedema is usually observed with hair loss, dryness of the skin, and hoarseness. In hypothyroidism loss of eyelashes and eyebrows, especially on the temporal side, and puffiness of eyelids are the main features [2]. Mahto described the puffiness of eyelids as a significant complication of myxedema [2]. However, the reports of the eyelid myxedema in thyphoidism are few and Ohtsuka et al., reported myxedema on the skin including both eyelids in hypothyroidism [3]. Our case is the second of localized myxedema with lesions restricted on the upper eyelids. Clinical differential diagnosis may include dermatomyositis, which was negated by laboratory findings of normal muscle enzyme activity, no increase in anti-nuclear antibody, and no liquefaction degeneration of basal cell layer of epidermis in histopathology.

We report a case of myxedema on the upper eyelids, which may be a clue of diagnosis of hypothyroidism.

References

1. Lynch PJ, Maize JC, Sisson JC (1973) Pretibial myxedema and non-thyroid disease. Arch Dermatol 107: 107. doi:10.1001/archderm.1973.01620160075024
2. Mahto RS (1972) Ocular features of hypothyroidism. Br J Ophthal 56: 546-549 .
3. Ohtsuka A, Yamakage A, Yamazaki S (1999) Deram mucinosis and musculoskeletal symptoms simulating polymyositis as a presenting sign of hypothyroidism. Eur J Dermatol 9: 227-229 .