

# The serious eye inflammation of post intraocular Avastin injection

Fathy Abdolmejed<sup>1\*</sup>, Khalid Almajri<sup>2</sup>, Ghamela Ali<sup>3</sup>

<sup>1</sup>Ophthalmology Department, Tobruk University, Tobruk,

<sup>2</sup>Ophthalmology department, Omer Al Mukhtar University, Derna,

<sup>3</sup>Pediatric Department, Tobruk University, Tobruk.

\*Corresponding author: Fathy Abdolmejed, Ophthalmology Department, Tobruk University, Tobruk

Received date: August 26, 2020; Accepted date: September 07, 2020; Published date: September 14, 2020

Citation: Rashid M., Rashid M., and Thompson I., (2020) With advances in information technology can we minimise errors in histopathology?. J. Archives of Medical Case Reports and Case Study. 3(2); DOI:10.31579/2692-9392/018

Copyright: © 2020 Fathy Abdolmejed, This is an open access article distributed under the Creative Commons Attribution License, which permits unrestricted use, distribution, and reproduction in any medium, provided the original work is properly cited.

## Abstract

Retrospective statistical study a collection of all patients with post intra vitreal injection (IVI) endophthalmitis in last 10 year period between 2010–2019 in eye department of Tobruk medical center -Tobruk and eye department of Alwahda hospital - Derna. We aim in this study to review the microbiology, clinical characteristics, diagnosis, and management strategies of post-intra vitreal injection endophthalmitis, by comparing our results with the different studies designs and treatment protocols. There were 9 patients of the after intra vitreal injections endophthalmitis cases. The age average is 70 years, 6 cases are females and 3 cases are male, all of them were practice post intravitreal Avastin injection endophthalmitis. There were 8 patients had Diabetes mellitus (DM), 2 patients had cardiovascular disease and 1 patient had hepatitis C as a systemic disease. The most common causative organism after intra vitreous injection endophthalmitis is *Coagulase-negative staphylococci* (CNS) 100% from the 56% positive causative organisms and 44% are no detected microorganisms, the outcome of cases which managed with pars-plana-vitrectomy (PPV) improved significantly about 60 Letters (> 3 Lines) and cases managed without PPV > 15 Letters (> 3 Lines). The cases of post intraocular endophthalmitis which diagnosed and treated early with PPV give a good result and can save the vision. The cases of acute POE in the first 3 day had significant better function (P value = 0.02).

**Keywords:** Endophthalmitis; Intra vitreal injection; Tobruk-Derna – Libya

## Abbreviations and Acronyms

CNV	: Coagulase-negative-staphylococci
PPV	: Pars-plana-vitrectomy
IVI	: Intra vitreal injection
VEGF	: Vascular endothelial growth factor
DM	: Diabetes mellitus
CME	: Cystoids macular edema
DMP	: Diabetic maculopathy
AMD	: Age related maculopathy
VA	: Visual acuity
LP	: Light perception

## Introduction

Endophthalmitis is a severe intraocular inflammation, due to bacterial or fungal infection, including involvement of the vitreous and/or aqueous humors. It can causes permanent damage to retinal photoreceptors that may lead to partial or complete loss of vision, even with intensive medical and surgical management. For that reason, endophthalmitis is an emergency condition. Endophthalmitis can be caused by either exogenous (micro-organisms diffuse inside the eye through surgery or

trauma) or endogenous (through blood from inside the body, through infection or sepsis), [Callegan, Engelbert, Parke and Gilmore 2002].

The post intraocular injection is a rare postoperative endophthalmitis. This is 0.03%-0.072% of all cases of anti-endothelial vascular growth factor (VEGF) injection [Hoevenaars et al., 2012; Park, Ramasay, Shaw, Prasad & Ling, 2014]. The most common causative organisms are CNS, *Staphylococcus aureus* and *Streptococci viridians*. The post anti VEGF injection endophthalmitis in general has a moderate visual outcome 6/60 [Dhoot, Kunjukuju, et al 2013, Solborg Bjerrum S, Kiilgaard JF ,et al, 2013].

The most common cases post intra vitreal injection endophthalmitis occur in first (3-4) days after operation. In this type the bacterial endotoxins and other bacterial products appear to cause direct cellular injury or indirectly enhance the inflammatory effect. [Solborg Bjerrum S, Kiilgaard JF, et al. 2013].

After the introduction of bacteria into the posterior segment, endophthalmitis follows one of two following paths: mild inflammation with effective treatment, which lead recovery of infection, or severe inflammation, not controlled with treatment, which lead to vision loss. [Callegan, Engelbert, Parke and Gilmore 2002].

The most common causes of endophthalmitis are from the patient's conjunctival flora, contamination of sterilised instruments, disposable

supplies, solutions, surgical field, or the intraocular lens. [Fang, Y. T., Chien 2006]

Most patients with post-operative endophthalmitis complain from pain and visual loss, and present with signs of conjunctival injection, fibrinous exudation, hypopyon and vitritis. [Rudnisky, Wan, et al. 2013]

There are some methods in management of postoperative endophthalmitis, including prophylaxis, medical and surgical.

Prophylaxis: Following are some examples of prophylaxis: Treatment of pre-existing infections: for example: blepharitis, conjunctivitis, of same eye or contralateral eye [Dancer SJ, Stewart M, et al. 2012 ].

Instillation of 5% povidone iodine into the conjunctival fornices, at least 3-5 minutes prior to operations [Ciulla, Starr, Masket 2002, Joseph S Bertino, 2009]. Scrupulous preparation of the surgical site [Schein OD. 2007, Beyea SC . 2004].

Prophylactic antibiotics: Pre-operative topical fluoroquinolone given in regimens 1 hour to 3 days before operation. But in some studies does not appear to protect against POE [Hollands H, Wong J, 2007], while other studies say it is protective if used postoperatively [Rudnisky C, Wan D, 2013], protective patch will be placed over the eye following surgery on the day of surgery [Behrens-Baumann, Frank, Neß, 2010, Wallin et al. 2005].

There are four methods to confirm the diagnosis; [1] taking aqueous samples and vitreous samples. [2] conjunctival swabs [3] ultrasound to confirm the posterior segment involvement in the case of the cloudy anterior segment. [Malhotra, Mandal, et al. 2008]; [4] polymerase chain reaction (PCR), which can detect a small amount of bacterial DNA. [Cornut, Boisset, et al. 2013, Barry, Cordovés, et al. 2013]. The use of this technique is not without disadvantages, as there is a false-positive rate of 5%, due to sample

contamination [Beselga, Campos et al. 2013, Zenith, Rose, Chan. 2012].

Medical treatment of POE: The diagnosis of POE should be prompt and treatment must be initiated as early as possible [Yannuzzi, Patel, 2014]. Endophthalmitis cases can be treated successfully if properly managed and useful vision can be retained [Novosad and Callegan 2011].

Topical antibiotics; which are used to protect the wound from infection but have limited benefit [Lundström, Wejde, et al. 2007]. Topical dexamethasone; which can be used initially 2-hourly in the severe cases. Topical mydriatic; which can be used twice daily.

Systemic medication: Systemic antibiotics: although some studies suggested systemic antibiotic treatment had no effect on the course and outcome of endophthalmitis, however, most recent retrospective still advise to use two types of broad spectrum systemic antibiotics to cover

both gram positive and gram-negative organisms, the most commonly used antibiotics, for example: vancomycin 2x 1g i.v. to cover gram-positive organisms, and a third-generation cephalosporin (ceftazidime) 3x 2g i.v. to cover gram-negative organisms, [Novosad and Callegan 2011, Bertino, 2009]. In case of alternative clindamycin 3x 600 mg oral plus ciprofloxacin 2x 750 mg oral or 3x 400 mg i.v. [Behrens-Baumann, Frank, 2010].

Systemic steroid must be used in severe cases of endophthalmitis to limit the destructive complications of the inflammatory process, but should exclude fungal infections.

Intravitreal antibiotics and steroids: [Silver standard]; An intra-vitreous injection of antibiotic should be immediately given to decrease the concentration of most organisms and quickly sterilize the eye. [Behrens-Baumann-2011 and Pham 2005].

The most commonly used antibiotics are ceftazidime and vancomycin [Beselga D, Campos A, Castro M, et al. 2013]. Intra-vitreous administration of dexamethasone may block of the immune response, and decrease progressive damage to the intraocular tissues [Rehak. Blatz. Meier 2008].

Surgical treatment: Pars-plana-vitreotomy (PPV) is used for surgical treatment: [Gold Standard]; If a vitreoretinal surgeon and equipped operating room are available. The best method of treatment is immediate PPV, to decrease the chance of bacterial toxins to attack the retinal photoreceptors. Clearing the posterior segment and maintenance of transparency and vitreal diffusion, leading to faster recovery of vision [Behrens-Baumann-2011 and Rehak, Blatz and Meier, 2007].

## Materials and Methods

Retrospective study done through collection of the data from the Statistic office in Tobruk medical center-Tobruk and Alwahda hospital-Derna. The recorded data included clinical features of the most serious complication (endophthalmitis) of the post intra vitreal Avastin injection; the data was collected are visual acuity at diagnosis, age and sex of the patients, time of the disease, type, type of management. Additionally classified were operations protocol, type of organism that caused the disease, lab findings, systemic and local disease of affected patients, and the outcome for the patient through the VA findings. We depend on Ranges of vision loss and reading performance (Tab. No. 1) to get the result of improvement of vision cases of post intraocular Avastin injection endophthalmitis (improvement of vision > 3 lines i.e > 15 letters on visual chart considered clinically a significant improvement). Statistical analysis was performed using Microsoft Office Excel program. Nominal and statistical significant variables were analysed using t- test for two samples. P value ≤ 0.05 or level (95%) was considered statistically significant.

*Ranges (ICD-9-CM)	Decimal VA	1 m (Low Vision)	**MAR (1/V)	**Log MAR	**Visual Acuity Score (letter count)
<b>Range of Normal Vision</b>	1.6	1/0.63	0.63	-0.2	110
	1.25	1/0.8	0.8	-0.1	105
	1	1/1	1.0	0	100
	0.8	1/1.25	1.25	+0.1	95
<b>Mild Vision Loss</b>	0.63	1/1.6	1.6	0.2	90
	0.5	1/2	2	0.3	85
	0.4	1/2.5	2.5	0.4	80
	0.32	1/3.2	3.2	0.5	75
<b>Moderate Vision Loss</b>	0.25	1/4	4	0.6	70
	0.2	1/5	5	0.7	65
	0.16	1/6.3	6.3	0.8	60
	0.125	1/8	8	0.9	55
<b>Sever Vision Loss</b>	0.1	1/10	10	+1.0	50
	0.08	1/12.5	12.5	1.1	45
	0.063	1/16	16	1.2	40
	0.05	1/20	20	1.3	35
<b>Profound Vision Loss</b>	0.04	1/25	25	1.4	30
	0.03	1/32	32	1.5	25
	0.025	1/40	40	1.6	20
	0.02	1/50	50	1.7	15
<b>Near Blindness</b>	0.016	1/63	63	1.8	10
	0.0125	1/80	80	1.9	5
	<b>FC</b>			1.98	1
	0.01	1/100	100	2	0
	<b>HM</b>			2.28	
	<b>PL</b>			3	
<b>Blindness</b>	No PL			4	

**Table 1:** Ranges of vision loss and reading performance:

\*modefide Table. ICD 9 Ranges of vision loss and reading performance

\*\* modefide Table. Recomendation of the DOG to quality assurance of neurophysiological tests and advice version-11

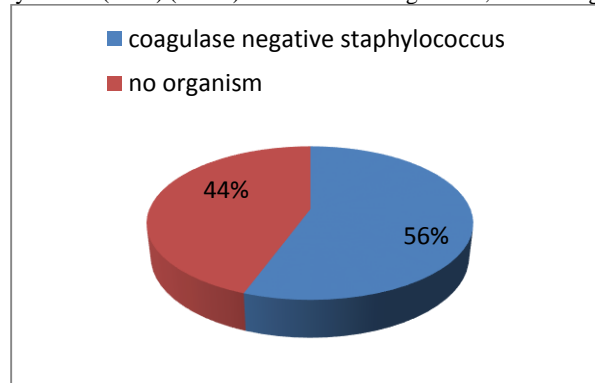
## Results

Out of the 9 recorded patients of intravitreal injections endophthalmitis cases, there were 8 patients which receive the medication for treatment of diabetic macular edema, one case for treatment of age related macular degeneration AMD. The age average is 70 years, 6 cases were females and 3 cases were male, all of them were practice postoperative endophthalmitis. There were 8 patients had DM, 2 patients had heart disease and 1 patient had hepatitis C as a systemic disease.

There were 8 cases (89%) where complain from pain, redness and blurred of the vision and one case were pain non remarkable. There were 5 cases presented with synechia and hypopion in the anterior chamber and 4 cases without hypopion, all of the cases were with cells in anterior chamber and vitreous. All the cases after intravitreal medication injections where is acute i.e. the endophthalmitis occurs < 28 days, the most is in the first 10 days, and there are (66.7%) of cases occurs at first 3 days.

The most common causative organism after intra vitreous injection endophthalmitis is Coagulase-negative staphylococci (CNS) (100%) from

the 56% positive causative organisms and 44% are no detected microorganisms, see the Figure



**Figure1:** causative organisms of post intravitreal injection endophthalmitis:

There were 6 patients (66.7%) from all cases of after intravitreal injection were presented with near Blindness vision and two cases with sever blurred of vision and one case with mild blurred of vision. There were 7 patients managed with PPV + intra vitreous medication injection with washing the anterior chamber. The Log MAR Loss of Vision average at diagnosis is 1.98 and at discharge (after receive their management) is 1.3, the vision improved significantly after the management about 30 Letters i.e. improved (> 6 Lines). Although the cases which managed with PPV had worsen visual acuity at time of diagnosis Log MAR 2.1 they had clinically better outcome after the management Log MAR 1.5 than the cases which managed without PPV (Log MAR at diagnosis 1.7 and 1.3 after the management), i.e. the outcome of cases of PPV improved significantly about 60 Letters (> 10 Lines) and cases managed without PPV >15 Letters (> 3 Lines).

## Discussion

Avastin is anti-vascular endothelial growth factor (anti-VEGF), these therapy has improved the quality of life for many patients with diabetic maculopathy, age-related macular degeneration, and other ocular diseases involving neovascularization and retinal edema. In these pathologies, the inhibition of intraocular VEGF is the only therapy that can preserve vision. [Semeraro et al., 2015].

Adverse events following intravitreal anti-VEGF injections has no relation to underlying ocular disease. The most common complications of intravitreal injection (IVI) are injection site discomfort, subconjunctival hemorrhage, vitreous reflux, transient increased intraocular pressure (IOP) and defect in the vision. The patient may also develop floaters, vitreous or retinal hemorrhage, and retinal detachment. [Frenkel MP, Haji SA & Frenkel RE, 2010]. The most serious complication of intravitreal injection is endophthalmitis and loss of vision. [Aiello et al., 2004].

In post intravitreal medication injection endophthalmitis, 44% of cases had positive organisms, all were Coagulase-negative staphylococci, making the most common causative organism in post- intravitreal medication injection endophthalmitis, was suggested with other studies. (Lyll et al. 2012 and Shah et al. 2011). The all cases of post- intravitreal medication were acute < 28, there were 6 patients (66.7%) occurred as acute endophthalmitis in the first 3 days after the injection. (Hoveenaars 2012 and Shah 2011).

Hoevenaars 2012 and Rudnisky 2013 reported the most cases of post IVI endophthalmitis cases treated with tap and injection of antibiotic. There were 7 patients (55.6%) had managed with PPV and intravitreal injection of antibiotic (vancomycin and dexamethasone), 2 patients had managed with only intravitreal injection of antibiotic (vancomycin and

dexamethasone) and there are 2 patients which had managed only with conservative treatment.

Peter Barry, Luis Cordovés, et al. 2013 and Zenith H. Y. Wu, Rose P. S. Chan, 2012, which advised immediately PPV make a significant outcome improvement cases of postoperative endophthalmitis, there were 7 patients managed with PPV + intra vitreous medication injection with washing the anterior chamber, the vision improved significantly after the management about 30 Letters i.e. improved (> 3 Lines). Although the cases which managed with PPV had worsen visual acuity at time of diagnosis they had clinically better outcome after the management than the cases which managed without PPV, i.e. the outcome of cases of PPV improved significantly about (> 10 Lines) and cases managed without PPV Letters (> 3 Lines).

## Conclusion

Although the postoperative endophthalmitis is sight threatening infection and destructive emergency disease, the appropriate prophylaxis is remain the best way of infection prevention. The delayed presentation, inappropriate management procedures, and severity of causative organism may account for the unfavorable visual outcome. In general post intravitreal endophthalmitis cases can be treatable condition especially when had diagnosed and managed early time with intravitreal antibiotics and early pars-plana-vitreotomy. Statistically we consist, the cases of acute intravitreal endophthalmitis in the first 3 day had significant better function outcome (P value = 0.024).

## Acknowledgement

We would like to thank Mr. Hafez E.L Mansour (Lecturer at Tobruck University) for his help with data retrieval and statistical analysis.

## References

1. Aiello, L. P., Brucker, A. J., Chang, S., Cunningham, E. T., Jr, D'Amico, D. J., Flynn, H. W., Jr, Grillone, L. R., Hutcherson, S., Liebmann, J. M., O'Brien, T. P., Scott, I. U., Spaide, R. F., Ta, C., & Trese, M. T. (2004). Evolving guidelines for intravitreal injections. *Retina (Philadelphia, Pa.)*, 24(5 Suppl), S3-S19.
2. Barry P, Cordovés L, Gardner S.(2013). ESCRS Guidelines for Prevention and Treatment of Endophthalmitis following Cataract Surgery: Data, Dilemmas and Conclusions. Paper Presented at the European Society of Cataract and Refractive Surgeons. Dublin, Ireland: 2013. Accessed July 25, 2020
3. Behrens-Baumann, Frank, Neß (2010) Rational antibiotic therapy in ophthalmology. *Ophthalmologie* - 2010 Apr;107(4):323-327.

4. Behrens-Baumann; (2011) Prophylaxis and therapy of postoperative endophthalmitis. Criticism of the ESCRS study and the Early Vitrectomy study] *Ophthalmologie* 2011 Nov;108(11):1062, 1064-1066.
5. Bertino J. S., Jr (2009). Impact of antibiotic resistance in the management of ocular infections: the role of current and future antibiotics. *Clinical ophthalmology (Auckland, N.Z.)*, 3, 507–521.
6. Beselga D, Campos A, Castro M, Fernandes C, Carvalheira F, Campos S, Mendes S, Neves A, Campos J, Violante L, Sousa JC. Postcataract surgery endophthalmitis after introduction of the ESCRS protocol: a 5-year study. *Eur J Ophthalmol.* 2013 Dec 16:0.
7. Beyea SC. Preventing surgical site infections--guiding practice with evidence. *AORN J.* 200Aug;72(2):3057.
8. Billy D Novosad, Michelle C Callegan (2011) Severe bacterial endophthalmitis: towards improving clinical outcomes *Expert Rev Ophthalmol.* PMID: PMC3092298 DOI: 10.1586/eop.10.52
9. Callegan, M. C., Engelbert, M., Parke, D. W., 2nd, Jett, B. D., & Gilmore, M. S. (2002). Bacterial endophthalmitis: epidemiology, therapeutics, and bacterium-host interactions. *Clinical microbiology reviews*, 15(1), 111–124.
10. Dancer, S. J., Stewart, M., Coulombe, C., Gregori, A., & Viridi, M. (2012). Surgical site infections linked to contaminated surgical instruments. *The Journal of hospital infection*, 81(4), 231–238.. 2012.04.023
11. Dhoot SB, Kunjukunju N, Sabates N. (2013).The role of prophylactic antibiotic use in prevention of endophthalmitis following intravitreal injection of anti-vascular endothelial growth factor agents: a meta-analysis. *Open J Ophthalmol.*, 3(2):46–49.
12. D.T. Pham (2005); prophylaxis and therapy of endophthalmitis guidelines.
13. Fang, Y. T., Chien, L. N., Ng, Y. Y., Chu, H. F., Chen, W. M., Cheng, C. Y., & Wu, S. C. (2006). Association of hospital and surgeon operation volume with the incidence of postoperative endophthalmitis: Taiwan experience. *Eye (London, England)*, 20(8), 900–907.
14. Frenkel, M.P., Haji, S.A. and Frenkel, R.E. (2010) Effect of Prophylactic Intraocular Pressure-Lowering Medication on Intraocular Pressure Spikes after Intravitreal Injections. *Arch Ophthalmol*, 128, 1523-1527.
15. Hoevenaars, N. E., Gans, D., Missotten, T., van Rooij, J., Lesaffre, E., & van Meurs, J. C. (2012). Suspected bacterial endophthalmitis following intravitreal anti-VEGF injection: case series and literature review. *Ophthalmologica. Journal internationale d'ophtalmologie. International journal of ophthalmology. Zeitschrift für Augenheilkunde*, 228(3), 143–147.
16. Hollands, H., Wong, J., Bruen, R., Campbell, R. J., Sharma, S., & Gale, J. (2007). Short-term intraocular pressure changes after intravitreal injection of bevacizumab. *Canadian journal of ophthalmology. Journal canadien d'ophtalmologie*, 42(6), 807–811.
17. Lundström M, Wejde G, Stenevi U, Thorburn W, Montan P. (2007) Endophthalmitis after cataract surgery: a nationwide prospective study evaluating incidence in relation to incision type and location. *Ophthalmology.* 2007 May;114(5):866-870.
18. Lyall DA, Tey A, Foot B, Roxburgh ST, Viridi M, Robertson C, MacEwen CJ. Post-intravitreal anti-VEGF endophthalmitis in the United Kingdom: incidence, features, risk factors, and outcomes. *Eye (Lond).* 2012 Dec;26(12):1517-1526.
19. M. Rehak. R. Blatz. P. Meier (2008) primary intraocular antibiotic in acute post-operative endophthalmitis. *Ophthalmologie* 2007.104:958-964 der Augenheilkunde Feb. 2008, Volume 22, Issue 1, pp 19-25
20. Park, J. C., Ramasamy, B., Shaw, S., Prasad, S., & Ling, R. H. (2014). A prospective and nationwide study investigating endophthalmitis following pars plana vitrectomy: incidence and risk factors. *The British journal of ophthalmology*, 98(4), 529–533.
21. Pierre-Loic Cornut, MD, PhD, Sandrine Boisset, PharmD, PhD, Jean-Paul Romanet; Principles and applications of molecular biology techniques for the microbiological diagnosis of acute post-operative endophthalmitis *Surv Ophthalmol.* 2013 Dec 17. pii: S0039-6257(13)00200-2 [PubMed].]
22. Rudnisky CJ, Wan D, Weis E. (2013) Antibiotic Choice for the Prophylaxis of Post-Cataract Extraction endophthalmitis *Ophthalmology* Dec 7 .pii: SO 161-6420(13)01007-5
23. Semeraro, F., Morescalchi, F., Duse, S., Gambicorti, E., Cancarini, A., & Costagliola, C. (2015). Pharmacokinetic and Pharmacodynamic Properties of Anti-VEGF Drugs After Intravitreal Injection. *Current drug metabolism*, 16(7), 572–584.
24. Shah, Chirag P; Garg, Sunir J; Vander, James F; Brown, Gary C; Kaiser, Richard S; Haller, Julia A; and The Post-Injection Endophthalmitis (PIE) Study Team (2011). "Outcomes and risk factors associated with endophthalmitis after intravitreal injection of anti-vascular endothelial growth factor agents." *Ophthalmology*, 118 (10): 2028-2034.
25. Schein OD. (2007); Prevention of endophthalmitis after cataract surgery: making the most of the evidence. . *Ophthalmology*.
26. Solborg Bjerrum, S., Kiilgaard, J. F., Mikkelsen, K. L., & la Cour, M. (2013). Outsourced cataract surgery and postoperative endophthalmitis. *Acta ophthalmologica*, 91(8), 701–708.
27. Sumeet Malhotra, Partha Mandal, Gopal Patanker, Deepshikha Agrawal (2008) Clinical profile and visual outcome in cluster endophthalmitis following cataract surgery in Central India *Indian J Ophthalmol*; 56(2) 157–158. PMID: PMC2636096
28. Thomas A Ciulla<sup>1</sup>, Michael B Starr, Samuel Masket. (2002); Bacterial Endophthalmitis Prophylaxis for Cataract Surgery An Evidence-based *Ophthalmology* 109(1):13-24. doi: 10.1016/s0161-6420(01)00899-5.
29. Trevin Wallin, Jared Parker, Yian Jin, Gus Kefalopoulos, Randall J Olson. Cohort study of 27 cases of endophthalmitis at a single institution. *J Cataract Refract Surg.* 2005 PMID: 15899450 DOI: 10.1016/j.jcrs.2004.10.057
30. Yannuzzi NA, Patel SN: (2014) predictors of sustained intraocular pressure elevation in eye receiving intravitreal antivascular endothelial growth factor therapy. *Am J ophthalmol* 2014;158:319-327
31. Zenith H. Y. Wu, Rose P. S. Chan, (2012) Review of Clinical Features, Microbiological Spectrum, and Treatment Outcomes of Endogenous Endophthalmitis over an 8-Year Period *J Ophthalmol.* 2012: 265078. Published online 2012 February 23. doi: 10.1155/2012/265078 PMID: PMC3594912





This work is licensed under Creative Commons Attribution 4.0 License

To Submit Your Article Click Here: [Submit Article](#)

DOI:[10.31579/2692-9392/018](https://doi.org/10.31579/2692-9392/018)

**Ready to submit your research? Choose Auctores and benefit from:**

- ❖ fast, convenient online submission
- ❖ rigorous peer review by experienced research in your field
- ❖ rapid publication on acceptance
- ❖ authors retain copyrights
- ❖ unique DOI for all articles
- ❖ immediate, unrestricted online access

At Auctores, research is always in progress.

Learn more [www.auctoresonline.org/journals/archives-of-medical-case-reports-and-case-study](http://www.auctoresonline.org/journals/archives-of-medical-case-reports-and-case-study)