

The effectiveness of ozone therapy in the patient with necrotic vasculitis wound

Hayriye Alp

Necmettin Erbakan University, GETAT CENTER, Konya, Turkey.

Corresponding Author: Hayriye Alp, Necmettin Erbakan University, GETAT CENTER, Konya, Turkey.

Received date: February 25, 2021; **Accepted date:** March 05, 2021; **Published date:** March 10, 2021

Citation: Hayriye Alp (2021) The effectiveness of ozone therapy in the patient with necrotic vasculitis wound *J, Heart and Vasculature* 1(1); DOI: 10.31579/JHV-2021/004

Copyright: © 2021, Hayriye Alp, This is an open access article distributed under the Creative Commons Attribution License, which permits unrestricted use, distribution, and reproduction in any medium, provided the original work is properly cited.

Abstract

Necrotic wounds are common injuries in many patients hospitalized in intensive care. Ozone therapy has been used as a complement to modern medicine since 1902 in the treatment of diabetes. It has been used in our country since 1999. With ozone therapy (o3), microcirculation improves 20-60% in the circulation in 12-14 days, and 10-40% in the venous part. Ozone therapy has been shown to reduce proinflammatory cytokines in soft tissue infections. This method of treatment will provide significant benefits if used in addition to modern medicine.

Key words: necrotic wound, ozone therapy, antiphospholipid syndrome

Introduction

Medical ozone therapy uses a gas mixture of ozone and oxygen, which never contains less than 95% oxygen [1]. There are several routes of ozone application. These include autohemotherapy, intramuscular, intra-articular, and paravertebral injections, rectal or vaginal insufflations, and topical ozone application.

A number of studies suggest that ozone therapy may have a role in the treatment of chronic wounds. Martinez-Sanchez *et al.* used three different routes of ozone application concurrently in diabetic patients with chronic wounds and compared the results with matched controls [2]. Patients in the ozone therapy group were treated by rectal ozone insufflations, topical ozone, and wound dressings with ozonized sunflower oil. Although the number of patients with complete healing was similar in both groups, ozone therapy increased the healing rate of wounds and reduced the hospitalization time.

Wainstein *et al.* used topical ozone therapy in addition to standard therapy in diabetic wounds [3]. Although the intention-to-treat analysis failed to show any benefit, the per-protocol analysis revealed that topical ozone therapy might confer clinical benefit when added to conventional treatment in diabetic wounds smaller than 5 cm² [3].

With the effect of ozone bradykinin release and inflammation inhibition of prostaglandin synthesis, it has an analgesic effect. It increases the release of antagonists that neutralize proinflammatory cytokines such as ozone IL-1,8,12,15 and TNF.

Depending on the stage and location of the lesion, ozone gas is used in concentrations of 60-40-30-20µg / ml in periods of 20-30 minutes. In purulent infections, 60-70µg / ml can be used. After the infection is under control and healthy granulation tissue is seen, the dose and session interval can be reduced. Erythrocytes increase elasticity and

deformability, blood can circulate better in microcirculation, tissue oxygenation increases. Ozone therapy used in soft tissue infections has been shown to significantly reduce pro inflammatory cytokines (IL-6, 8, 10) and fibroblast growth factor levels [4].

The effect of ozone therapy on necrotic wounds

This technique made with ozone therapy is considered as one of the best methods on the human body that you can do both for aesthetic treatment and for the treatment of diseases. It provides the opportunity to treat the person in a comfortable environment without any side effects, using a non-invasive method.

Ozone oil is obtained by passing the ozone bubbles obtained from pure oxygen through olive oil (sunflower oil, etc.) for a certain period of time. Double bonds of unsaturated fatty acids in oils such as olive oil are formed from peroxide series, oxidized by ozone gas. Peroxide is formed as much as the broken double bonds in unsaturated Ansature oil. The oil should be ozonated until it becomes solid [5]. It is classified according to the amount of ozonoid (peroxide) in ozonated oils.

Ozone oil has a long time to stay active when it is stored in the refrigerator and with its mouth closed. Dr J. Hansler has shown that good quality ozone oil will maintain its quality in the refrigerator for more than 10 years [6].

Every year peroxide rate is 5% when stored at +4 ° C, 30-50% when stored at +20 ° C, The mechanism of action of ozone oil provides skin oxygenation, increases microcirculation, triggers tissue repair and regeneration, slows the skin aging process. The omega3,6,9s present in the content of the ozonated oil have anti-inflammatory effects. It reduces fluid loss of the skin [7].

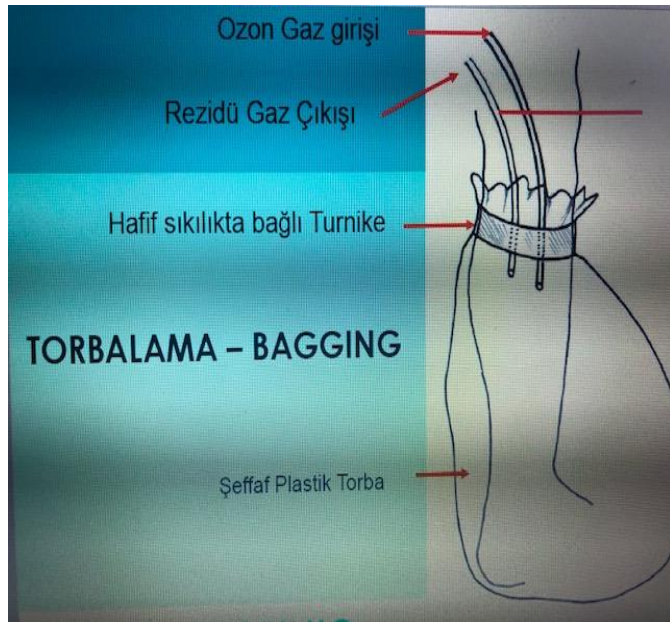
The effects of ozone oil on the healing of the experimental skin flap were investigated. In the acute cutaneous wound healing model, it has been reported that ozone oil contributes to neovascularization. With the study, the effect of ozonized oil on vascular endothelial growth factor has been shown to be positive in rats [8].

It is emphasized that the combination of ozonized oil with α -bisabolol (chamomile) is effective in supportive treatment in venous ulcer cases and necrotic wounds [9].

A study was conducted on the experimental facial nerve paralysis of ozone therapy; Ozone therapy has been found to be effective in regeneration of facial nerve damage in rats [10].

Case History

The male patient was 68 years old, and he was diagnosed with antiphospholipid syndrome. While undergoing intensive care treatment for 2-3 months, venous ulcers have formed on his feet. neither applied for ozone therapy. The patient was taking multiple antiaggregants (salicylic acid, corasprin 100, trental cr 600, coumadin 5mg. There was coronary stent 2 times in her anamnesis. He had hemo dialysis treatment for 8 months with inr follow-up. Digoxin 0.025mg, Ator 40mg for cardiac problems. , desal tb, Beloc 100mg, Diltizem 90mg, ursaeactive for gall bladder stone, levotron 0.25mg for goiter. Antiphosphate capsule 500mg 3x1 and endoxane for Panto tb antiphospholipid syndrome. Permission was obtained from patients or legal representative if required.



Ozone gas entrance , exit, tourniquet, bag

Figure 1. Tecnic of bagging ozone

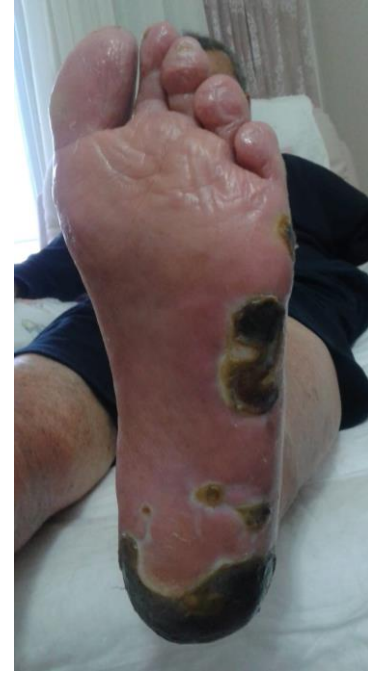

Figure 2. Treatment Before

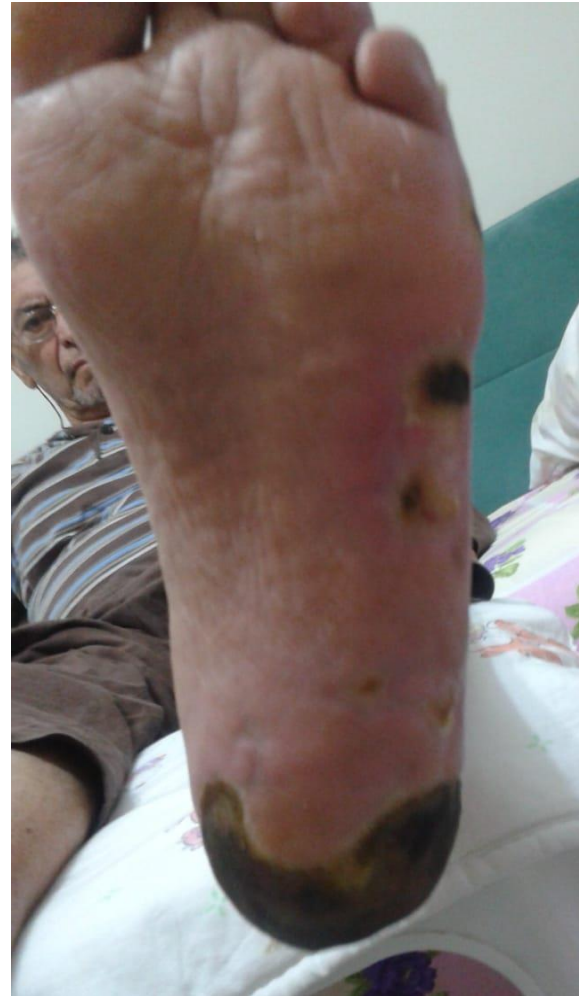

Figure 3. In Treatment During

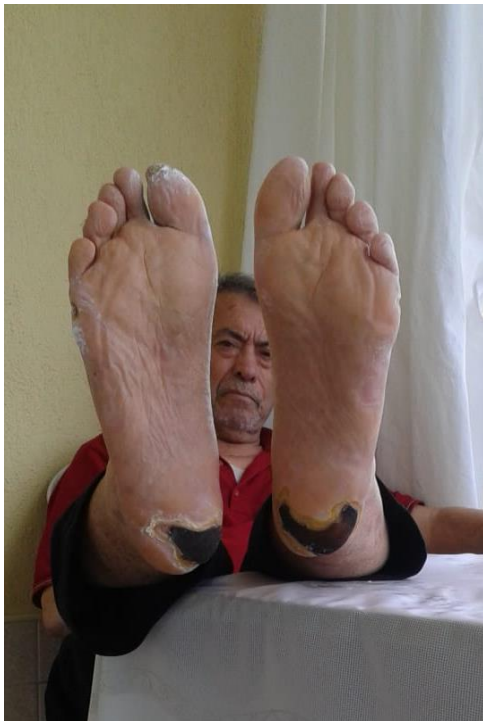

Figure 4. After Treatment Ozone

First, ozone oil was applied to the ulcer area. Then, beating ozone therapy was performed every 5 days (20-30 -40-60-70 μ g / ml doses) every other day. The last patient was asked to apply sarichanone oil.

The ulcers in both the heel area and side parts of the geriatric patient using multiple drugs and antiphospholipid syndrome also improved in the 3rd week. The dead skin of the patient was peeled and new tissue granulated from the bottom was observed.

Discussion

There are many publications in the literature about the therapeutic properties of ozone. In infected wound treatment study; Staphy in irrigation with ozone saline. The effect of ozone on sterilisation and wound healing, in which the Aureus biofilm layer is removed, has been shown [11]. Usage areas of ozone therapy were determined by Madrid declaration in 2010 [12].

In the studies conducted, the results of multitrauma were very successful with the addition of ozone therapy to the treatment [13]. The same study group reported that they achieved very successful results in furnier gangrene.

Ozone therapy and hyperbaric oxygen therapy have not been shown to be superior to each other in studies performed on different groups of experimental animals. It is stated that both of them increase bone wound healing [14]. Ozone therapy, which is effectively used in bone healing, has been shown to reduce staphylococcal colonization by 99% within 15 minutes without showing cytotoxic effects to osteoblasts [15].

Ozone therapy has been found to increase the inflammatory neutrophil migration and activate IL-10 via TNF- α [16].

In a randomized controlled gingival deepitelizing graft case study, the postoperative of ozone therapy. It has been determined that with the better blood flow in the first week, it improves wound healing, increases quality of life, and decreases pain [17].

Ozone therapy, which was used empirically at the beginning, now finds use in many skin related diseases with a better understanding of its biological effects. Ozone therapy, which is used effectively in tissue healing, has been found effective in all 3 phases of wound healing. It can be used effectively in both gram negative and gram positive bacteria, virus and fungal infections [18, 19]. The mechanism of action of ozone oil provides skin oxygenation, increases microcirculation, triggers tissue repair and regeneration, slows the skin aging process. The omega 3,6,9s present in the content of the ozonated oil have anti-inflammatory effects. It reduces fluid loss of the skin [7]. Also, it is a subject to be kept on the agenda and investigated as an adjuvant treatment method that provides both antimicrobial and tissue regeneration.

Although our information about the exact mechanisms of ozone therapy is more recent, it is quite promising especially in skin and mucous diseases. Revealing the efficacy of ozone therapy at an increasing rate in the literature Articles are included. However, although ozone is very reliable and

Although it has a wide therapeutic index, critical anatomical having a good command of the anatomical structure in ozone gas application to localizations, Except for experienced practitioners who perform well the application technique, such we believe that interventions should not be made. Care should be taken when injecting ozone near vital organs such as the eyes and thin skin, although rarely emphysema may develop as a complication [20].

The mechanism of action of ozone therapy still needs to be explained in many ways are available. Positive clinical effects of ozone on dermatological problems. Despite the observation, unfortunately, many dermatological application methods are sufficient does not have a randomized controlled clinical trial. However suitable concentration, volume and application of O₃ in dermatocsmetic indications randomized controlled trials to help determine the pathway needs to be implemented.

References

1. Bocci VA. (2006) Scientific and medical aspects of ozone therapy. State of the art. *Arch Med Res.* 37:425–35.
2. Martínez-Sánchez G, Al-Dalain SM, Menéndez S, Re L, Giuliani A, Candelario-Jalil E, et al. (2005) Therapeutic efficacy of ozone in patients with diabetic foot. *Eur J Pharmacol.* 523:151–61.
3. Wainstein J, Feldbrin Z, Boaz M, Harman-Boehm I. (2011) Efficacy of ozone-oxygen therapy for the treatment of diabetic foot ulcers. *Diabetes Technol Ther.* 13:1255–60.
4. Makita Y., Imamura Y., Masuno K. (2015) The effect of ozone on collagen type-I and inflammatory cytokine production in human gingival fibroblasts. *Dentistry.* 5:339.
5. Bocci V. (2002) A new Drug Ozone Springer Netherlands.
6. Hansler RV. Fernandez OSL. Fahmy Z. (2012) Ozone in medicine: low-dose ozone concept-guideline and treatment strategies. *Science & Engineering.* 34(6),408-424.
7. Vinnik IS, Salmina AB, Tepliakova OV, Drobusevskaja AI, Pozhilenkova EA, Morgun AV, et al. (2015) The results of combined ozone therapy using in complex treatment of soft tissues infections in patients with diabetes mellitus type II. *Khirurgiia,* (2):63-69.
8. Krkl C, Yiğit MV, Özeran İH, Aygen E, Gültürk B, Artaş G. (2016) The Effect of Ozonated Olive Oil on Neovascularization in an Experimental Skin Flap Model. *Adv Skin Wound Care.* 29(7):322-7.
9. Velikaya VV , Gribova OV , Musabaeva LI , Startseva ZhA , Simonov KA , Aleinik AN , et al. (2015) Ozone therapy for radiation reactions and skin lesions after neutron therapy in patients with malignant tumors. *Voprosy Onkologii,* 61(4) :571-574

10. Ozbay I, Ital I, Kucur C, Akcular R, Deger A, Aktas S, et al. (2018) Effects of ozone therapy on facial nerve regeneration. *Braz J Otorhinolaryngol.* 83(2):168-175.
11. Al-Saadi H, Potapova I, Rochford ETJ, Moriarty TF, Messmer P. (2016) Ozonated saline shows activity against planktonic and biofilm growing *Staphylococcus aureus* in vitro: a potential irrigant for infected wounds. *Int Wound Journal.* 13(5): 936-942.
12. Schwartz A, Guemez FA, Nazarov SEI, Viebahn-Haensler R, Rieck AE, Stefan T. (2010) Madrid Declaration on ozone therapy. (Ozon Tedavisinde Madrid Deklerasyonu.) Madrid.
13. Türkmen A, Kesici S, Keles E, Büyükyıldırım A, Kesici U. (2015) Ozone treatment in patient with multiple traumas. *Case study and case reports.* (5) 1:25-28.
14. Türkmen A, Kesici S, Keles E, Büyükyıldırım A, Kesici U. (2015) Ozone treatment in patient with multiple traumas. *Case study and case reports.* (5) 1:21-24.
15. Kan B, Secimen M, Bayar GR, Korkusuz P, Coşkun AT, Korkmaz A, et al. (2015) Journal Maxillofac Surgery. 73(6):1231.e1-10.
16. Dawley, C. (2018). Aqueous Ozone Inactivation of Viruses and Bacteria on Biotic and Abiotic Surfaces.
17. Hao K, Liu Y, Feng J, Zhang W, Zhang Y, Ma N, et al. (2015) Ozone promotes regeneration by regulating the inflammatory response in zebrafish. *Int Immunopharmacol.* 28(1):369-75.
18. Taşdemir Z, Alkan BA, Albayrak H. (2016) Effects of Ozone Therapy on the Early Healing Period of Deepithelialized Gingival Grafts: A Randomized Placebo-Controlled Clinical Trial. *J Periodontol.* 87(6):663-71.
19. Zeng J, Lu J. (2019) Mechanisms of Action Involved in Ozone-Therapy in Skin Diseases. *Review Int Immunopharmacol,* 56:235-241.
20. Bas S, Yula E. (2018) Overview of dermatological ozone applications and a rare complication of dermal ozone treatment: Isolated orbital emphysema with cutaneous injection. *J Immunol Clin Microbiol.* 2018; 3(1): 38-49



This work is licensed under Creative Commons Attribution 4.0 License

To Submit Your Article Click Here: [Submit Manuscript](#)

DOI: [10.31579/JHV-2021/004](https://doi.org/10.31579/JHV-2021/004)

Ready to submit your research? Choose Auctores and benefit from:

- ❖ fast, convenient online submission
- ❖ rigorous peer review by experienced research in your field
- ❖ rapid publication on acceptance
- ❖ authors retain copyrights
- ❖ unique DOI for all articles
- ❖ immediate, unrestricted online access

At Auctores, research is always in progress.

Learn more www.auctoresonline.org/journals/journal-of-heart-and-vasculature